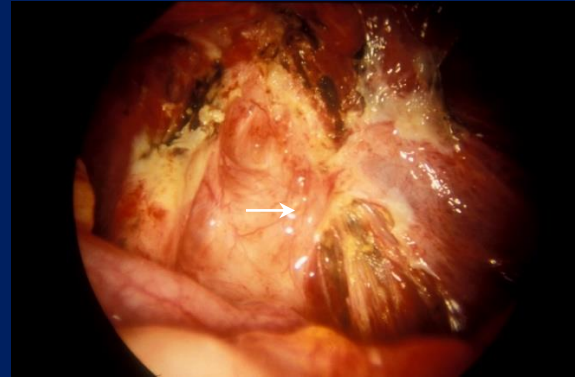
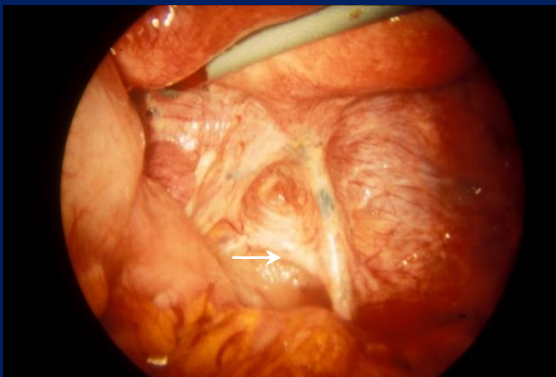


Endometriosis Concepts and Theories



Dan C. Martin

Foreword by John A Rock

Endometriosis

Concepts and Theories

Endometriosis

Concepts and Theories

Dan C. Martin, M.D.

Scientific and Medical Director, Endometriosis Foundation of America
Professor Emeritus, The University of Tennessee Health Science Center
Institutional Review Board, Virginia Commonwealth University

Working Copy, April 21, 2024

This working file is for the first edition to be published soon and is periodically updated at

www.danmartinmd.com/files/endotheory.pdf

When the first edition is published, a link will be added here.

Endometriosis Concepts and Theories began as a thread of email conversations on endometriosis theories in 2017 and has evolved into this monograph. Much of it is from email threads with other pelvic surgeons and Q&A sessions of meetings.

This is an open-access, educational publication. Permission is granted to use the images of this publication in educational programs, presentations, articles, blogs, social media, websites, and similar presentations. For specific questions about sharing the content, please reach out to danmartinmd@gmail.com or leave a message on Google Voice at +1 (901) 761-4787.

Additional Resources:

Endometriosis Concepts: <http://www.endometriosisconcepts.com/> (Webpage)

1988 Laparoscopic Appearance of Endometriosis (PDF)

www.danmartinmd.com/files/coloratlas1990.pdf

1990 Laparoscopic Appearance of Endometriosis Color Atlas (PDF)

www.danmartinmd.com/files/coloratlas1990.pdf

Downloads: <http://www.danmartinmd.com/sitemap.html> (Webpage)

Society for Women's Health Research (SWHR) Toolkit

https://swhr.org/swhr_resource/endometriosis-toolkit-a-patient-empowerment-guide/

Knowledge in clinical and surgical sciences constantly changes. As the latest information becomes available, changes in medical, alternative, or surgical management may be necessary. The author and contributors to this volume have taken care to confirm that the information is correct and compatible with the standards generally accepted at the time of publication. If you see that corrections are needed, please send them to the email address below.

Readers are advised to review the most current information available. Techniques discussed in this publication may have been modified or abandoned over time. It's important to distinguish between the principles of diagnosis and management of endometriosis.

This material serves as a public educational resource, intended for sharing on external platforms, websites, social media, blogs, and educational presentations, with appropriate citations as provided. It may be printed and displayed in its original format. We encourage sharing and reposting to raise awareness about endometriosis and women's health. For queries regarding content sharing, please contact danmartinmd@gmail.com or leave a message on Google Voice at +1 (901) 761-4787.

Please use the following or a similar statement on published reproductions:

*With permission of Dan Martin, Endometriosis Concepts and Theories, 2024,
www.danmartinmd.com/files/endotheory.pdf*

Please cite as:

Martin DC, editor. Endometriosis Concepts and Theories. Richmond, Virginia, Resurge Press, 2024, revised April 21, 2024, www.danmartinmd.com/files/endotheory.pdf. Accessed [insert date]"

ISBN: [979-8-9890297-0-9](https://www.isbn-international.org/product/9798989029709) - Registration in progress

Published by the Resurge Press
201 Wakefield Road, Richmond, VA 23221
(901) 761-4787
danmartinmd@gmail.com

Copyright 2017-2024, Dan C. Martin, MD, Resurge Press, Richmond, Virginia

Contents

Contents	1
Contributors	2
Dedication	3
Foreword	4
Cover	5
Introduction	6
Overview	6
Theory Background	8
Theoretical Concepts	10
Selection Bias	12
Diagnostic and Screening Tests	13
Can We Recognize Endometriosis?	14
Tunnel Vision	17
What Size Lesion Can We Detect at Laparoscopy?	17
When Does the Cell Of Origin Become Endometriosis?	18
Excision or Ablation for Endometriosis?	21
Surgery is Not the Only Answer; Proactive Holistic Care	28
Subtle Inflammatory Lesions, Bacterial Overgrowth, or Both?	30
The Tomato Effect (Theory-Based Medicine)	31
Medical Reversal of Evidence-Based Medicine	33
Annotated References (Chronologic)	34
References (Alphabetical)	104
Resources	165

Contributors

Munaza Afaq, M.B.B.S.

www.linkedin.com/in/afaqmunaza

Dr. Afaq is an international medical graduate with a strong interest in pursuing a residency in Obstetrics and Gynecology in the United States. Her career aspirations involve specializing in Reproductive Endocrinology and Infertility, and she is particularly eager to deepen her understanding of the complex disease of endometriosis. Alongside her medical pursuits, Munaza is passionate about mentoring and actively participates in healthcare awareness programs in her home country.

Katie Edmonds, FNTF

<https://orcid.org/0009-0006-1034-7915>

<https://www.healendo.com/>

Katie's books have been ranked from #1 to #4 on Amazon's list of endometriosis books the first four months of 2023.

Heal Endo: An Anti-Inflammatory Approach to Healing from Endometriosis

<https://www.amazon.com/Heal-Endo-Anti-Inflammatory-Approach-Endometriosis/dp/1792389485/>

The 4-Week Endometriosis Diet Plan: 75 Healing Recipes to Relieve Symptoms and Regain Control of Your Life

<https://www.amazon.com/4-Week-Endometriosis-Diet-Plan-Symptoms/dp/1641527366/>

Martin L. Robbins, M.D.

New England Center for Endometriosis

38 years in practice, Endometriosis excision for 27 years with a focus on intestinal and diaphragmatic involvement.

John A Rock, M.D.

Founding Dean Emeritus

Florida International University

Department of Obstetrics and Gynecology

11200 SW 8th St, AHC2 466

Miami, Florida 33199

Dedication

This monograph is dedicated to all those who advocate for more timely and better care for endometriosis sufferers. This complex and often devastating disease affects countless individuals worldwide. To tackle this multifaceted condition, we need a combination of expertise in medical management, surgical treatment, complementary and alternative medicine, and general health concerns. Advocates work tirelessly to educate physicians, patients, and even adolescents in schools through various outreach programs. Some focus on specific areas of endometriosis, such as deep infiltrating endometriosis, while others address the entire spectrum of issues, including pain, infertility, and proactive management of young women to potentially limit or prevent this disease.

Comprehensive advocacy requires the integration of many possibilities and the creation of individualized plans for each patient. We recognize that every person is unique and requires an individualized approach. In our pursuit of solutions to the challenges of endometriosis, we must remain prepared and well-informed. Louis Pasteur's famous quote, "Chance favors the prepared mind," is particularly applicable here. Advocacy requires a commitment to ongoing research and education to prepare for future development.

Endometriosis can be a complex condition with many overlapping symptoms and conditions. Other illnesses, such as irritable bowel syndrome, chronic cystitis, and bladder dysfunction, can often mimic endometriosis symptoms and complicate diagnosis and treatment. In contrast, many individuals have asymptomatic disease with no recognized problems; they are concerned about the 2% to 10% chance it will progress.

Successful advocacy demands a deep understanding of the multiple factors that influence endometriosis, including immunity, genetics, epigenetics, inflammation, fibrosis, medical and surgical treatments, complementary and alternative medicines, and the various triggers that can contribute to developing this condition.

As a former gynecologic surgeon and Consumer's Checkbook Primary Care Certificate of Achievement awardee, I bring a mixed perspective to the management of endometriosis. That combination of tertiary and primary care experience contributes to seeking to broaden our understanding of the entire spectrum of issues related to endometriosis, from its medical and surgical management to complementary and holistic health concerns. I am grateful to the many contributors who have helped make this a comprehensive resource for physicians, patients, and others seeking to better understand this often-challenging disease.

Although this monograph discusses "women," that is not to detract from the suffering of an unknown number of trans-men, nonbinaries, and sex diverse individuals.

Daniel C. Martin, MD

Foreword

Endometriosis remains an enigmatic disease. Dan Martin brought needed clarity to our understanding of this disease with the first monograph ([Laparoscopic Appearance of Endometriosis Color Atlas](#)) which addressed the challenges of visual recognition of Endometriosis. This second monograph (Endometriosis Concepts and Theories) offers additional clarity by comprehensively reviewing the concepts and theories of the origin of Endometriosis and provides a critical analysis of the current treatments. There are in-depth discussions of the main theories of the Pathogenesis of the disease. The author provides important discussions of Theory- Based medicine, Selection Bias, and Medical Reversal of Evidence Base Medicine and their influence on our treatment approaches. This new edition provides the reader with a comprehensive, chronologic, and annotated reference list. Included with each reference is a brief statement summarizing the study findings.

The gynecologist will find the second edition a welcome addition to his or her library. The author reminds us that much work is needed by future clinician scientists to truly understand the pathogenesis of endometriosis and to develop highly effective treatment protocols.

John A. Rock, M.D.
May 2, 2023

Cover

“*Leave it alone*” David Redwine, 2018

The cover images are examples of intentionally avoiding rectal endometriosis based on a patient shared decision. Twenty years later, she had no residual pain or evidence of endometriosis.

Before surgery, she had several years of moderate to severe dysmenorrhea and pain with sex for two days a month associated with tender uterosacral nodules. She was medically sophisticated, i.e., she was a hospital employee who worked with me and understood endometriosis. She had decided to tolerate pain and monitor for the possibility of progression since she wished to avoid the potential side effects or complications of medical suppression or surgery.

At age 43, she had a 6 cm dermoid appearing, complex cyst with characteristics suggesting the possibility of cancer. She consented to surgery in this situation due to the possibility of cancer and wanted laparoscopy if reasonable. She wished to avoid laparotomy; that included elective bowel surgery. The cyst was a benign dermoid with no evidence of cancer. There was diffuse endometriosis with rectal involvement. Although she was ready for bowel surgery in the case of cancer, she did not want bowel surgery that included possible colostomy. Endometriosis was resected as close to the rectum as reasonably. The arrows in the cover images point to the area of involvement of the rectum.

The rectal endometriosis was discussed with her at a follow-up visit. She decided that she would rather live with her cramps than take even a small chance of a colostomy. The chance was less than 1% for small nodules at this location; 0% in my practice. That contrasts with rectovaginal endometriosis with anastomosis at 3 to 4 cm from the anus and 1 to 2 cm from the hymen where my colostomy rate for perforation complications was 67%. That is contrasted with planned diverting, protective colostomy sometimes decided on by the bowel surgeon. Current evaluation would also include pre-operative imaging to look for the possibility and degree of bowel involvement to facilitate surgical planning.

On yearly follow-up exams monitoring for the possibility of progression, she had focal right rectal tenderness at about 12 cm with no palpable nodule in the area of residual endometriosis. Sigmoidoscopy was benign. No MRIs were done at that time, but I would use periodic ultrasound, MRIs, or other testing in similar cases today to monitor for growth or malignant transformation. A concern is that even asymptomatic endometriosis may progress (Moen 2002, Fedele 2004b) or be associated with complications such as silent loss of a kidney. (González-Bonilla et al. 2019; Yang et al. 2021) Moreover, with our [inability to recognize all endometriosis](#), we should have concern for all who are diagnosed with or thought to have endometriosis. Neither surgery, nor contemporary medicine, nor complimentary medicine, nor alternative medicine, nor the body's immune and reparative systems cures all endometriosis.

Her cramps were controlled with over-the-counter medication until she was perimenopausal. Pain with bowel movements was tolerated and not treated with medication. By age 50, her symptoms and the right rectal tenderness had resolved. She avoided estrogens; therefore, control of menopausal symptoms was difficult for a few years. She was in good health with no pain or palpable abnormalities when last seen at age 63.

Sometimes, examination and imaging can help prepare for rectal surgery. The response to unanticipated rectal involvement, when a patient and surgeon are not prepared or do not consent for colostomy, is to avoid the bowel, discuss the situation post-operatively, and decide on plans, the appropriate team, and an appropriate evaluation.

Introduction

“Please don’t refer to endometriosis, adenomyosis, or fibroids as “benign disease” – nope, not benign, they are “common and morbid.””

[Linda G Griffith, Ph.D.](#), 2020

“Studying endometriosis is like nailing Jell-O to a tree.”

[Donna Vogel, MD, Ph.D.](#), 2000

“Embrace the complexity of the disease.”

[Hugh Taylor, MD](#), 2023, Reframing Endometriosis: Power, Politics and Potential Futures. Birmingham City University, Birmingham, UK, The British Academy Conferences, 2023

Symptoms suggesting endometriosis were reported as early as 1855 BC (Kahun Medical Papyrus, Egyptian). ([Redwine 2012](#), [Nezhat 2012](#)) The first description of endometriotic nodules may be Hippocrates (400 BC) noting that "part of the vagina hardens." ([Whiteley 2003](#)) Intraabdominal lesions with history compatible with endometriosis were noted in 1690 (Shroen). The histology of endometriosis and adenomyosis was described in 1860 (Rokitansky) and difficulty in recognition was documented in 1899 (Russell). [Sampson’s publications](#) beginning in 1918 expanded the study of endometriosis. Sampson (1925a) proposed the term “endometriosis” to replace the earlier “adenomyoma,” “adenomas of the endometrial type,” and other terms.

The articles summarized in this review are only a small part of what is published. A PubMed search for endometriosis 7/8/2023 listed 33,539 articles with 1,912 articles (5.3 daily) in the past year compared with 3.5 and 2.8 daily in the previous four years and nine years. In addition, scholar.google.com lists 440,000 articles and the NIH Gene Expression Omnibus (GEO) database has more than 291,450 GEO profiles.

Overview

- Endometriosis is heterogenous with more than 65 overlapping, visual and anatomic phenotypes published in 16 papers from 1921 to 2014. And there are many microscopic, biochemical, histochemical, immunological, genetic, and epigenetic phenotypes. It presents with heterogenous signs, symptoms, and behaviors and has a non-uniform response to hormonal, surgical, and anti-inflammatory therapy. The prevalence varies from 0.9% to 22% overall, 2.1% to 77.1% in infertile women, and 1.4% to 50.0% in fertile women (Simpson 1980, Guo 2006). It can regress, progress, or remain stable. There is debate about diagnostic criteria. Possible components of the criteria include endometriotic (endometrium-like) glands and stroma, evidence of bleeding, transition from a cell of origin to an endometriotic cell, vascularization, fibrosis, and the presence of CD10, IFITM1, BER-Ep4, Calretinin, CD34, antiendometrial antibodies or other characteristics.
- There are age-dependent, diagnosis, symptom, sign, and imaging differences in appearances, depth of infiltration, and volume of lesions.
- The diffuse locations of endometriosis may be explained by retrograde menstruation, peritoneal dispersion, attachment, infiltration, and growth; peritoneal or pleural metaplasia; and hematogenous or lymphatic dissemination of Müllerian or non-Müllerian stem cells.

- Nodular rectovaginal lesions of 4 cm can be asymptomatic while 0.08 mm lesions have been associated with pain. Tenderness can be found 27 mm from a visible lesion.
- Endometriosis can be hidden deep or behind adhesions; it can be missed in plain sight. Clinically unrecognized endometriosis was described as early as 1899 and nodules as large as 4 cm have been discovered beneath adhesions or scar and in ovaries, the retroperitoneum, tubes, lymphatics including nodes, open pockets, cryptic pockets, large and small bowel, appendices, epiploic fat, mesentery, and omentum. Surface endometriosis may not be visualized on the peritoneum when it is microscopic, including stem cells.
- Coelomic metaplasia, immune overload, immune dysfunction, immune dysregulation, escape from immune surveillance, immune maturation, neuroimmune maturation, inflammatory induction (initiation or activation), stem cells, epigenetic, and genetic changes may play a role in both women and men.
- Pulmonary, pleural, and mediastinal endometriosis may be a) retrograde menstruation with dissemination through diaphragmatic fenestrations or infiltration through the diaphragm, b) hematogenous dissemination, c) diaphragmatic lymphatic dissemination, or d) coelomic metaplasia of the pleura.
- Retroperitoneal, retrocervical, and cul-de-sac endometriosis may be a) Müllerian remnants, b) pelvic lymphatics, c) retrograde with retraction, or d) hematogenous.
- Hematogenous sites may include pulmonary, spinal, dermal, and other distal sites.
- Early endometriosis may start with normal Müllerian (endometrium, endosalpinx or remnants) cells or non-Müllerian (peritoneal) stem cells. These undergoes reactive, biochemical, hormonal, immunologic, epigenetic, and genetic changes in developing later and more severe forms of endometriosis. Bone marrow stem cells may engraft previous foci of endometriosis. Peritoneal metaplasia may be recruitment into preexistent endometriosis.
- Bone marrow–derived stem cells may engraft and “differentiate into multiple cell types including endothelial, muscle, stromal, and epithelial cells.” (Mamillapalli 2021) They are not specific for endometriosis.
- Sites of surgical transplantation include C-section scar, surgical excision scar including laparoscopy incisions, drain sites, episiotomies, and vaginal tears.
- *Inflammatory* stimuli can include estrogens, menstrual debris, surgical trauma, and infection.
- Fibrotic collagen reaction (fibrogenesis) with muscular metaplasia starts as part of a local inflammatory reaction with prolonged exposure to activated platelets or immune cells leading to increased expression of α -smooth muscle actin as part a pathologic process that Guo (2018) characterizes as wounds undergoing repeated tissue injury and repair (ReTIAR).
- Neuroimmunologic maturation, decreased immunologic load, control by the hypothalamic-pituitary-adrenal axis, homeostasis of the sympathetic nervous system, immunocompetence, apoptosis, autolysis, and autophagy can limit infiltrative or expansive growth.
- Endometriosis is associated with müllerian anomalies.
- Genetics, epigenetics, clonality, repeated tissue injury and repair (ReTIAR), peritoneal metaplasia as recruitment into preexistent endometriosis, engrafting of bone-marrow stem cells into endometrium or endometriosis, neuroimmunologic maturation, neuroendocrine axis interaction, and homeostasis of the sympathetic nervous system also appear important.

Theory Background

There are many theories of endometriosis that may be useful at several levels, including guiding research, acting as a framework for education, understanding possibilities in endometriosis, explaining changes that occur in endometriosis, and explaining why treatment might work. On the other hand, the [Tomato Effect](#) discusses how theories can interfere with the acceptance of useful remedies. This is contrasted with the placebo effect or a conclusion that coincidental improvement is related to treatment. In addition, Medical Reversal is an ongoing parallel concern that requires continuing education for improvements in medicine.

Sampson (1921) noted that endometrium was different from endometriosis “both in structure and in function.” The pathophysiology of the transition from normal endometrium, müllerian remnant, bone marrow stem cells, peritoneal cells, or other cell of origin is needed. Current theories start with müllerian cells in a normal (endometrium, tubal epithelium) or abnormal (müllerian rests or possibly endometriosis) position or non-müllerian cells that can include peritoneum, bone marrow stem cells, and possibly endometriosis if endometriosis originates from a non-müllerian cell.

Retrograde menstruation was found in 76% of women undergoing tubal ligation (Liu and Hitchcock 1986) and müllerian remnants or markers in 85.7% of fetuses (Bouquet de Jolinière et al. 2012). Additionally, everyone has peritoneum and bone marrow stem cells. But only 2% to 22% develop endometriosis. (Guo and Wang 2006) Thus, more is needed to understand the development of endometriosis than a precursor cell.

A stimulus or stimuli is needed for initiation, induction, or activation of the transition from a normal cell to an endometriotic cell with the potential to progress to late endometriosis. Activation may involve hormonal, inflammatory, immune, epigenetic, genetic, or other factors. Activation has a window-of-opportunity that is in adolescence and early adulthood. The window-of-opportunity might involve the maturation of the hormonal axis, neuroimmune maturation, or other processes. This might involve engrafting or metaplastic differentiation. Growth requires escape from immune control, clearance and other controls and epigenetic changes. Last there needs to be mechanisms of stabilization, inactivation, and theoretical clearance. Stabilization and inactivation may be more common than progression. (Evers 2013, Fuentes 2014) It can be speculated that clearance is the normal response in most women. Is so, that will be impossible to prove without accurate non-invasive diagnostic markers.

No concept or theory is entirely adequate. I learned Sampson’s retrograde theory in 1970 (Sampson 1921 & 1927, Ridley 1961) and added Müllerian remnants (Batt 1985, Koninckx and Martin 1992) and surgical transplantation by 1992. I was using those, lymphatic dissemination, venous dissemination, and inflammatory induction when I retired in 2016. After I retired and had more time to read the literature, the number I need has increased to more than twenty-three to introduce what I saw in patients or published and more to discuss what I have read. I also have a list of 40 overlapping concepts Sampson discussed. The number continues to increase with 2,157 new endometriosis papers in PubMed and 20,200 in Google Scholar in 2023.

Although retrograde theory was first published by Schrön (1690) and Ruysch (1691), (Nezhat 2012) Sampson’s focus on retrograde theory began a revolution in our understanding of endometriosis. He introduced venous dissemination and expanded on retrograde and metaplastic theories. Retrograde theory is adequate as the cell of origin for all peritoneal and other endometriosis that can be seen at laparoscopy. (Sampson 1927a) It is also supports other

menstrual substances (Levander 1955, Merrill 1966) as precursor substances or initiators for peritoneal metaplasia, fibrosis, and epigenetic changes such as intrauterine tissue injury and repair, inflammatory factors such as cytokines, microRNA-mediated signal transduction pathways for context-dependent gene expression, and Wnt signaling. However retroperitoneal, bowel wall, pulmonary and other distal sites require venous, lymphatic, or surgical routes of dissemination or developmental mispositioning. (Sampson 1922, Sampson 1927b, Batt 1985, 2011a, 2013, & 2015, Possover 2007, Roman 2021, Possover 2021)

Müllerian tissue is programmed to migrate along the genital ridge and become the uterus including the endometrium, Fallopian tubes, and upper vagina. Alternatively, Müllerian cells can migrate to abnormal positions during embryonic development and become a Müllerian rest. Endometrium can disseminate after birth by retrograde menstrual, venous, lymphatic, or surgical routes. In addition, parallel pathways can result in adenomyosis, endosalpingiosis, or endocervicosis. Endomyometriosis appears to be an organoid form of endometriosis as discussed by Batt (1989) and is likely congenital. Accessory and cavitated uterine mass and juvenile cystic adenomyoma may be adenomyosis variants.

Retroperitoneal, rectovaginal, and retrocervical endometriosis may be Müllerian remnants (Batt 1985, 2011a, 2013, & 2015; Redwine 1988, 2002, 2018; Koninckx 1992; Donnez 2001; and Signorile 2009, 2010 & 2012), lymphatic metastasis, the result of retrograde with retraction, or hematogenous metastasis. However, hidden, retroperitoneal endometriosis in women and any endometriosis in men are rarely reported and, until Badescu et al. (2016) found unrecognized endometriosis in 100% of 26 bowel endometriosis cases, hidden endometriosis was considered as uncommon or rare. That series was recently updated to clarify that nonvisualized nodules as small as 2 mm can be palpated at laparotomy in 25% of bowel resections with 14% of those at or beyond the anticipated staple line (Roman 2021). A similar microscopic finding in tubes is reported by McGuinness et al. with tubal endometriosis found grossly in 12 (12%) and microscopically in 34 (35%) of 97 women. Possover (2007 and 2021) found isolated sciatic endometriosis with no connection to the peritoneum in 267 (59%) of 452 patients with sciatic endometriosis. Moreover, 36 (54%) of 67 in group 1 had no other evidence of endometriosis as seen in three patients in 2007.

Rei (2018) found only 17 cases in men in the world literature from 1971 to 2018. The 17 male cases and retroperitoneal cases in women are limited to the genital and lower abdomen areas and are therefore not a model for the diffuse locations of female endometriosis. Furthermore, Rei (2018) reported one case compatible with coelomic metaplasia. Also, if organoid, a Müllerian remnant could be expected to look like an accessory and cavitated uterine mass (Acién 2012), endomyometriosis (La Greca 2021), or a uterus-like mass (Clement 2007). In contrast, the location of most female cases of endometriosis, including retroperitoneal, can also be explained with retrograde, hematogenous, lymphatic, or extensional dissemination.

Furthermore, various forms of trauma such as delivery, uterine curettage, intraabdominal surgery, retroperitoneal menstruation, intraperitoneal hemorrhage, or occult pelvic inflammatory diseases may mitigate the ongoing course and chance of recurrence. That might even include surgical treatment of endometriosis which may cause inflammation and increase implantation.

Theoretical Concepts

Theoretical concepts include the source of the *cell of origin*; methods of *dissemination (metastasis)* if not in situ: the stimulus or stimuli for the *initiation, induction or activation* of the transition; why, how, and when the cell of origin (transient phenomenon or early endometriosis?) *transition or growth* to late endometriosis; and the mechanisms of *inactivation and clearance*. Some theories combine some or all the components. This discussion considers those to be at least partially independent.

- **Cell of Origin**
 - Müllerian Endometrium
 - Stem cells or precursors individually or in normal mature endometrium.
 - Stem cells or precursors in traumatized endometrium
 - Mesenchymal cells
 - Stromal stem cells
 - Epithelial stem cells
 - Intrauterine or ectopic changes
 - Müllerian Embryonic Remnants
 - Organized fragments
 - Stem cells
 - Müllerian remnants (any congenital)
 - Müllerianosis (organoid and non-organoid including secondary müllerian system)
 - Mülleriosis (non-organoid and projected to include dissemination and transition)
 - Müllerian Tubal Cells
 - Source of ovarian endometriosis
 - Non-Müllerian metaplastic (differentiation) theories
 - Peritoneal or pleural mesothelial coelomic metaplasia (in situ)
 - Mesenchymal stem cells (in situ)
 - Mesoderm (in situ)
 - Bone marrow stem cells (as an engrafting vascular disseminated cell)
 - Mesodermal derivatives such as vascular endothelium
 - Endometriosis can infiltrate, transplant, or metastasize to distal organs.
- **Dissemination (Metastasis) or In Situ Location**
 - Retrograde menstruation, implantation, and infiltration
 - Hematogenous dissemination of endometrium or endometriosis
 - Lymphatic dissemination
 - Uterocervical extension
 - Surgical or traumatic (vaginal delivery) transplantation
 - Growth (expansion or infiltration)

- Embryonic Rests
 - In situ – The normal Müllerian area is the upper vagina, the uterus, and the tubes.
 - Dissemination of embryonic rests to non-Müllerian areas.
 - Pelvic peritoneal area, ovaries
 - Other body areas (bowel, diaphragm, lungs, eyes, and others)
- In situ – coelomic, mesenchymal, and mesodermal metaplasia and Müllerian remnants in normal or abnormal Müllerian area.
- **Stimulus or Stimuli of Initiation, Induction or Activation**
 - Retrograde exfoliated endometrial cells or other products to activate peritoneum.
 - Estrogen
 - Inflammation and infection
 - Microbiome
 - Trauma
 - Surgery, delivery
 - Intrauterine tissue injury and repair (TIAR)
 - Repeated tissue injury and repair in endometriosis (ReTIAR)
 - Serologic factors

- **Window-of-Opportunity**

The onset of symptoms decreases with age. The peak onset is before age 20 and the initiation likely precedes that. (Ballweg 2003, Koninckx 2021) This parallels neuroimmune maturation. (Holder 2014, Simon 2015, Brenhouse 2016)

- **Transition and Growth / Immunosurveillance Disorder**

The transition from normal Müllerian or non-Müllerian stem cells to endometriosis and subsequently to later forms such as infiltrating endometriosis or ovarian endometrioma appears to hold the most potential for future research and therapeutic options. Transition involves changes that distinguish endometriosis from endometrium, Müllerian remnants, or non-Müllerian stem cells. Those changes may begin in in-situ endometrium before dissemination and can involve the local environment, immune modulation, neuroimmune maturation, immunologic dysfunction, immune overload, immune escape, immunologic suppression, histological, biochemical, reactive, angiogenic, immunological, genetically driven, gene regulatory (non-hereditary epigenetic), genetic mutations, implantation, estrogenic stimulation, proliferation, progesterone resistance, progenitor cell differentiation, glycolysis, mitochondrial biogenesis, differential expression of peritoneal mesothelial adhesion factors, loss of tight junctions in the peritoneum, invasion/infiltration, differentiation, growth, expansion, anti-inflammatory cytokines, matrix balance, aberrant regulation of matrix metalloproteinases, tissue remodeling, exposure to endocrine-disrupting chemicals, inflammation, intrauterine tissue injury and repair (TIAR), repeated tissue injury and repair in endometriosis (ReTIAR), intracellular aromatase, endometrial metaplasia, peritoneal metaplasia, tubal metaplasia, differentiation, transdifferentiation, transcommitment, paligenosis, progesterone resistance, environmental gene regulation, environmental toxicants, estrogen-lie

toxicants, endotoxins, oxidative stress, biochemical changes immunologic changes, apoptosis, anti-apoptosis, lack of apoptosis, autophagy, reactive oxygen species, fibrinogenesis, fibrosis, muscular metaplasia, fibroblast to myofibroblast transdifferentiation, macrophage migration inhibitory factor, clonality, microRNA, signaling, nerve activation, cancer-associated driver mutations, neurogenesis, angiogenesis, genetic dysregulation, and central processes. It is not known how many of these cause or contribute to the development of endometriosis and how many are a consequence of a reaction to endometriosis. (Zondervan 2020)

- **Inactivation, Stabilization or Clearance**

Growth is opposed by immunology, inactivation, apoptosis, epigenetic reversibility, scavenging mechanisms including phagocytosis and autophagy/clearance, and suppression of activation/stimulation by decreased estrogens and inflammation.

Concerns and concept include progression, regression, stabilization, normalization of pain, association with müllerian anomalies, heterogeneity, appearances, biochemistry, epigenetics, proteins involved in epigenetic modifications, genetics, congenital anomalies, study populations, analysis protocols, biochemical testing, immunologic testing, stromal markers, epithelial markers, inflammatory reactions, menstrual debris, inflammatory mediators, macrophages, lymphocytes, cytokines, normal immunological reaction, abnormal immunological reaction, cellular immunology, humoral immunology, fibrosis, transitions into mesenchymal cells, fibroblast-to-myofibroblast transdifferentiation, smooth muscle metaplasia, histology, histological stains, histologic technique, histochemistry, stages, phenotypes, aromatase production, hormonal levels, miRNA, nanoparticles, embryology, fetal origins of adult disease neonatal development, genetics, environmental gene regulation (non-hereditary epigenetics), molecular alterations, transcriptional regulation, cell cycle regulation, cell adhesion, organoid development, stromal type endometriosis, endometriosis in men, bone marrow stem cells in endometriosis, differentiated stem cells, primordial germ cells, programmed death (apoptosis), autolysis, oxidative stress, growth factors, vascularization, angiogenesis, pelvic nerve fibers, neuronal growth, neuroangiogenesis, neurogenic inflammation, activators of nociceptive pathways, estrogen receptors, progesterone receptors, progesterone resistance, local pain, peripheral sensitization, central sensitization and comorbid cross organ sensitization.

The older concept of metaplasia as transdifferentiation from mature tissue appears to be incorrect. Metaplasia appears to be one tissue phenotype replacing another as one dies off and is replaced by a new cell type differentiated from stem or precursor cells. See Tosh 2014.

Selection Bias

The heterogeneity of inclusion and diagnostic criteria and selection bias (Ghiasi 2020) affects not only the variability of frequency and distribution but also the reliability of testing. Selection bias is also influenced by referral reason, acceptance of surgery, access to imaging, access to surgical expertise, hysterectomy status, coexisting conditions, and incidental endometriosis. (Shafirir 2018, Horne 2022) Women undergoing laparoscopy for pain differ from those undergoing laparoscopy for infertility. (Shafirir 2018) Selection bias is particularly important in adolescents. Only those with the most severe symptoms undergo surgery. (Shafirir 2018)

Many, if not most studies come from tertiary care practices. The bias in tertiary practices may be best exemplified by Drossman et al. (1977) who published the spectrum of clinical features among patients with IBS. They found major variation in the clinical features of correlation with gut physiology, constancy of symptoms, psychosocial difficulties, and health care use when comparing primary care with tertiary care. Symptoms were not constant and there were no psychosocial difficulties in primary care but those were major issues in tertiary care. Gut physiology correlated less and there was more use of health care in tertiary patients.

Studies that only include women whose endometriosis was diagnosed as part of an infertility evaluation may under-sample women with pelvic pain, as these women may never have come for laparoscopic diagnosis if they had not attempted pregnancy and if they did not have access to an infertility evaluation. (Shafrir 2018)

A failure to understand Ling's 1999 inclusion and exclusion criteria in a tertiary pain practice led to the 2005 ACOG (CO 310) conclusion that GnRH agonists could be used to make a diagnosis of endometriosis. This was subsequently reversed in ACOG PB114 (2010) with the clarification that "empiric therapy does not confirm the diagnosis of endometriosis." Ling's referral bias and his inclusion and exclusion criteria resulted in a study population with an 82% prevalence of endometriosis. Ling's population, or mine, with an 85% prevalence and 72% yearly incidence of endometriosis, should not be compared with a family practice population with a 10% prevalence and 0.25% yearly incidence of new endometriosis patients in their reproductive female population. About 50% of my new patients had endometriosis-associated pain compared with 0.03% in family practice. The 0.03% is 0.25% corrected for 26% reproductive age females in family practice with half having infertility and endometriosis. Better focus is needed to address the problem; expecting 10% yearly in primary care will lead to incorrect conclusions. Similar data is seen in Sarria-Santamera et al. (2020). They summarized 27 papers with 28,660,652 women. The prevalence varied from 1% for population-based integrated information systems to 5% for self-reported data. The incidence varied from 0.13% to 0.35%. A wider range is seen at 0.01% to 0.7% in Christ et al. (2021) and Morassutto et al. (2016).

Moreover, selection bias is but one of many statistical problems seen in trying to understand this perplexing disease. Falcone and Wilson (2019) point out the statistical problems including recurrence of disease is not easily observed, pain is a highly dependent variable, underpowering, unbalanced representation, independent observations, correlated observations, clustered data, repeated measures, hierarchical data structures, standard errors, sample size, assumptions, dependency in correlated data, histologic confirmation, length of follow-up, false-positive rates, overdispersion. Abbott (2020 and 2023) agrees and adds that, we have "An abundance of studies but a dearth of evidence in endometriosis..."

Diagnostic and Screening Tests.

Currently, there are several diagnostic tests evaluated in tertiary populations who were to undergo laparoscopy or had recent laparoscopies with untreated endometriosis. None have been tested as part of a decision tree and followed for success. Those include the the IVD Ziwig saliva test (Bendifallah 2022, Bendifallah 2023), the EndoSure electroviscerography measurement of intraabdominal myoelectrical activity (Mathias 1998, Noar 2022) and others including apps like the Nezhat Endometriosis Risk Advisor (Jackman 2020, Nezhat 2023). These

tests need to be studied and validated in primary care ObGyn, emergency rooms, family practice and the many other areas where they might be useful.

One concern regarding the widespread use of diagnostic tests is their inappropriate use as screening tests. Using diagnostic tests for screening can lead to various problems. Overdiagnosis may result in unnecessary overtreatment, increased costs without any benefit, and potential harm. Furthermore, a negative test could delay the treatment of pelvic pain that has already been normalized. It is crucial to consider endometriosis as a potential cause of pelvic pain, regardless of examinations, imaging findings, non-invasive diagnostic testing (Viganò 2023), or laparoscopic findings. There is no definitive "gold standard" for diagnosing endometriosis, and excluding the condition entirely is not possible. This is another "watch this space" story.

Can We Recognize Endometriosis?

Unrecognized endometriosis is an old concern. The difficulty of visual recognition of endometriosis was first documented in an adherent, but otherwise normal-appearing ovary in 1899 (Russell 1899, Longo 1979). In some patients this has occurred in the absence of other recognized endometriosis. Recently McGuinness et al. (2020) noted that 35% of tubal endometriosis was not seen at laparoscopy. If tubal endometriosis is symptomatic, that might explain why so many women with diffuse pain do not get relief from removal of only focally visualized pelvic lesions. They concluded that *"further evaluation of the postoperative benefits of bilateral salpingectomy for chronic pelvic pain patients with endometriosis would also contribute to our knowledge about the benefits of available treatment options."*

Surgically unrecognized endometriosis has been found in the retroperitoneum (Taussig 1906, Sampson 1926, Javert 1949, Moore 1988, Nezhat 1991, Koninckx 1993, Koninckx 1996, Possover 2007, Possover 2015, Law 2020, Possover 2021), adhesions and scar (Russell 1899, Sampson 1921a, Longo 1979, Griffiths 2007), large and small bowel (Martin 1990c, Kavallaris 2003, Badescu 2016, Badescu 2018, Roman 2021, Martin 2023), appendix (Martin 1990a, 1990c), intraluminal ureter (Zanetta 1998, González-Bonilla 2019, Alenezi 2023), epiploic fat (Martin 1989b), mesentery (Martin 1995), cryptic pockets (Martin 1992, Stuparich 2019), ovaries (Russell 1899, Longo 1979, Candiani 1990), tubes (Yamamoto 1997, McGuinness 2020), and omentum (Zinsser 1982). Endometriosis may not be recognized at surgery because of small size, retroperitoneal location, intratubal location, lesions hidden by adhesions, lesions hidden in the bowel wall, lack of tactile sensation by the surgeon at laparoscopy, or overreliance on imaging. Endometriosis may not be histologically confirmed because of size. (Healy 2010)

Moreover, the problems include not only recognition of endometriosis but also the misdiagnosis of endometriosis as cancer. Case #4 in "Persistent or recurrent endometriosis" (Martin 1999) was originally diagnosed as cancer on a barium enema. One of my (DCM) few unplanned colostomies was because an unanticipated 4 cm endometriotic appendiceal nodule looked like cancer during surgery and was managed as cancer. Recently, Liang et al. (2024) reported a case of rectal endometriosis misdiagnosed and treated as rectal malignancy after three colonoscopies with biopsies. They also review cervical, vulvar, Bartholin, nasolacrimal, anal, umbilical, abdominal wall, renal, hepatic, muscular, pulmonary, diaphragmatic, para-aortic, pericardial, and knee locations. In addition, they update information on increasingly sensitive CT and MRI imaging that can help prepare surgeons for the expected findings at surgery. New advances in intestinal endoscopic techniques add to diagnostic possibilities and preoperative planning.

An adequate clinical exam involves both vaginal and rectal components. A vaginal exam includes the retrocervical area and lateral areas above the posterior vaginal fornix. Stretching that area can locate retrocervical, uterosacral, and rectovaginal endometriotic lesions 1 cm closer to the perineum than a rectovaginal exam (unpublished data). A rectovaginal exam is needed to help determine the extension of a nodule toward the rectal mucosa. An MRI is likely more precise than a rectal exam in determining the position of a nodule with respect to the rectal mucosa. (Arévalo 2017) Sonography was more accurate than laparoscopic video in detecting rectosigmoid endometriosis. Rectosigmoid endometriosis was recognized in only 5.6% of bowel videos contrasted with 96% of sonograms. (Goncalves 2021)

Examination during menstruation increases the ability to locate nodules. (Koninckx 1996). When nodules are found, Hollis's (1984) three steps are used for excision. Those steps are:

- 1) Single finger palpation on exam under anesthesia (EUA) for localization,
- 2) Use a finger or probe to push the nodule up for better recognition/visualization and excision when needed.
- 3) After excision, repeat palpation to confirm that the nodule was removed. Continue excision if the nodule is still present and repeat the steps.

Palpation in the clinic and at surgery has been useful for recognizing endometriosis of uterosacral nodules (Koninckx 1996), retroperitoneal nodules as large as 4 cm (Moore 1988, Koninckx 1993, Koninckx 1996, Griffiths 2007), large and small bowel (Martin 1990c, Roman 2021), appendix (Martin 1993), epiploic fat (Martin 1989b), and mesentery (Martin 1995). Palpation may be facilitated by bowel prep.

Koninckx (1993) noted that in two of 25 women with Type III, the endometriotic nodule could only be found by palpation and in a third woman only during menstruation. Koninckx (1996) subsequently found that five (14%) of 37 women with a painful nodularity during menstruation had retroperitoneal nodules but a normal pelvis at laparoscopy. Moore (1988) discussed five patients with deep retroperitoneal involvement and rectovaginal lesions as large as 4 cm with little or no intraabdominal disease. Griffiths (2007) used indirect palpation with a rectal probe to reveal deep extension of apparent superficial scarring. Martin (1990c) discovered up to 20 palpable nodules at laparotomy which had not been seen at laparoscopy. More recently, Roman (2021) confirmed palpable, non-visualized bowel nodules of 2-mm to 10 mm during bowel resections. An awareness that 2-mm bowel lesions are palpable may help guide bowel examination. Martin (1993) discovered 50% of appendiceal endometriosis on palpation only. Martin (1995) added three mesenteric lesions missed at laparoscopy that were palpable at laparotomy.

Arrington (2020) uses a rectal probe at laparoscopy to better recognize rectal and sigmoid endometriosis as suggested by Reich (1991) and Griffiths (2007). Other possibilities to increase recognition include hand-assisted laparoscopy for palpation and laparotomy.

Possover (2007, 2015, and 2021) recognizes deep sciatic involvement based on history, exam, and MRI. He (2021) found isolated sciatic endometriosis with no connection to the peritoneum in 267 (59%) of 452 patients with sciatic endometriosis. Moreover, 36 (54%) of 67 in group 1 had no other evidence of endometriosis.

Intrinsic (intraluminal) ureteral endometriosis was noted on retrograde pyelogram in 1998 by Zanetta et al. (1998) and removed using a ureteroscope. This was associated with a fibrotic periureteral nodule removed at laparotomy the following month. More recently, González-Bonilla et al. (2019) and Alenezi et al. (2023) limited the surgery to ureteroscopic resection with no laparoscopy or laparotomy. Their patients are doing well on follow-up.

Hidden endometriosis has also been found during dissection (Martin 1992, Possover 2007, Possover 2015, Stuparich 2020).

Endometriosis has been found on histology when it was not noted at surgery (Russell 1899, Sampson 1926, Javert 1949, Longo 1979, Zinsser 1982, Martin 1988, Martin 1990a, Nezhat 1991, Martin 1992, Balasch 1996, Yamamoto 1997, Kavallaris 2003, Badescu 2016, Yeung 2016, Roman 2016, Badescu 2018, Law 2020, McGuinness 2020), by palpation at laparotomy (Taussig 1906, Sampson 1926, Javert 1949, Moore 1988, Stripling 1988b, Martin 1990a, Koninckx 1993, Koninckx 1996, Roman 2021), by ovarian aspiration (Candiani 1990) and using rectal probes during laparoscopy to stretch the bowel surface (Arrington 2020). In addition, adhesions or scars can hide endometriosis (Russell 1899, Sampson 1921, Longo 1979, Griffiths 2007). Up to 88% of rectovaginal nodules were missed at first laparoscopy but identified an intraoperative rectal probe (Griffiths 2007).

Endometriosis has been found in lymph nodes (Taussig 1906, Sampson 1926, Javert 1949, Noël 2008, Lenz 2020) including up to 50% of bowel resections. (Rossini 2016)

As recognition is not always possible, the finding of tenderness 27 mm from the closest visually recognized endometriosis (Demco 1998) may be related to an unrecognized small or retroperitoneal lesion, inflammation, nerve sensitization, referred pain, or other causes.

In addition to the expected difficulty in recognizing endometriosis, there are technical problems that can interfere with recognition. Those include failing to mark the margins, inadequate magnification, lack of palpation, not anticipating palpable 2 mm lesions, not looking in unusual locations, inadequate power density for excisional vaporization, bleeding, use of standard histology processing, coexistent fibroids, coexisting cancer, and tunnel vision.

Although the completeness of removal might be improved by extending the margins or performing laparotomy for palpation, those have been associated with increased complications. The increased completeness may not decrease recurrence sufficiently to justify the increase in complications. (Roman 2018, Redwine 2018, Laufer 2019, Abo 2020, Roman 2020, Roman 2021, Martin 2023) Moreover, smaller lesions are less likely to be tender and may be less likely to progress as are asymptomatic lesions. (Ripps 1992, Moen 2002, Fedele 2004b)

As Martin et al. (1989b) introduced, it's important to distinguish between superficial and deep endometriosis to determine an appropriate surgical technique. The revised AFS (also known as rASRM) stages are insufficient, as demonstrated by Koninckx et al. (1991), who found that deep endometriosis was present in 3%, 34%, 15%, and 22% of women in revised AFS classes I to IV, respectively. This finding was supported by Healey et al. (2010), who found that in a study limited to rAFS Stages I and II, 37% of the patients had deep infiltrating endometriosis. Additionally, Koninckx et al. found that 4% of vesicles and 3% of polyploid lesions were associated with infiltration greater than 2 mm, which suggests that coagulation may not be

effective in 7% of cases with superficial-appearing lesions. However, as Redwine (2018) concludes, not all endometriosis needs to be completely treated.

The revised rASRM Staging System does not score some lesions directly. “The presence of endometriosis of the bowel, urinary tract, fallopian tube, vagina, cervix, skin, etc., should be documented under 'additional endometriosis.’” (ASRM 1997) As an example, bowel lesions have a score if they are hidden in the ovary or associated with other visible endometriosis, partial or complete cul-de-sac obliteration or adhesions. Otherwise, they are rASRM 0-0. A variation on that is endometriosis not recognized at laparoscopy but subsequently recognized on aspiration of endometriotic bloody fluid; those were rASRM 0-0 before and rASRM I to III after aspiration. (Candiani 1990)

Tunnel Vision

Advanced in imaging and laparoscopic recognition using artificial intelligence will reopen concerns for tunnel vision and retroperitoneal nodules. Tunnel vision decreases the recognition of surface peritoneal lesions. Martin (1988) published cases of multifocal endometriosis (satellites) with lesions as large as 7 x 2 x 2 mm and as small as 0.08 mm missed during surgery but seen on imaging. The first was missed because a large powder burn lesion dominated the area and the second required additional magnification. (Martin 1988b,1990d)

This was also a problem for Davis (1988) and Redwine (1991). Davis found no endometriosis at second-look laparoscopy in areas of previous excision, but endometriosis was seen in areas not previously treated. Redwine concluded that 33 of the 35 “new” diagnoses at second look were related to lesions that were missed at his first surgery. He later discussed, in oral presentations, that when he looked at images of his surgeries, he found many, if not most, of those on close examination of his pictures from the first surgery.

In addition, large retroperitoneal endometriotic nodules and lesions hidden in the bowel can be unrecognized. (Griffiths 2007; Roman 2021) These are less of a problem with the increasing resolution of imaging. (Dinh 2020)

Unrecognized retroperitoneal endometriosis, bowel nodules, and peritoneal lesions will become less of a problem with the use of artificial intelligence that is currently in development for radiologic and laparoscopic imaging.

What Size Lesions Can We Detect at Laparoscopy?

In addition to the concerns previously covered on the general difficulty in recognizing endometriosis, there is concern about the resolution of video monitors. In one blinded study of appearance, the blinded reviewers were unable to recognize even surface lesions due to poor contrast (paper in progress). There is the possibility that calibration of monitors might increase recognition and add to patient care.

Small lesions can be associated with pain and large lesions may be asymptomatic. The smallest lesion (0.08 mm) I saw in an adolescent patient with pain was seen on 35mm film but not during surgery. As the 0.08 mm lesion was not seen in real time, the specimen was not processed to look for lesions that small. Neither David Redwine (personal communications), nor Paul Raas using 25× to 40× magnification (1997), nor Camran Nezhat using videolaseroscopy with 4x to 6x magnification (1991), nor I (1988b & 1990d) had histologic confirmation of lesions smaller than

0.2 mm seen at the time of surgery. Moreover, these small lesions were associated with larger lesions. That is also true of the 0.1 mm bowel lesions in Badescu et al. (2016). Because of the association of smaller and larger lesions, it cannot be determined if it is larger lesions, smaller lesions, a combination, an associated inflammatory reaction, nerve stimulation, or other cause that is the source of pain.

Badescu et al. (2016) discovered nonvisualized bowel lesions of 0.1 mm to 10 mm using microdissection of bowel specimens. A subsequent paper from that group using palpation at laparotomy detected non-visualized bowel endometriosis of 2 mm to 10 mm in 25% of patients with 14% at or past the planned staple line. (Roman 2021)

As a contrasting concern, a patient with an asymptomatic, infiltrating, rectovaginal endometriosis of 4 cm, was seen in the posterior upper vagina on a yearly exam by a primary care physician and referred to oncology and then to me. She remained asymptomatic with no change in size on exam and or MRI for seven years before she moved to another state. Her disease was like the 93% non-progressive asymptomatic rectal nodules reported by Fedele et al. (2004b) and 72% non-progressive symptomatic rectal nodules by Netter et al. (2019). The chance of future surgery is even less at 3% for asymptomatic mild endometriosis seen at tubal ligation. (Moen 2002)

As a tangential concern, the revised AFS (also known as revised ASRM) stage I and II include deep endometriosis. As an example, Healey et al. (2010) limited their study to stages I and II to avoid deep disease. But, they had deep in 37% of their patients. This inadequacy of was also demonstrated by Koninckx et al. (1991) who found deep in 3%, 34%, 15%, and 22% of women in revised AFS classes I to IV respectively. Deep endometriosis was more common in mild stage II than in severe stage IV endometriosis in that study.

When Does the Cell of Origin Become Endometriosis?

Munaza Afaq M.B.B.S. and Dan C. Martin, MD

This question raises related inquiries: how do cells of origin result in the development of endometriosis, what triggers the development of endometriosis or endometriotic lesions, and when can we say that endometriosis has developed, whether it be from retrograde endometrium, congenital rest, peritoneal stem cell, or venous disseminated bone marrow stem cell transforms into endometriosis or when during development they should be considered as a disease remains unanswered (Sampson 1921a, Redwine 2002, Zondervan 2018, Zondervan 2020). The characterization of endometriosis, or in other words, the criteria for a disorder to be labeled as endometriosis, is extensively discussed in literature but lacks a definitive conclusion. This may be due to the diverse mechanisms of origin, a decreased window of opportunity, the possible spectrum of the disease, delayed diagnosis, and the limited availability of disease models and non-invasive diagnostic methods. Potential components of the criteria may include the presence of endometriotic (endometrium-like) glands and stroma, symptoms, persistence, progression, inflammatory reaction, vascularization, bleeding, fibrosis, epigenetic changes, genetic mutations, or the presence of CD10, IFITM1, BER-Ep4, Calretinin, CD34, anti-endometrial antibodies.

Definitions of endometriosis include Zegers-Hochschild et al. (2017) who required the presence of endometrium-like epithelium and stroma outside the endometrium and myometrium and ICD-11 as the ectopic growth and function of endometrial tissue outside the uterine cavity. Koninckx et al., in 1994, however, argued that symptoms are essential for the condition to be considered a

disease, as retrograde menstruation is relatively common in women, but not all women develop endometriosis. Therefore, implanted tissues may either result in subtle lesions or disappear over time. They proposed using the term "endometriotic disease" for severe symptomatic presentations and "endometriosis" for mild/subtle cases or even considering it a normal process that intermittently occurs in all women. Similarly, if pain or growth is required in the definition, even large lesions may not meet the criteria. Fedele et al. (2004b) followed 88 patients with untreated asymptomatic rectovaginal endometriosis for 1 to 9 years and found that only 2% of them had specific symptoms attributable to rectovaginal endometriosis and associated with an increase in lesion size. Those two patients underwent surgery, while 5% had an increase in lesion size but remained symptom-free, and 93% showed no clinical or imaging changes and remained stable. Tica et al. (2006) reported the removal of an incidental 3-cm asymptomatic abdominal wall endometrioma during a repeat C-section 15 years after the previous C-section. Furthermore, Koninckx et al. (2019) also observed that some large lesions might not cause pain. Moen (2002) concluded that asymptomatic lesions seen at tubal ligation are unlikely to become symptomatic even with 12 to 14 years of follow-up.

Brosens (1997) considered endometriosis to be physiological unless recurrent bleeding in the implants caused progressive disease and symptoms. Guo's ReTIAR (2018a) is based on recurrent bleeding, while Canis et al. (2016, 2019) concluded that endometriosis may not be a chronic disease in the absence of local trauma. Evers (2005) concluded that glands and stroma outside the uterine cavity must persist and progress to be considered pathological, in contrast to the pimple model, which considers early lesions causing inflammation as potentially symptomatic and transient pathology (Martin 2005). This implies that non-progressive rectal nodules, as reported by Fedele et al. (2004b), Chapron (2010), and Netter et al. (2019), are not persistently pathological. Vigano et al. (2018) suggested that fibrosis is necessary for endometriosis to be considered a disease, similar to Guo (2018a) and Canis et al. (2016, 2019), as discussed earlier.

With recent research, pathogenesis is increasingly considered in defining endometriosis. The World Endometriosis Society Consensus defined endometriosis as an inflammatory disease process characterized by lesions of endometrium-like tissue outside the uterus that is associated with pelvic pain and/or infertility (Johnson et al. 2017). Furthermore, the International Working Group attempted to consolidate the definitions of endometriosis in a consensus paper, defining it as a disease characterized by the presence of endometrium-like epithelium and/or stroma outside the endometrium and myometrium, usually with an associated inflammatory process while defining other forms of the disease as subtypes with their specific characteristics (2021). Hence, there does not seem to be a single picture or set of criteria that defines endometriosis as a disease. Instead, it appears to be a spectrum of manifestations that can evolve over time, ranging from transient pathology to more severe lesions.

Endometriosis is largely considered to be an estrogen-dependent and inflammatory disorder. The cell of origin goes through a myriad of changes once it appears in the non-native location to be able to initiate the lesion of endometriosis. This likely requires an initiating event or trigger for the disease process to commence after the cells of origin appear in a non-native location. Many studies have demonstrated that endometrial stromal cells (ESCs) possess the ability and are accountable for adhering to the peritoneal surface's mesothelium (Witz CA et al., 1999, Nisolle, M. et al., 2000, Witz C, et al., 2002). More recent research has also explored the role of endometrial stem cells in initiating ectopic endometrial lesions (Gargett CE et al. 2010, Gargett CE et al. 2011, Gargett CE et al. 2014), particularly in premenarchial endometriosis (Brosens I et

al. 2013). Following attachment, epithelial and stromal cells gradually restructure into endometrial glands (Nisolle, M. et al., 2000). The peritoneal lining's role in facilitating the onset and progression of endometriotic lesions has also been investigated, with factors such as changes in adhesion molecules, epithelial-to-mesenchymal transition, and reduced immune defense being implicated (Young 2013). Moreover, Donnez J. et al., 2001 were the first to demonstrate that an intact peritoneum does not hinder endometrial implantation. Efforts have been made to determine the time frame during which cells of origin form endometrial lesions. Attachment to the peritoneal surface was observed to occur as early as 1 hour (Witz CA et al. 2003) or 1 day (Nisolle, M. et al. 2000). However, the challenge lies in pinpointing the transition from attachment to transmesothelial invasion, as it happens swiftly. Nevertheless, some studies suggest that transmesothelial migration can occur as quickly as 24 hours (Witz CA et al. 2001, Witz CA et al. 2003).

The cell of origin of the endometriotic lesion experiences hypoxia and hormonal imbalance upon exposure to a non-native location. The migrated endometrial cells have been studied to possess a complete set of steroidogenic enzymes that increase local estrogen levels. Excessive estrogen, particularly estrogen receptor 2 (ESR2), attracts immune cells and activates the critical pathway of prostaglandin synthesis, leading to inflammation and inhibiting apoptosis. ESR2 also activates tumor suppressor genes and angiogenic proteins, triggering epithelial-mesenchymal transition and promoting lesion progression. Hypoxia further induces angiogenesis from endothelial progenitor cells of the bone marrow, aiding in the survival of the lesion. Progesterone, which primarily acts through estrogen receptor 1 (ESR1), which is less abundant in endometriotic lesions, is unable to effectively limit estrogen levels, contributing to progesterone resistance. (Kapoor 2021)

If endometriosis occurs when endometrial cells are exposed to a non-native environment, it raises the question of why not all women who experience retrograde menstruation, which happens in more than 90% of women, develop endometriosis or experience lesion progression. Although abnormalities in steroid hormone receptors have been found to have genome-wide effects with defective epigenetic reprogramming, gene mutations have not been consistently detected in endometriosis, despite it being more common in women with a family history of the condition. However, epigenetic aberrations in stromal cells have been implicated in the onset and progression of endometriosis. Differential methylation is a central mechanism that upregulates estrogen receptor 2 (ESR2) in endometriosis stromal cells. Defective epigenetic reprogramming may also contribute to progesterone resistance. It is unclear where these epigenetic aberrations occur first, whether in the eutopic endometrium (within the uterus) or the ectopic lesion (outside the uterus). There may be risk factors in the endometrium or the immune response that clear shed cells, predisposing them to lesion formation and progression. Stem cells in the endometrium have also been proposed to play a role in this process, as these may be epigenetically programmed to switch hormonal balance and become more likely to form lesions once outside the uterus. These stem cells have increased expression of ESR2, which is implicated in driving the pathogenesis of endometriosis. Additionally, natural killer cells, which are involved in immune response, have been found to have lower activity in endometriosis, which could account for poor clearance of endometriosis cells from the peritoneal cavity. (Yilmaz et al., 2019)

Another major issue in endometriosis is infertility, which cannot be fully accounted for by the mechanical impact of lesions and may not be alleviated by surgically removing them. One potential explanation for this is the development of a decidualization defect due to progesterone

resistance (PR resistance). With PR resistance increasingly being linked to infertility, various mechanisms have been proposed that explain this. Studies in baboon models have shown that a PR-resistant phenotype can develop in the endometrium as endometriosis advances, potentially due to bidirectional cell movement or eutopic endometrium's epigenetic reprogramming under the influence of inflammation caused by lesions. PR resistance could also be inherited from stem cells with defective programming (Macer et al., 2012). Chronic inflammation in endometriosis impacts endometrial receptivity in the eutopic endometrium, affecting fertility (Lessey BA et al. 2017). Alterations in progesterone receptors, integrins, steroid enzymes, and other crucial molecules like IL-6, IL-17, STAT 3, HIF1A, and BCL6 have been studied to affect the eutopic endometrium (Lessey BA et al. 2017). A recent study has shown the role of non-mutated activation of KRAS-mediated BCL6/SIRT1 complexes, significantly contributing to progesterone resistance (Yoo JY et al. 2017). Progesterone resistance interferes with decidualization, which prepares the endometrial lining for embryo implantation, and fosters anti-apoptotic pathways and cell survival in endometriosis lesions, leading to infertility in endometriosis (Macer et al., 2012).

In conclusion, endometriosis is a complex disease characterized by a spectrum of manifestations, diverse mechanisms of origin, and a range of severity. While the precise criteria for its diagnosis and the exact point at which cells of origin transform into endometriosis remain unclear, the disease is generally recognized as estrogen-dependent and inflammatory in nature. Factors such as epigenetic aberrations, progesterone resistance, and alterations in immune response have been implicated in the initiation and progression of endometriotic lesions. Despite advances in research, endometriosis continues to pose challenges in diagnosis and treatment. A more comprehensive understanding of the disease's pathogenesis and predisposing factors is essential for the development of better diagnostic tools and more effective therapeutic strategies.

Excision or Ablation for Endometriosis?

Katie Edmonds, FNTF, Martin L. Robbins, MD, and Dan C. Martin, MD

Controversy exists regarding the use of ablation rather than excision. Some have expressed concern that ablation is inadequate for removing endometriosis. Others point to randomized data that shows no significant difference. As endometriosis is a heterogeneous disease, even well-designed studies do not always answer the question asked, especially with the average six-to-10-year delay that it takes for patients to receive this care. Making the matter even more complex, Bougie et al. (2021) found that 75.8% of women had no further surgery after diagnostic laparoscopy with no surgical treatment. This suggests that most women can be managed after a diagnosis of endometriosis without surgical treatment. Just knowing they have endometriosis might be enough to keep most patients out of future surgery. (Bougie et al. 2021) Neither hysterectomy nor excision nor ablation cure pain for all women. (Bougie 2021, Mackenzie 2023)

Ablation refers to five or more techniques. One involves using heat from electricity or other sources to destroy endometriotic implants on the peritoneum's surface or with superficial extension. A second technique is laser vaporization, which turns the lesion into a plume of vaporized water, tissue, and carbon. It's worth noting that the use of lasers for ablation is different than their use for excision, where they are employed as a hot knife. Examples of CO2 laser excision are on images 1, 2, 41, and 42 at <https://www.danmartinmd.com/files/lae1988.pdf>. A third technique is harmonic scalpel to coagulate or excise endometriosis. Sclerotherapy, the

fourth, uses ethanol or other caustic agents. Cryoablation is the fifth and can freeze abdominal wall endometriosis.

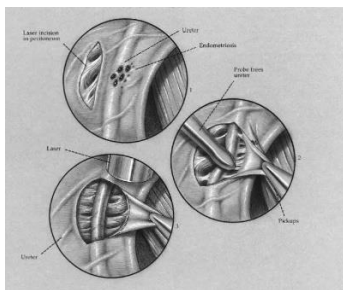
When examining the research comparing the two techniques, it's clear that published data is insufficient to determine the optimal approach. As endometriosis is a heterogenous disease, even well-designed studies face challenges when trying to uncover the best surgical outcomes.

Surgical outcomes are also influenced by factors beyond the technique used alone. There is a wide range of skill levels among physicians who perform surgery, varying from inadequate to highly skilled. Additionally, doctors often base their approach on their experience, judgment, and previous observations rather than solely on data. This means that the experience of one patient with ablation or excision can vary widely from another patient, solely based on the doctor performing the surgery. Therefore, data may pertain to either or both the technique used or the surgeon performing the procedure. If a surgeon doesn't know what to look for and how to remove it, surgical outcomes will be less than positive no matter which technique is used (see limitations to research below).

Although published data has such limitations, the scientific literature clearly demonstrates that each technique has advantages and disadvantages depending on the stage and depth of the endometriotic nodules.

Advantages of Excision

- The lateral and deep treatment margins can be seen.
- The limits of excision are more visually apparent than with ablation.
- Can provide a more complete removal of tissue and better recognition of deep structures.
- Can work for deep, bowel, ureteral, and other sites of endometriosis
- Does not crush specimens as much as biopsy forceps.
- Does not slide off specimens like biopsy forceps.
- Can provide better tissue for histology and clarification of what was taken out.
- Can decrease the chance of misdiagnosis.
- Can decrease the chance of missing coexistent pathology including cancer.
- Complete en-bloc removal of disease decreases the chance of incomplete margins, missing pathology, fragmentation, spreading pieces of the endometriosis, and losing track of identified endometriosis.
- Required to clarify the depth of infiltration in some cases (Koninckx 1991) and thus to confirm that apparent superficial endometriosis is actually superficial.
- Is more precise and can be less dangerous than ablation near vital organs, as in dissecting peritoneal lesions off the ureter. Lesions over the ureter are peritoneal in 95% of cases. Lesions that look superficial/peritoneal are confirmed in 96% of cases. The loose connective tissue is pushed away from the lesion, not the ureter from the loose connective tissue, to decrease ureteral trauma and vascular damage.



Martin & Rock 1992

Disadvantages of Excision

- May not be necessary (Redwine 2018)
- Fewer surgeons are available.
- Insurance coverage may not be as good or sometimes not even available.
- Patients can have longer waiting times to get to surgery.
- Patients may have to travel for services.
- Operating room and anesthesia times can be longer.
- There is a longer learning curve for physicians.

Advantages of Ablation:

- Almost all surgeons are trained in bipolar coagulation as it is useful for hemostasis.
- Almost no complications when used appropriately.
- Ablation is generally covered by insurance.
- Works for surface peritoneal surface and some superficial endo with few complications.
- Limited treatment can be all that is needed. (Redwine 2018, Evers 2013, Fuentes 2014)
- Operating room and anesthesia times can be shorter.
- The learning curve for physicians is shorter than excision.
- Five prospective studies and three reviews conclude that ablation is equivalent to excision for superficial and mild endometriosis. (Wright et al. 2005; Wright et al. 2005; Healey et al. 2010; Radosa et al. 2010; Barton-Smith (thesis) 2010; Riley et al. 2019; Bafort et al. 2020, Burks et al. 2020; and Falcone and Wilson 2019; Radosa et al. 2010; Barton-Smith (thesis) 2010; Riley et al. 2019; Bafort et al. 2020, Burks et al. 2020; Falcone and Wilson 2019).
- Healey et al. 2014 found that 12 or 13 variables did as well with ablation as excision in a study that combined superficial and Stage I-II into the analysis. Only dyspareunia of the 13 variables showed a significant difference.

Disadvantages of Ablation

- The treatment margins are more often distorted and, thus, the limits cannot be determined.
- The limits of excision are less visually apparent than with excision.
- Ablation with wide margins might not have been published or studied.
- Bipolar coagulation depth, though good for superficial surface endometriosis, is not predictable at more than 2 mm. Semm (1980) began the use of partial excision to avoid

deep coagulation of large nodules. Semm's techniques led to the development of complete excision techniques. See Semm 1980, 1981, 1984, 1987; Martin 1985, 1986a, 1986b, 1986c, 1986d, 1987, 1988a, 1989; and Redwine 1988a, 1990, and 1991.

- Song et al. (2009) reported bipolar electrosurgical thermal effects at up to 11.5 ± 9.3 mm in lab testing.
- Laser vaporization for deep endometriosis is difficult to use effectively due to tissue distortion.
- Coagulation and vaporization can cause thermal distortion of tissue and obscure visualization as seen on page 27 of the [Appearance of Endometriosis](#). (Martin 1990d)
- Though complications are rare when ablation is used appropriately, they can occur.
- Thompson and Wheelless (1973) documented 11 cases of gastrointestinal complications using monopolar electrosurgery for tubal sterilization at the Johns Hopkins Hospital. Yoon, Wheelless, and King (1974) summarized the replacement of monopolar by the Yoon silicone rubber band technique at the Johns Hopkins Hospital. At that time, Rioux and Cloutier (1974) introduced bipolar electrosurgery for laparoscopic sterilization.
- Wheelless (1977) reported thermal spread of monopolar contact electrosurgery at 5 cm in lab testing.
- Coagulation or vaporization can damage vital structures without being seen.
Note: Two of the three complications in Khare et al. (1993) were from excision and one from ablation. A discussion is later in this section.

Concerns of both excision and ablation

- Bougie et al. (2021) found that 75.8% of women had no further surgery after diagnostic laparoscopy with no surgical treatment. This suggests that most women can be managed after a diagnosis of endometriosis without surgical treatment. Just knowing they have endometriosis might be enough to keep most patients out of future surgery.
- We do not know if histologic documentation of endometriosis adds to the care of endometriosis patients other than by excluding other diseases like cancer. There has been a [reward](#) since 2007 for data that proves otherwise.
- Wide peritoneal margins do not treat hidden deep, tubal, bowel, or other endometriosis.
- [Complete recognition is not currently possible](#) with any technique. Thus, “complete excision” does not exist in all women.
- Excision or ablation can inadvertently damage organs. (Khare 1993)
- Roman et al. (2020) reported colostomy, bowel fistula, bladder dysfunction, and hydronephrosis associated with complex deep endometriosis cases. See “Cover” on page 5.
- Metzemaekers et al. (2021) reviewed significant complication rates of up to 14% in complex surgery, which include enterotomy, anastomosis leakage, damage of the urinary tract, fistula formation, and even temporary or permanent colostomy (bowel bag).
- Wide margins are reported to improve results possibly because of multifocal disease (Badescu 2016, Roman 2021, Yeung 2011), other peripheral causes of pain (Demco 1998, Dückelmann 2021), or the positive bias of surgeons analyzing their own results.

Semm (1980) was the first to publish the use of partial excision for nodular disease. Martin et al., (1989b) Cornillie et al. (1990), and Koninckx et al. (1991) discussed deep as 5 mm or more deep to the peritoneum. Davis et al. (1993) concluded that 3 to 5 mm might be a more reasonable limit. Excision for deep endometriosis is a consensus opinion tested in only one randomized study; even that one has not been peer-reviewed. (Barton-Smith 2010)

The use of excision for deep endometriosis contrasts with ablation (coagulation or vaporization) for superficial (2 mm or less depth) endometriotic disease. Although ablation techniques are not predictable at a depth greater than 2 mm, they may suffice for superficial peritoneal lesions. For instance, examples of 0.08 to 0.4 mm lesions are displayed on images 21 and 22 on page 5 of <https://www.danmartinmd.com/files/lae1988.pdf>. Also on that page, the 3 mm polypoid lesions in image 23 can be removed with biopsy forceps and the base coagulated as performed by Semm (1980). Koninckx et al. (1991) have considered the limits of coagulation at 2 mm and concluded that coagulation might be successful in treating 96% or more of superficial appearing lesions, given that complete treatment may not always be necessary. Nevertheless, due to the unpredictable depth of ablation, ablation is not employed over vital structures like the intermediate (3 mm deep) lesions on top of the ureter on page 9, image 41 in the same 1988 publication. The appearance of an exposed ureter after excision is in image 42.

Ablation is equal to excision for superficial and minimal to mild disease but randomized controlled trials with longer follow-ups are necessary. The most recent Cochrane review (Bafort 2020), Burks et al. (2020), and Falcone and Wilson (2019) support this view. However, the most recent Cochrane review also concludes that there is inadequate evidence that surgical treatment of superficial peritoneal endometriosis is effective. A unique finding is that Burks et al (2020) noted in Radosa et al. (2010) that excision had a higher recurrence at 18.6% than electrocoagulation ablation at 2.8%.

The 2022 ESHRE guidelines (Becker et al. 2022) suggest that “clinicians may consider excision instead of ablation of endometriosis to reduce endometriosis-associated pain,” This is a “weak recommendation” from references that includes Pundir et al. (2017) whose paper was found to include faulty statistics (Chen 2017; Gu 2018) and did not include Barton-Smith’s (2010). data on superficial endometriosis in tables 35 or 36. Those tables show no difference between excision or vaporization for superficial endometriosis. Pundir et al. and Barton-Smith use the wording “both superficial and deep disease” to mean “both superficial and deep disease combined” rather than individually. The other papers reviewed by ESHRE also found no difference between excision and ablation.

Although Healey et al. (2010, 2014) showed improvement at five years after excision compared with one year, but this was for revised AFS (rASRM) stages I and II and included deep disease in 53% of the excision group and in 22% of the ablation group. This was despite excluding stage III and IV because they felt that electrocoagulation was not a “suitable treatment modality for nodular or deep infiltrating disease.” There were no differences at one year. (Healey 2010) Only one of the 13 VAS-rated criteria (dyspareunia) was significantly reduced in the excision group at five years. (Healey 2014)

The protocol for Healey et al. (2010 and 2014) excluded stage III and IV because they felt that electrocoagulation was not a “suitable treatment modality for nodular or deep infiltrating disease.” However, due to the inadequacy of the revised ASRM (AKA rAFS) stages to correlate with depth, they included deep disease in 53% of the excision group and 22% of the ablation

group. They found that 37.3% of Stages I and II had deep endometriosis. Koninckx et al. had similar data with more deep in Stage II (34%), than Stage IV (22%), Stage III (15%), and Stage I (3%) respectively. Deep endometriosis was more common in mild stage II than in severe stage IV endometriosis in that study.

The superficial lesion and minimal/mild stage reviews mentioned above are based on only one to four primary papers of the thousands that are published. Burks et al. (2020) reviewed 2,608 articles before selecting the four they analyzed. They excluded nonrandomized series and case reports. Case reports included inadequate vaporization of even superficial endometriosis using a low-power laser on page 27 of the Color Atlas (Martin 1990c) and inadequate coagulation (Martin 1999). Moreover, a Google Scholar search for endometriosis and excision or ablation or coagulation or vaporization lists 102,000 citations. This large number of papers not included in the reviews may be part of why physicians rely more on experience, judgment, and past observations than on systemic reviews. Systemic reviews do not represent the entire story.

Koninckx et al. (1991) have considered the limits of coagulation at 2 mm and concluded that coagulation might be successful in treating 96% or more of superficial appearing lesions, given that complete treatment may not always be necessary. Nevertheless, due to the unpredictable depth of ablation, ablation is not employed over vital structures like the intermediate (3 mm deep) lesions on top of the ureter on page 9, image 41 in the 1988 [Laparoscopic Appearance of Endometriosis](#). The appearance of an exposed ureter after excision is in image 42.

The use of excision for deep endometriosis contrasts with ablation (coagulation or vaporization) for superficial (2 mm or less depth) endometriotic disease. Although ablation techniques are not predictable at a depth greater than 2 mm, they may suffice for superficial peritoneal lesions. For instance, examples of 0.08 to 0.4 mm lesions are displayed on images 21 and 22 on page 5 of [Laparoscopic Appearance of Endometriosis](#). Also, on that page, the 3 mm polypoid lesions in image 23 can be removed with biopsy forceps and the base coagulated as performed by Semm (1980).

All surgery comes with risks, benefits, advantages, and disadvantages. This is particularly important in bowel surgery. Even David Redwine (2018) agrees that there are times when we should “leave it alone” such as residual microscopic lesions in the bowel that “carry a very low risk of progressing to clinically significant disease.” Even limited bowel procedures have sufficient success rates to avoid extended bowel resection and increased complications for more complete removal. And no matter how extensive a bowel resection is, there is no way to be sure that we have recognized or removed all endometriosis. This is covered in the section "[Can We Recognize Endometriosis?](#)" in this publication.

Complications of either excision or ablation usually arise from the depth or location of the area treated. Ablation, which is generally a superficial surface (less than 2mm) technique, can be unpredictable and dangerous if the surgeon tries to go beyond the surface. It's usually avoided near critical structures because of the risk involved. Excision, on the other hand, is used everywhere, including bowel resection and colostomy for endometriosis, and excision of hearts before heart transplants for heart disease. Jaiswal and Huang (2017) reviewed the history, use, and complications of energy devices for laparoscopy.

Of the three cases described in Khare et al. (1993), two were during the normal use of excision, while one was during the negligent use of ablation. In the ablation case, "*deep endometriosis was*

not anticipated but was found adjacent to the right side of the rectum. Bipolar electrosurgery was used to desiccate the lesion in its entirety." My usual response to unanticipated endometriosis near a vital structure like the rectum is to avoid it, assess the lesion through exams potentially combined with transvaginal ultrasound, rectal ultrasound, MRI, sigmoidoscopy, colonoscopy, etc., and decide who is qualified to do the surgery. Then set up a team or refer them for advanced care.

In Europe, Horace Roman in Bordeaux, France, is one example of a qualified physician for this kind of surgery. His video with a text transcription is "Primum Non Nocere vs. Definitive Bowel Surgery for Endometriosis." It can be found at <https://www.endofound.org/horace-roman-md-phd-primum-non-nocere-vs.-definitive-bowel-surgery-for-endometriosis>.

As stated by Abbott (2020), there is "an abundance of studies but a dearth of evidence in endometriosis." "Expertise is recommended to optimize care." Falcone and Wilson (2019) point out statistical problems including the recurrence of disease is not an easily observable event, pain is a highly dependent variable, underpowering, unbalanced representation, independent observations, correlated observations, clustered data, repeated measures, hierarchical data structures, standard errors, sample size, assumptions, dependency in correlated data, histologic confirmation, length of follow-up, false-positive rates, and overdispersion. Focus and experience are needed not only for the surgeon but also for analysts.

Moreover, data generally analyze the surgical or research process used and not the experience of the surgeon, although surgeon experience is as important as the technique employed. The data previously discussed in this section are from tertiary care groups and may not reflect the experience of all surgeons. Martin's (1990a) recognition research was on research documentation rather than clinical recognition. It demonstrated a near-linear variation in physician documentation of surgical recognition of endometriosis based on surgical volume for histologically positive cases. Physicians performing <6 cases documented only 41% of cases diagnosed by pathologists annually while one physician did 127 cases and documented 86%. The 14% that Martin (1990a) missed were red and other lesions that had been labeled as "rule out endometriosis" or lesions hidden in adhesions. Although this study was on documentation, it suggested variation in recognition. That study was not STARD compatible and the protocol was inadequate to be clinically useful. (Bossuyt 2003; Dekel 2005) Still, it's important to note that the data discussed in this section are from tertiary care groups and may not reflect the experience of all surgeons, especially those with little experience or specific trained in endometriosis diagnosis and surgical treatment.

In conclusion, excision is the consensus standard for treating deep infiltrating endometriotic nodules seen on exams, sonograms, or MRIs that result from a 6- to 10-year delay in treatment in 3% to 30% of those with endometriosis seen in tertiary care. Superficial lesions and mild endometriosis may respond as well to ablation as to excision. Because it's possible for all stages of endometriosis to present with deep nodules, both techniques employed within the same surgery may indeed offer the best outcomes. Better data is needed. However, surgery is not the only answer; this is covered in the next section.

Surgery is Not the Only Answer, Proactive Holistic Care.

Katie Edmonds, FNTF and Dan C. Martin, MD

For early disease, the use of hormonal suppression, diet, lifestyle modification, anti-inflammatory therapy, antioxidants, treatment of infection, decreasing immune reactions, control of endotoxins, control of oxidative stress, and an integrative framework with involvement of the patients, their families, and their primary care providers are necessary considerations to address the chronic inflammation and immune dysfunction that drive the disease.

We speculate that those considerations may keep some women from needing to see surgical specialists and might increase the 75.8% of women who needed no further surgery after a diagnostic laparoscopy with no surgical treatment. (Bougie 2021) This suggests that most women can be managed after a diagnosis of endometriosis without surgical treatment. Just knowing they have endometriosis might be enough to keep most patients out of future surgery. Most women do not need ablation or excision.

As an example of associated care, Mier-Cabrera et al. (2009) examined how increased food consumption of antioxidants could counter oxidative stress in women with endometriosis with compelling results. The researchers applied a high-antioxidant diet to women with endometriosis by including 1050iu beta carotene, 500 mg vitamin C, and 20 mg vitamin E per day. This was achieved by eating 8 servings a day of assorted fruits and vegetables, plus 4 tbsp pumpkin seeds and 3 tbsp peanuts. No supplements were consumed. After switching to this higher antioxidant diet, the women with endometriosis had some dramatic gains. Researchers found that their serum levels of these antioxidants rose after just the first month, while their endogenous antioxidants SOD and glutathione levels after three months. Oxidative stress markers were reduced by 20% after 3-months.

Mathias et al. (1998) found that bacterial overgrowth associated with endometriosis symptomatology responded to eight weeks of treatment with clonazepam (0.25 mg 3 times per day) to slow bowel motility, dietary changes, reduction of glycemic carbohydrates, balancing with omega-9 oils, elimination of foods with caffeine and tyramine, and addition of omega-3 fatty acids. After treatment, there was a significant reduction in the total endometriosis-associated bowel motility score. Antibiotics were not necessary. There was a significant reduction in the total endometriosis-associated bowel motility score after treatment.

Clower et al. (2022) demonstrated that endometriosis is linked to increased levels of reactive oxygen species and oxidation products but a decrease in antioxidants and detoxification enzymes, along with iron metabolism dysregulation. The high levels of oxidative stress contribute to inflammation, angiogenesis, cell proliferation, and extracellular matrix degradation, which may explain its involvement in endometriosis. The pain associated with endometriosis is believed to be caused by neurogenic inflammation and a feed-forward mechanism that involves macrophages, pro-inflammatory cytokines, and pain-inducing prostaglandins. Encouragingly, certain supplements such as N-acetylcysteine, curcumin, melatonin, and a combination of vitamins C and E have shown promising results in the treatment of endometriosis.

Dietary management of endometriosis was reviewed by Gutke et al. (2021) and Kobayashi et al. (2023b) and Katie Edmonds' two books at [Resources](#). Studies in parallel diseases are encouraging. Abbott et al. (2019) demonstrated clinical improvements in Hashimoto's while

Chandrasekaran et al. (2019a) demonstrated improved symptoms of inflammatory bowel disease patients. Chandrasekaran et al. (2019b) demonstrated changes in the epigenetic expression of inflammation via numerous markers. Santanam et al. (2013) demonstrated increased antioxidants via supplementation and saw the quality of life go up while inflammatory markers in the peritoneal cavity decreased. In 2009, women who simply increased the amount of antioxidant-rich food they ate (basically more fruits, veggies, and nuts) had their antioxidant levels rise significantly while their oxidative stress lowered.

Control of these factors may stop or limit endometriotic lesions if started early when lesions are small and before they have time for significant inflammation, fibrosis, angiogenesis, epigenetic modifications, and genetic mutations. Alleviating the chronic inflammation and immune dysfunction that contribute to the disease may potentially prevent disease progression, scar tissue formation, and adhesions. Early treatment may also decrease stress-related exacerbation of endometriosis-associated generalized hyperalgesia. (Long 2016) Control of pain and its associated problems may increase the spontaneous improvement of endometriosis, which occurs in about 42% of endometriosis sufferers reviewed by Evers (2013) or the 5.7% of all women with coincidental endometriosis in 15 studies reviewed by Fuentes et al (2014). If so, surgery may be avoided.

Knox et al. (2019), in an adolescent referral center, followed adolescents with dysmenorrhoea an average of 10.24 years. As adults, 41 (58.6%) reported seeking further medical management for dysmenorrhoea and 43 (61.4%) reported being happy with their treatment. 24 (34%) participants had a laparoscopy. Endometriosis was found at 13 of these (19% of total or 54% of laparoscopies), ovarian cysts in five (7% and 21%), and no abnormalities in three (4% and 17%). Notably, all had mild disease. None had moderate or severe disease.

However, these therapies are less likely to work after six to ten years of delay and the development of deep infiltration with inflammatory changes, epigenetic changes, and DNA mutations. By then, excision is the approach most likely to be successful for all cases.

Although some of these approaches are still considered speculative for endometriosis, they are correct for the comprehensive treatment of pain and dysmenorrhea, both of which suggest the presence of endometriosis in primary care, especially in teens, and potentially for those with deep nodules. If the comprehensive treatment of pain helps stop endometriosis in the process, that would be a bonus.

A concern is that even asymptomatic endometriosis may progress (Moen 1991, Brosens 2013) or be associated with complications such as silent loss of a kidney (González-Bonilla et al. 2019; Yang et al. 2021). Ernst (2018) reviewed alternative medicine and concluded that symptomatic relief could result in misdiagnosis and avoidable delay of significant disease. In the presence of spontaneously asymptomatic endometriosis, subsequent care is needed from 2% (Fedele 2013) to 3% (Moen 2022) to 9.7% (Fedele 2013). If we correct that for normalization, we anticipate higher percentages and numbers to be at risk. We do not know if therapeutically asymptomatic will have the same, higher, or lower progression than spontaneously asymptomatic endometriosis. We anticipate that patients like the one on the [cover](#) need long-term surveillance to assess them for possible progression. Moreover, with our [inability to recognize all endometriosis](#), there are concerns concern for all who are diagnosed with or thought to have endometriosis. Neither surgery, nor contemporary medicine, nor complimentary medicine, nor alternative medicine, nor the body's immune and reparative systems cures all endometriosis.

Subtle Inflammatory Lesions, Infection, Bacterial Overgrowth, or Both?

The association of inflammation with endometriosis has a long history. Sampson (1926) discussed menstrual blood irritating the peritoneum causing inflammatory exudation, granulation tissue, adhesions, and peritoneal inclusions. He subsequently published histology of endometriosis associated with an inflammatory exudate like gonorrhea and cancer (Sampson 1927a). Mathias et al. (1998) found that bacterial overgrowth associated with endometriosis symptomatology responded to eight weeks of treatment with the antiseizure medication clonazepam to slow bowel motility, omega-9 oils, omega-3 fatty acids, dietary changes, reducing glycemic carbohydrates, and eliminating of foods with caffeine and tyramine. After treatment, there was a significant reduction in the total endometriosis-associated bowel motility score. Antibiotics were not necessary. Post-treatment breath hydrogen was not reported; this may be clonazepam rather than the other changes. This is like van Haaps et al. (2023) noting that an endometriosis diet positively affects the quality of life. Dietary management of endometriosis is discussed in Kobayashi (2023b) and Katie Edmonds' two books at [Resources](#).

More recently, Muraoka et al. (2023) found *Fusobacterium* in 64% of patients with ovarian endometriomas and <10% of controls. Activated transforming growth factor- β signaling led to the transition from quiescent fibroblasts to myofibroblasts with the ability to proliferate, adhere, and migrate in vitro. In a mouse model, antibiotics limited endometriosis. Clinical studies are needed to determine if antibiotic treatment against *Fusobacterium* will be effective in humans. Since this involves the transition from quiescent fibroblasts to myofibroblasts, antibiotics may be effective in early endometriosis but not in established fibrotic lesions after 6 to 10 years of delay. Also, this may be bacterial overgrowth as discussed above. Until we have a non-invasive test for early endometriosis, culturing the endometrium or empirical antibiotics might be considered for persistent dysmenorrhea without a firm diagnosis. A study is needed to see if urinary PCR or a similar test can diagnose *Fusobacterium*. If so, urinary testing would be a first-line test and is more reasonable and acceptable than an endometrial culture or empirical antibiotics.

Concerns in adolescents are raised by inflammatory lesions suggestive of endometriosis in adolescents and children (Marsh and Laufer 2005, Cabana et al. 2010). These inflammatory lesions have been called a form of subtle peritonitis. It is not published if those are infectious or sterile. In either situation, endometrial or endometrioid stroma can be challenging to recognize in inflammation (Clement 2007), and the conclusion that these reactive and inflammatory are endometriosis is reasonable. However, neither Marsh and Laufer (2005) nor Cabana et al. (2010) used stromal markers such as CD10. Nor did they exclude infection, endotoxins, or other causes of inflammation (Khan 2014, Khan 2016, Canis 2017, Leonardi 2020a) as the source of the inflammation.

Kobayashi (2014, 2023a, 2023b) concluded that gut microbiome dysbiosis caused by the imbalance between the commensal and pathogenic microbiomes or reduced microbial diversity dysregulates the bidirectional crosstalk between the gut and uterus, which results in not only immune dysfunction but also altered estrogen signaling. It is not known if infection precedes or follows sterile inflammation. Koninckx et al. (2019b) found that women with endometriosis have a significantly increased risk of lower genital tract infection, chronic endometritis, severe PID, and surgical site infections after hysterectomy. Leonardi et al. (2020a) found that endometriosis appears to be associated with an increased presence of Proteobacteria, Enterobacteriaceae, *Streptococcus* spp., and *Escherichia coli* across various microbiome sites.

Although antibiotics can treat active infections and potentially decrease long-term morbidity, these have side effects. Conversely, if these are sterile inflammatory lesions or bacteria are present but part of a healthy microbiome, then antibiotics may interfere with a healthy microbiome (Power 2017). The [Tomato Effect](#) discusses problems of treatment based on theory; we need prospective data of response and risks.

Canis et al. (2017) considered “occult pelvic inflammatory disease” as a potential initiating event for endometriosis.” Cicinelli et al. (2017) concluded that chronic endometritis might facilitate the development of endometriosis. Gazvani et al. (2013) suggested that *C. albicans* may contribute to the pathogenesis of endometriosis by modulating cytokine production.

Muraoka (2023) found that myofibroblasts expressing TAGLN promote endometrial cell survival at ectopic sites. These cells are induced by TGF- β signaling, which can be activated by *Fusobacterium* infection. They speculated that targeting *Fusobacterium* in the endometrium by antibiotic treatment may be a therapeutic option for patients with endometriosis.

Kobayashi (2023) concluded that women with endometriosis are at increased risk of comorbid PID and vice versa. They found a bidirectional relationship between endometriosis and PID that shares a similar pathophysiology, which includes the distorted anatomy favorable to bacteria proliferation, hemorrhage from endometriotic lesions, alterations to the reproductive tract microbiome, and impaired immune response modulated by aberrant epigenetic processes.

There is speculation but no data to clarify if sterile inflammatory changes with bacteria are part of a healthy microbiome or if they are an infectious process. If these are sterile or bacteria are part of a healthy microbiome, then antibiotics may interfere with a healthy microbiome (Power 2017). It is not known if these are related to bacteria overgrowth-associated bowel dysfunction. Dietary changes are easy to try.

The Tomato Effect (Theory-Based Medicine)

The tomato effect in medicine occurs when an effective treatment for a specific disease is ignored or rejected because it does not make sense in the light of accepted theories of disease mechanisms and treatment of these diseases. The tomato effect can interfere with the acceptance of useful remedies.

Discussions of theory are not discussions about the effectiveness of treatment. The results of surgical or medical therapy depend on their therapeutic outcomes, not on an opinion or a theory.

Since early endometriosis can be transient or stable in many, if not most cases, observation, or symptomatic care, such as hormonal suppression can be reasonable. Superficial endometriosis can respond to observation (Evers 1994, Koninckx 1994, Harrison 2000), medication or coagulation. Deep endometriosis will more likely require excision (Malinak 1979, Semm 1980, Martin 1989b). Redwine’s (Redwine 1991) reoperation rate of 55%, with only 19% having endometriosis recognized suggested that, for some/many women, endometriosis may not be a laparoscopically recognizable disease, surgery might not be the answer, or there may be a different cause of their pain.

Sutton (1994) noted that three to six months of pain relief after surgery is non-specific and can be a placebo response. Performing a repeat laparoscopy for pain that occurred in the first six months after excision is not commonly useful long-term. For those patients, focusing on their

questions and concerns, helping them with expectations, considering hormonal suppression, encouraging physical therapy, investigating dietary changes, considering stress therapy, deciding about judicious use of narcotics, and more are more useful.

According to Goodwin & Goodwin (1984), the three issues that matter in picking a therapy are:

- Does it help?
- How toxic is it?
- How much does it cost?

Goodwin & Goodwin's three issues can be updated to include:

- Risks
- Benefits
- Costs
- Acceptability
- Availability
- Wholistic treatment
- Natural treatments
- Alternative treatments
- Other associated concerns of using a therapy.
- Insurance coverage
- Preauthorization
- In-network providers
- Out-of-network providers
- Inclusivity
- Physician qualifications

Additional questions from patients include:

- What do I have?
- How did I get it?
- What can we do about it?
- When can I go back to work?
- How do I involve integrative medicine?
- Is a multidisciplinary team available?
- What is my chance of cancer?
- How do I decrease my chance of cancer?
- What do I need to worry about after treatment?
- Do my children need to be concerned?
- Can I avoid surgery?
- Can I avoid hormones?
- How do I manage my allergies?
- How do I avoid narcotics?
- Can I have access to narcotics?

Medical Reversal of Evidence-Based Medicine

“Medical reversal” can be compared to the tomato and placebo effects. The difference is that medical reversal occurs after treatment that is initially accepted based on positive but inadequately studied information is reversed. That contrasts with the initial rejection of a treatment due to the tomato effect or acceptance due to a placebo response.

Evidence-based medicine, like theory, is dependent on the knowledge available at the time it is applied. When knowledge changes, the approach to a disease and its treatment can also change and create a new standard of care. This commonly happens when new knowledge updates and improves older but effective treatment. But, medical reversal describes when medical practices that were initially thought to be beneficial are found to be inadequate or detrimental.(Prasad 2012, Prasad 2019, Herrera-Perez 2019) The seven stages of medical reversal are: 1) promising report, 2) adoption by providers, 3) patients and payors accept the innovation, 4) insubstantial studies that superficially support the innovation, 5) randomized controlled trials, 6) denial if the trials do not support earlier observations and finally 7) acceptance.

Both changing to a new standard of care and the recognition of medical reversal can be compounded by delay. Balas (2000) studied the components of delay such as the time needed to do the research, have the research accepted for publication, and have the change accepted by the general medical community. He calculated that it takes an average of 17 years for research evidence to reach broad based, clinical practice.

For endometriosis, perhaps no medical reversal is more distressing for physicians trained in the late 1900s than that regarding the use of diethylstilbestrol (DES). DES was touted as a treatment for endometriosis in the 1940s (Karnaky 1948) but was found to cause vaginal adenosis associated vaginal cancer (Herbst 1971) as the daughters born in the late 1940s and 50s matured. Other significant problems in the daughters of DES exposed mothers include endometriosis, infertility, miscarriage, preterm delivery, loss of second-trimester pregnancy, ectopic pregnancy if pregnant, stillbirth, early menopause, grade 2 or higher cervical precancerous changes, and breast cancer at 40 years of age or older. For most outcomes, the risks among exposed women were higher for those with vaginal epithelial changes than for those without such changes (Senekjian 1988, Wilson 2011, Upson 2015, Ottolina 2020). Medical reversal, in addition to the tomato effect, can have serious consequences.

Annotated References (chronological)

1. Kahun Medical Papyrus 1825 BC vs. 1855 BC – This hieroglyphic Egyptian text is discussed in [Redwine 2012](#) and [Nezhat 2012](#) as the oldest known medical text. Symptomatology such as pelvic pain is discussed but is not sufficiently specific to determine if the pelvic symptoms were those of endometriosis. Hippocrates' (400 BC) notation that “a part of the vagina hardens” may be the first description of endometriotic nodules. Johnstone (1777) described an isolated rectal stricture, Rutter (1808) added the scirrhus characteristic, and Seymour (1830) noted a rectovaginal location. Chocolate cysts with iron noted on chemical analysis and probable endometriomas or hemorrhagic corpus lutea (see Martin 1990b) were reported by Lobstein (1820). Also, see Hippocrates (466 – 377 BC) and Knapp 1999.

Redwine DB. Googling Endometriosis - The Lost Centuries.

https://drive.google.com/file/d/1UIBmdgddjD5eO-1TxW0mpky_vT97f2U2/view?usp=sharing

Nezhat C, et al. Endometriosis: ancient disease, ancient treatments.

[https://www.fertstert.org/article/S0015-0282\(12\)01955-3/fulltext](https://www.fertstert.org/article/S0015-0282(12)01955-3/fulltext)

2. Hippocrates's (466 – 377 BC) – From [Whiteley 2003](#) and quoted in [Redwine 2012](#) - Hippocrates's theories were based purely on observation and experience. His observation “when, in a woman who has not given birth, the menses stay away or are not able to find a way out, disease occurs, and this happens—either the mouth of the womb closes, or it doubles back upon itself, or a part of the vagina hardens” may be the first description of nodules. Kathleen Whiteley Ph.D. thesis (2003) <http://uir.unisa.ac.za/handle/10500/1620>
3. Shroen 1690 – Shroen is referenced in Knapp 1999 and Nezhat 2012 as describing “ulcers” associated with “a flow of blood” “outside the sphere of the uterus” that Knapp concluded were endometriosis. (Knapp 1999, Nezhat 2012) The symptoms Shroen described were more of pain than fever and are compatible with endometriosis. Shroen's “ulcers” were a female disorder, characteristic of those who are sexually maturing. The lesions were in the bladder, intestines, broad ligament, and outside of the uterus and the cervix. They were inflammatory and tended to form adhesions that linked organs together. They expanded in size, were vacuolated, and were susceptible to hemorrhaging. Histologic description was in its infancy in the 17th century and is not in the paper. If the term “ulcers” in the seventeenth century can mean the same as the current concept of “lesions,” then this was likely endometriosis. See Knapp 1999 for Shroen and 18th century reference. Discussions are in Knapp 1999, Batt 2000, Brosens 2000, and Batt 2011a, and Nezhat 2012.
4. Ruysch 1691 – Frederik Ruysch is discussed by Nezhat (2012) as advancing reflux (retrograde) theory in cases with congenital malformations and blood refluxed from the fallopian tubes into the peritoneum.
5. von Reitzenstein c1769 – Leopoldine von Reitzenstein, the Countess of Reitzenstein, had coexistent malignancy and ovarian pathology supporting the diagnosis of an endometriotic ovarian cyst. Reported in van der Weiden 2020.
6. Müller 1830 – Johannes Peter Müller published his treatise on the embryology of vertebrate genitalia, entitled *Bildungsgeschichte der Genitalien aus anatomischen Untersuchungen an Embryonen des Menschen und der Thiere*. Müller elevated the developmental anatomy and pathology of the Müllerian organs (upper vagina, uterus, and tubes) to a prominent scientific level. Müllerianosis is Ron Batt's theory of four congenital Müllerian diseases

(endometriosis, adenomyosis, endosalpingiosis, and endocervicosis) and four corresponding acquired Müllerian diseases. Müllerian defects (pockets) are also associated with endometriosis. See Batt 1985, Redwine 1988b, Batt 2011b (*Intellectual Development of Carl Von Rokitansky*), Marsh & Laufer 2005, Batt 2013, Batt 2015, Batt 2015, Song 2020, and Martin 2021.

7. Cruveilhier 1835 – Cruveilhier published a gross description of “the existence of cysts of the adnexa, uterus, and vagina, forming along the course of the Wolffian (mesonephric) and Müllerian paramesonephric remnants. Although lacking accurate descriptions, both gross and microscopic, it is plausible to think that such "cysts" were probably of an endometrial nature.” Quoted in Breus 1894, Ridley 1968, Batt 2011a, Redwine 2016.
8. Rokitansky 1860 – Rokitansky published the first accurate description of the histology of what we now call endometriosis and adenomyosis in addition to endometrial polyps, intracavitary myomas, and either a papillary serous cystadenofibroma with psammoma bodies or an ovarian malignancy in a malnourished 68-year-old. In the time of Rokitansky and Virchow, almost every connective tissue proliferation, whether neoplastic or reactive, with or without epithelial component was also referred to as "sarcoma." Interpretations are by Dr. Franz Glasauer, Prim. Dr. Günter Alpi, Prof. Dr. Jörg Keckstein, and Dr. Ken Groshart.
9. Waldeyer 1870 – Waldeyer concluded that epithelial ovarian cysts were from metaplasia (metamorphosis) developing in nests of cells in the germinal epithelium of an ovary. This might be the first recognition of a progenitor cell for epithelial cells. The germinal epithelium of an ovary had also been considered as the precursor to eggs. See Iwanoff 1898, Levander 1955, and Merrill 1966 for coelomic metaplasia. See Lauchlan 1972 for metaplasia from a secondary Müllerian system. See Zamecnik 2013 for case report of metaplasia in men. See Que 2019 for recent concepts of metaplasia, paligenosis, differentiation, transdifferentiation and transcommitment.
10. Marchand 1879 – Marchand’s theory of the extension of tubal epithelium is quoted in Russell 1899. Marchand believed that the epithelium of the tube could extend out over the surface of the ovary, and by penetrating the stroma of the ovary produce tubules like Pflüger ducts. From these, he argued, cysts might arise with a histological resemblance between the mucous membrane of the tube and papillary tumors of the ovary.
11. Cullen 1896, Kossmann 1897, Russell 1899, Longo 1979, Koninckx 1992, Batt 2007, Acién 2012, Batt 2003, Batt 2008, Batt 2013, Signorile 2009, Signorile 2010, Signorile 2012, Laganà 2017 – Müllerianosis is seen as a remnant or fragment of Müllerian tissue in or near the area of embryologic Müllerian development. See Nerune 2016 for persistent Müllerian ducts in men and Rei 2018 for endometriosis in men.
12. Von Recklinghausen 1896 (discussed by Cullen in 1896 and Casler 1919) – The Wolffian theory proposes that adenoma (later called endometriosis) results from intermingling when the Wolffian and Müllerian ducts cross in fetal development.
13. Ries 1897, Sampson 1922, Halban 1924, Jerman 2015, Jerman 2020 – Theory of the lymphatic spread (metastasis) of the endometrium.
14. Iwanoff 1898, Meyer 1903, Lockyer 1918a, Sampson 1921, Suginami 1991, Matsuura 1999 – Coelomic metaplasia of ovarian serosa may be the same concept as Waldeyer’s metaplasia from the germinal epithelium. See Zamecnik 2013 and Rei 2018 for metaplasia in men. See

Que 2019 for recent concepts of metaplasia, paligenosis, differentiation, transdifferentiation and transcommitment.

15. Russell 1899 – Clinically unrecognized, intraovarian endometriosis was discovered within an ovary and beneath adhesions. He also discusses theories including remnants of the germinal epithelium, extension of tubal epithelium, a Wolffian body, and a Müller’s Duct remnant. See Waldeyer 1870 for germinal epithelium theory, Marchand 1879 for extension of tubal epithelium theory. Non-visualized endometriosis was recognized on aspiration of endometriotic bloody fluid; those were rASRM 0-0 before and rASRM I to III after aspiration. (Candiani 1990) Also see Sampson 1921 and Griffiths 2007 for endometriosis behind adhesions or scar. Areas where endometrium is visually missed include the retroperitoneum (cervix, rectum, ureter, lymphatics including nodes, nerves) (Taussig 1906, Sampson 1926, Javert 1949, Moore 1988, Nezhat 1991, Koninckx 1993, Koninckx 1996, Griffiths 2007, Possover 2007, Possover 2015, Griffiths 2007, Rossini 2016, Law 2020, Possover 2021), adhesions and scar (Russell 1899, Sampson 1921, Griffiths 2007), large and small bowel (Martin 1990c, Kavallaris 2003, Badescu 2016, Rossini 2016, Badescu 2018, Roman 2021), appendix (Martin 1990a, 1990c), epiploic fat (Martin 1989b), mesentery (Martin 1995), cryptic pockets (Martin 1992, Stuparich 2019), ovaries (Russell 1899, Longo 1979, Candiani 1990), tubes (Yamamoto 1997, McGuinness 2020), and omentum (Zinsser 1982). Reviewed in Longo 1979.
16. Füh 1903 – A retrouterine, recto-uterine endometriotic mass, incorrectly labeled as being in the recto-vaginal septum, is illustrated in Lockyer 1918a, page335.
17. Taussig 1906 – Taussig reported twenty-six pelvic lymph-node dissections for cervical carcinoma and found endometriotic tissue in one lymph node. From Javert 1949. See Sampson 1926, Javert 1949, Noël 2008, Rossini 2016, and Lenz 2020.
18. Clark 1908 (quoted in Kelly 1931) – Clark developed useful electrosurgery.
19. Stevens 1910 – Isolated small vaginal wall nodules with characters of diffuse adenomyoma of the uterus. Stevens contended that a Wolffian origin was more than likely for the small adenomyoma than Müllerian origin.
20. Klages 1912, Hueter 1918, Lockyer 1918a, Meyer 1919, Meyer 1924, Redwine 1988b, Alifano 2006 – Inflammatory induction (initiation or activation) of coelomic metaplasia of mesoderm or “endothelium” may include both peritoneum and pleura. Lockyer (1918a) quotes Klages (1912) as discussing the earlier work on metaplasia with illustrations of the transition from flat to cylindrical peritoneum by Opitz and Meyer with no citations listed. See Que 2019 for recent concepts of metaplasia, paligenosis, differentiation, transdifferentiation and transcommitment. See Nap 2004a, Levander 1955, and Merrill 1966 on inductive theory of exfoliated endometrial cells entering the peritoneal cavity and stimulating its epithelium to transform into endometrial tissue.
21. Lockyer 1913, Cullen 1914, Stevens 1916 – Rectovaginal lesion with fibrous and muscular components like adenomyoma that are compatible with what would later be called rectovaginal endometriosis. They concluded these were in the rectouterine (Lockyer) and rectovaginal (Lockyer, Cullen, Stevens) septum. Lockyer, Cullen, and Stevens’ findings were in the normal area of the rectovaginal pouch, not the normal area of the septum. Lockyer supported Wolffian remnants theory. See Martin 2001 and Batt 2014 for normal location of the rectovaginal pouch and rectovaginal septum.

22. Stevens 1916 – Adenomyomatous growths arise in the uterus and invade the rectum, sigmoid, and other parts. These may have an endometrial, Müllerian duct, Wolffian remnants or peritoneal endothelium origin.
23. Sampson 1918, Sampson 1927b, Yovich 2020 – Discusses venous dissemination (metastasis) of intrauterine contents. See Sampson 1927b for endometrial dissemination and Yovich 2020 for review of Sampson 1927b with Sampson’s illustrations. See Bobek 2014, Chen 2017, and Pospisilova 2019 for circulating endometrial cells as an endometriosis marker and Vallvé-Juanico 2019 for circulating stromal cells. See Samani 2017 for endometriosis-derived cells migrating to extrapelvic organs including the lung, spleen, liver, and brain in a mouse model. See Kiss 2020 for spontaneous pneumothorax and circulating endometrial cells.
24. Lockyer 1918b – This first classification was of the anatomic location of adenomyomas that were later called endometriosis.
25. Casler 1919 – Report of cyclic bleeding from ovarian adenoma (later called endometriosis) through a vaginal fistula after hysterectomy. Casler referred to this as a “*menstruating ovary*” Casler also discusses Von Recklinghausen’s Wolffian theory of intermingling when the Wolffian and Müllerian systems cross in fetal development. Discussed in Batt 2011.
26. Sampson 1921a, Sampson 1921b – Discusses peritoneal implantation from internally menstruating ovaries, differences between native endometrium and “adenomas of endometrial type” both “*in structure and function,*” and adenomyosis as different than adenomyoma. The term “adenomas of endometrial type” preceded his use of the term endometriosis. Recognition could be difficult and “*the variation in size of the cysts, with the varying extent and denseness of the adhesions, leads to mistakes in diagnosis both before and during the operation.*” Diagnosis requires careful study of “*the tissue involved in the adhesions.*” Adhesions between the rectum and uterus had adenoma of the endometrial type in 72% of cases. The 1921a Archives of Surgery version is duplicated and expanded with meeting discussion in the 1921b Transactions of the American Gynecological Society version. The discussion includes Sampson’s first mention of his retrograde theory. Also see Shroen 1690 and Ruysch 1691 for reflux (retrograde) discussed in Nezhat 2012.
27. Sampson 1921b, Sampson 1926, Sampson 1927a, Nap 2004a, Nap 2004b, Nap 2012 – Sampson suggested retrograde menstrual and as “a,” not “the” source of endometriosis. He also considered congenital rests. “*Two possible sources of the origin of these small tubules or cysts of endometrial type in the ovary present themselves: first, congenital, and second, acquired from the implantation of epithelium escaping from the tube during menstruation and its subsequent invasion of the ovary.*”
 He also discussed endometriosis within the adhesions of hemorrhagic cysts, invasion (implantation). vascular dissemination, lymphatic dissemination, transplantation, differentiation of celomic epithelium, direct extension from perforating ovaries, tubal epithelium as the origin, metaplasia of peritoneal epithelium due to the stimulus of menstrual blood from perforating ovaries, metaplasia of the mesothelial lining of the processus vaginalis peritonei or of the endothelial lining of vessels, extraperitoneal endometriosis remnants from Wolffian bodies, developmentally misplaced endometrial (Müllerian) tissue, and why endometriosis was a better designation than Müllerianosis. In 1921b, Sampson introduced, in the Transactions of the American Gynecological Society, the *possibility of “implantation of epithelium escaping from the tube during menstruation and its subsequent invasion of the ovary.”* Joseph V. Meigs (1922) heard a subsequent presentation at Peter Bent

Brigham Hospital, Boston, on February 14, 1922, and discussed Sampson's theory that ovarian "hematomas" are "*due to the implantation of endometrium reaching the ovary by way of the Fallopian tube.*" In 1927a, Sampson expanded this theory and added the transition from endometrium to endometriosis and the inflammatory reaction of early implantation to his 1921 observation that endometriosis was different "*both in structure and in function.*"

Retrograde menstruation theory can be expanded with current knowledge to include:

- Endometriosis differs from endometrium "*in structure and function.*" Histologically normal endometrium and endometriosis can coexist, and a transition can be seen. See Karnaky 1969 regarding animal research and Koninckx 2018 for the transition from endometrium to endometriosis. Also see Evers 1994, Koninckx 1994, Koninckx 1999, Harrison 2000, Nap 2004a, Wang 2020, and Masuda 2021., Nezhat 2012 discussed reflux (retrograde) introduced by Shroen 1690 and Ruysch 1691.
- The cell of origin - Endometrial fragments (DNA, mRNA, other) or cells
- Dissemination - Retrograde menstruation of tissue fragments or cells
- Peritoneal dispersion of cellular or sub-cellular components. See Levander 1955, Merrill 1966, Lauchlan 1972, and Thomas 1996.
- Attachment. See Young 2013 for differential expression of peritoneal mesothelial adhesion factors.
- Inflammation
- Infiltration
- Growth
 - o Inflammatory reaction
 - o Fibrosis
 - o Muscular metaplasia
 - o Entrapment

Theories of dispersion (retrograde menstruation, lymphatic, hematogenous, traumatic, surgical), congenital Müllerian remnants, secondary Müllerian system, and metaplasia have been expanded to include the role of stem cells, replacement of endometrial cells by endometriotic cells, differentiation of stem cells into endometriotic cells, differentiation of stem cells into endometrial cells, and other concerns reviewed in the references that follow. See Wang 2020 for retrograde menstruation model.

28. Sampson 1922 – Recognition increases with experience.
29. Meyer 1923, Meyer 1924, Gruenwald 1942, Marsh & Laufer 2005, Alifano 2006, Zamecnik 2013, Gruber-Dujardin 2017, Rei 2018 – Coelomic metaplasia of mesothelial cells from the peritoneum or pleura.
30. Sampson 1924 – There are multiple appearances including red raspberries, purple raspberries, blueberries raspberries, hemorrhagic blebs, and clear blebs. Invading lesions are older than superficial lesions. See age related changes in Karnaky 1969, Redwine 1987, Davis 1988, Koninckx 1991
31. Sampson 1925 – Discusses endometriosis phenotypes, endometrial (Müllerian) tissue derived from the uterine or tubal mucosa, pseudo-endometrial tissue which arises from remnants of

the Wolffian body, metaplasia of the peritoneal serosa, transplantation, and distant metastasis. He concludes that endometriosis is a Müllerian derivative. This may be the first mention of “endometriosis.” See Sampson 1921 for “endometrial type” tissue.

32. Jacobson 1925 – Experimental induction (initiation or activation) of endometriosis by intraperitoneal autotransplantation of endometrium during oestrus was successful in sixteen (84%) of 19 rabbits. There is an early discussion of “Sampson’s syndrome” and “endometriosis.” He rejected metaplasia of mesothelium. Jacobson was Sampson’s pathologist.
33. AGS Society Transactions 1925 – The American Gynecological Society held a “Symposium on Misplaced Endometrial Tissue” in Washington, DC, May 4,5, and 6, 1925. Drs. Ewing and Sampson used the term “endometriosis” while Drs. Cullen, Brady, Graves, Danforth, and Heaney used the term “adenomyoma.” Dr. Keene discussed Sampson’s “perforating ovarian cysts” and Dr. DeWitt Casler (1919) discussed his menstruating ovarian “chocolate cyst containing about a dozen typical uterine polypi” as a “a tumor of Müllerian origin.”
34. Sampson 1926 – Sampson found endometriosis “in the venous sinuses and possibly the lymphatics of the uterine wall.” See Ries 1897, Taussig 1906, Javert 1949, Noël 2008, Rossini 2016, and Lenz 2020 for lymph nodes.
35. Sampson 1927a – See Sampson 1921b for discussion of his several theories and the development of his landmark retrograde menstruation theory paper (1927a).
“The implantation theory does not account for all instances of ectopic endometrium-like tissue in the pelvis.”
Lesions include both “*typical endometrium with glands and stroma identical with that of the Müllerian mucosa from which it came, and also dilated glands or cyst-like cavities lined by epithelium with very little or no characteristic endometrial stroma about it.*”
36. Sampson 1927b – Discusses use of extirpated uterine specimens to develop the data for his 1918 article and how that expanded into this study demonstrating the vascular dissemination of endometrial tissue. See Yovich 2020 for review with Sampson’s 1927b illustrations. See Vallvé-Juanico 2019 for circulating stromal cells.
37. Hunter 1927 – Early research on grafting of endometrial fragments.
38. Weller 1927 – Early report of umbilical endometriosis.
39. Ferguson 1929, Nora 1956, Steck 1965, Kaunotz 1979, Rock 1981, Donnez 1984 – Direct implantation of endometrium or endometriosis in surgical scars, drain sites, amniocentesis needle tract or traumatic vaginal tears may be from denuded surface, trauma, or inflammation.
40. Novak 1931 – Metaplasia due to hormonal stimulation. See Que 2019 for recent concepts of metaplasia, paligenosis, differentiation, transdifferentiation and transcommitment.
41. Watkins 1937, Watkins 1938 – Watkins documented endometrial cells in peritoneal fluid during menstruation. Discussed in Blumenkrantz 1981. Also See Koninckx 1980, Dmowski 1981, Halme 1984, Halme 1988, and Dorien 2017.
42. Sampson 1940 – Discusses the details needed for research including attention paid to small implants, sketches, selection of sections to be submitted, supervision of technicians, and giving cutting instructions. Noted that endometriosis can remain small and superficial. See

Goldstein 1980 on close-up view, Redwine 1988a on near-contact laparoscopy, and Martin 2006 on STARD.

43. Geist 1941 (reviewed in Brosens 2011) – Geist advocated the use of androgens in gynecological disorders. Brosens (2011) is a free download at <https://www.ncbi.nlm.nih.gov/pmc/articles/PMC3135985/>
44. Karnaky 1948, Karnaky 1969 – Karnaky proposed the use of the synthetic estrogen diethylstilbestrol (DES) to produce amenorrhea and suppress endometriosis. See section on [Reversal in Evidence-Based Medicine](#). See Upson 2015 and Ottolina 2020 for increase in endometriosis with in-utero DES exposure.
45. Fallon 1946 – 13 to 19-year-old with endometriosis. See Clark 1948 for 11 years old, Marsh 2005 for 8.5 to 15 years old, and Ebert 2009 for 8.5 years old.
46. Clark 1948 – 11-year-old with endometriosis.
47. Javert 1949 – Four of five cases with endometriosis in lymph nodes had recognized pelvic endometriosis. See Taussig 1906, Sampson 1926, Noël 2008, Rossini 2016, and Lenz 2020.
48. Fallon 1950 – Endometriosis can be colorless and amenorrheic. See Karnaky 1969.
49. Scott & Te Linde 1950 – Early discussion of excision and fulguration (ablation).
50. Te Linde 1950 - The viability of excised endometrium was demonstrated using autogenous transplantation in monkeys. Keettel (1951) subsequently demonstrated viability of cast-off menstrual endometrium. By 2021, Marinaro concentrated on mesenchymal stromal cell viability.
51. Noyes 1950 (reprint 2019) – Endometrial leukocytic infiltration begins on day 24 of the cycle and continues through day 5. See da Silva 2014 for inflammation and angiogenesis markers in the menstrual blood. See Khan 2010 Khan 2016, and Koninckx 2019b for Escherichia coli bacterial endotoxins in menstrual blood. See Merrill 1966 for “Merrill factor,” a metaplasia-inducing substance such as estrogen and a factor liberated from degenerating menstrual endometrium.
52. Keettel 1951 – Keettel demonstrated viability of cast-off menstrual endometrium. See Te Linde 1950 for excised endometrium and Marinaro 2021 for menstrual blood-derived mesenchymal stromal cells.
53. Scott 1953, Evers 1994, Koninckx 1994, Evers 1999, Koninckx 1999, Harrison 2000, Nap 2004a, Fedele 2004b, Koninckx 2018 – Endometriosis in its superficial form may be physiologic, generally transient, self-limiting, and cause little or no long-term damage. This has been called the “Pimple Model” (Martin 2005) as almost everyone has pimples, most are mild and resolve spontaneously, some cause pain, some do not, pimples hidden behind the skin can cause pain, ugly pimples did not always cause pain, some respond to hormonal therapy (estrogens), some respond to anti-inflammatory medication (tetracycline) some get worse, some come and go (Hoshiai 1993 and Martin 1999), some cause significant scarring, some require dermabrasion (surgery), and some are chronic and nonresponsive. In contrast, Evers 1994 concluded the native endometrial explants in the peritoneal cavity are a physiological finding in all menstruating women and that, as such, they do not constitute a disease in its proper sense. That conclusion might be extended to asymptomatic deep endometriosis with 93% showing no clinical or imaging changes over 1 to 9 years. (Fedele 2004b)

Scott (1953) was the first to propose that if serial sections of all pelvic tissue were feasible, all women might have endometriosis. Evers (1999) calculated that if >16 blind biopsies were taken, then Nisolle et al. (1990) would have found endometriosis in all women. Koninckx's endometriotic disease theory (1994, 1999) of the transition of some early, transient, subtle endometriosis to late, deep infiltrating and ovarian endometriomas evolved into the genetic/epigenetic theory (Koninckx 2018). See Dmowski 1981, Halme 1988, Vinatier 1996, and others for immune competence and immune overload models that explain why both transient and progressive may be common pathway. See Sampson 1921 and 1927a for transition from endometrium to endometriosis. See Giudice 2004 for intrauterine precursors. See Deans 2015 for clarification of definitions of "epigenetics." See Simon 2015 and Brenhouse 2016 for neuroimmune maturation. See Zondervan 2018 and Zondervan 2020 for inadequacy of the definition of "endometrium-like tissue outside the uterus." This may be related to the 5.7% of women with coincidental endometriosis in 15 studies reviewed by Fuentes et al (2014).

54. Meigs 1953 – Meigs recommended early and frequent childbearing as prophylaxis.
55. Scott 1954 – Scott & TeLinde proposed the order of viability to be:
 1. Postmenstrual endometrium.
 2. Interval endometrium
 3. Secretory endometrium
 4. Premenstrual endometrium
 5. Menstruating endometrium
 6. Endometrium associated with early pregnancy
 7. Endometrium associated with late pregnancy.
56. Brews 1954 – Brews reported a woman with ascites and right pleural effusion with diffuse abdominal and diaphragmatic with a small communication through the right side of the diaphragm between the peritoneal and right pleural cavities. See Suginami 1991 for cribriform fenestrations and Maniglio 2018 for perforations.
57. Levander 1955, Merrill 1966, Lauchlan 1972, Thomas 1996 – Induction (initiation or activation) of endometriosis due to activation of mesenchymal cell metaplasia by products degenerating endometrium that arrives in the pelvis. These have been called "Merrill factors" and "Levander substances." See Que 2019 for recent concepts of metaplasia, paligenosis, differentiation, transdifferentiation and transcommitment.
58. Fallas 1956 – Cervical and upper vaginal agenesis anomaly associated with retrograde menstruation and severe endometriosis. See Song 2020.
59. Kistner 1958 – Kistner proposed a state of "pseudopregnancy" to reproduce the improvement noted in endometriosis during and after pregnancy. He postulated that decidualization results in necrosis and elimination of superficial endometriotic implants. Also, see Klemmt 2006 & Aoyagi 2017.
60. Ridley 1958 & 1961 – Menstrual endometrium was implanted in the abdominal wall laparotomy sites in 15 women. Abdominal wall endometriosis was induced in two of the 15 with gross and microscopic glands and stroma compatible with endometriosis at the sites of implantation. An additional four had scarring, hemosiderin-laden macrophages, and an occasional small gland acinus with an atypical epithelium compatible with endometriosis or tissue reaction to the material that had been injected. See Ridley 1968.

61. Freidman 1959 – Müllerian epithelium was noted in an exophytic bladder in a male. This AFIP slide was reported in Olikier 1971.
62. Ridley 1968 –Eleven theories: implantation (Sampson retrograde), mechanical transplantation theory, theory of benign metastasis (lymphatics), celomic metaplasia, hormonal stimulation, histogenesis by induction phenomenon, embryonic cell rests, direct extension, mesonephric (Wolffian) cell rests, uterotubal (salpingitis isthmica nodosa), composite. See Ridley 1958 & 1961.
63. Kantor 1963 – Endometriosis due to retrograde menstruation may be a different disease than endometriosis due to embryonal rests. Two phenotypic disease theory.
64. Merrill 1966 – “Merrill factor” (quoted in Suginami 1991) is a metaplasia-inducing substance such as estrogen and a factor liberated from degenerating menstrual endometrium. These have also been called “Levander substances.” Also see Levander 1955, Lauchlan 1972, and Thomas 1996 for induction (initiation or activation) of endometriosis due to activation of mesenchymal cell metaplasia by products degenerating endometrium that arrives in the pelvis. See Que 2019 for recent concepts of metaplasia, paligenosis, differentiation, transdifferentiation and transcommitment.
65. Melicow 1967 – First report of prostatic endometrioid cancer in a male. See Olikier 1971 for the first report on endometriosis.
66. Karnaky 1969, Redwine 1987, Davis 1988, Koninckx 1991 – There is a 4 to 20-year progression from an initial water blister lesion (clear papule) to red to hemorrhage to scar to scar with blue dome cysts (black only appearance) to deep infiltrating endometriosis. Diagnosed endometriosis in the absence of hemosiderin. See Sampson 1924.
67. Karnaky 1969 – Endometrium and endometriosis respond differently to antiestrogen therapy. He further notes that the differences in humans were not seen in monkeys and questions if monkey research might be on transplanted, native endometrium and not endometriosis. He felt this supported the theory of coelomic metaplasia. See Que 2019 for recent concepts of metaplasia, paligenosis, differentiation, transdifferentiation and transcommitment.
68. Karnaky 1969, Jansen 1986, Redwine 1987, Stripling 1988a, Stripling 1988b, Davis 1988, Martin 1989a, Koninckx 1991, Albee 2008 – Any abnormality of the pelvic peritoneum, irrespective of size, the ease of visualization, the subtleness, the color, or the age of the patient may be endometriosis.
69. Olikier 1971 – This is the first report of endometriosis in a 46 XY male. See Friedman 1959 for Müllerian epithelium, Melicow 1967 for prostatic endometrioid cancer, and Nerune 2016 for male pseudohermaphroditism. Seventeen reports of endometriosis or endometrioid cancer were summarized in Rei 2018. Most were older and on estrogen therapy.
70. Lauchlan 1972 – Differentiation of precursor tissue in a secondary Müllerian system may be responsible for endometriosis outside the normal Müllerian developmental area. He felt that pelvic endometriosis was most compatible with retrograde while distal, non-abdominal sites might be hematogenous dissemination or metaplasia. He also noted that endometriosis is histologically different from endometrium with a mixture of cell types. See Cullen 1914 for fibrous and muscular components. (*Author’s Note: Many peritoneal endometriotic lesions are outside the normal Müllerian area including ileum, appendix, cecum, lateral gutters, and diaphragm.*) See Que 2019 for recent concepts of metaplasia, paligenosis, differentiation, transdifferentiation and transcommitment. See Levander 1955 and Merrill 1966 for other

menstrual substances that might serve as precursor substances or initiators for peritoneal metaplasia. Those might include intrauterine tissue injury and repair, inflammatory factors such as cytokines, microRNA-mediated signal transduction pathways for context-dependent gene expression, and Wnt signaling. See Thomas 1996.

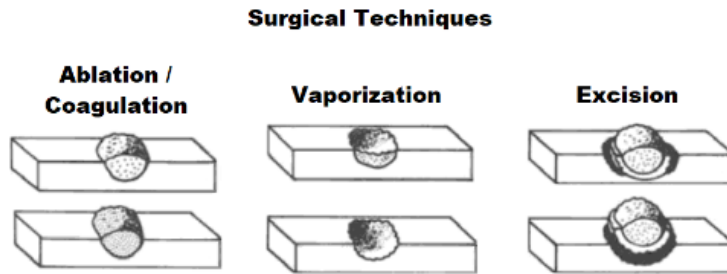
71. Schifrin 1973 – Reported endometriosis in 15 teenagers. See Fallon 1946 for 13 to 19 years old, Clark 1948 for 11 years old, and Marsh 2005 for 8.5 to 15 years old.
72. Kistner 1975 – Surgery improves pregnancy rates. *“Early implantations on the surface of the peritoneum should be excised. Electrocoagulation is not recommended because of the possibility of subsequent adhesions to the small intestine or the adnexal structures.”*
73. Cohen 1975 – Early report of biopsy and cautery.
74. Dmowski 1975 – The principle of medical treatment of endometriosis is based on arrest of proliferation, followed by involution, and resulting atrophy of the ectopic endometrium. See Dmowski 1981 for cellular immunity.
75. Williams 1977 – Endometriosis was found retrospectively in 6% and prospectively in 50% of patients. See Roman 2021 for nonvisualized but palpable bowel endometriosis prospectively missed at laparoscopy. See Ferrero 2010 for 38% suspected on unfocused histories but 62% based on four pain symptoms: pelvic or uterine pain during menstruation, genital pain on deep penetration, pelvic pain for more than six months, and painful bowel movements.
76. Malinak 1979 – Large implants require excision at laparotomy. Small lesions with no nodules or infiltration can be fulgurated (coagulated). Recurrence rates were 12% to 40%.
77. Mettler 1979 – Reported on ovarian cyst resection but concluded that more than *“coagulation of endometriotic foci cannot be performed via the laparoscope.”* See Semm 1980 for initial report on excision. Semm was Mettler’s chairman at the University of Kiel in Germany.
78. Goldstein 1980 – Endometriosis in adolescents as young as 10.5 years old with petechial lesions. Karnaky 1969 discussed young girls and Schifrin 1973 discussed teenagers. Marsh 2005 and Ebert 2009 reported as young as 8.5 years old.
79. Goldstein 1980, Redwine 1988a – A “close-up” or “near-contact” view is better for recognizing subtle, atypical, consisting of petechial-like areas, appearances of endometriosis. Redwine’s (1988a) “near-contact” is more descriptive of the technique.
80. Simpson 1980, 2003 – Genetic predisposition and heritable aspects of endometriosis are generally seen as observations, not theory. This risk indicates that polygenic and multifactorial etiology is far more likely to be the cause than Mendelian inheritance. This conclusion parallels the genetic basis of most adult-onset conditions, including many in reproductive medicine (e.g., polycystic ovarian disease, leiomyomata, endometrioid or serous ovarian epithelial cancer).
Endometriosis was seen in
 - 8.1% of mothers
 - 0.9% of husband’s mothers
 - 5.8% of sisters
 - 1.0% of husband’s sistersCompare with Moen 1993

81. Semm 1980 – The depth of coagulation is not adequate for large nodules, and laparoscopic partial excision needs to precede coagulation for those. See Malinak 1979 for laparotomy. See Semm 1980, 1981, 1984, 1987.
82. Koninckx 1980 – After ovulation, peritoneal fluid contains concentrations of progesterone and of 17 β -estradiol that are 5 to 20 times higher than plasma concentrations in women with ovulatory cycles but not in women with unruptured luteinized follicles. Since viable endometrial cells were found in the peritoneal fluid of over 50% of women, both with and without endometriosis, pelvic endometriosis could be the consequence of infertility caused by an unruptured luteinized follicle. Cells were likely from retrograde menstruation as they occurred with and without endometriosis. See Dmowski 1981, Halme 1983 & Halme 1984 for hormonal or immunologic factors and Dorien 2017 for update.
83. Semm 1981 – Professor Semm presented partial excisional techniques at the 10th Annual AAGL meeting in Phoenix, Arizona circa Nov 7, 1981. See Semm 1980 for slide set with the technique, Semm 1980, Semm 1984, Semm 1987, and Martin 1985, 1986, 1987, 1988a, & 1989 for ongoing development of excision.
84. Dmowski 1981 – Dmowski proposed that the immune system was involved in the development of endometriosis and that endometrial cells translocated from their normal location may implant only in women with specific alteration in cell-mediated immunity. See Koninckx 1980, Badawy 1983, Halme 1983, Halme 1984, Halme 1988, and Dorien 2017. See Simon 2015 and Brenhouse 2016 for neuroimmune maturation.
85. Blumenkrantz 1981 – Blood in the peritoneal dialysis catheter just before menstruation was regularly observed in 9 of 11 premenopausal women maintained on peritoneal dialysis for end-stage renal failure. Peritoneal bleeding at other times during the menstrual cycle was not seen in any of these patients. Likewise, peritoneal bleeding in men or nonmenstruating women on chronic peritoneal dialysis was exceedingly rare, was not periodic, and usually was due to recognizable causes. These observations suggest that retrograde menstrual bleeding into the peritoneal cavity is the rule rather than the exception in women on peritoneal dialysis and possibly in all menstruating women. See Watkins 1937, Watkins 1938, Koninckx 1980, Dmowski 1981, Halme 1984, Halme 1988, Dorien 2017, and Masuda 2021.
86. Rock 1981, Donnez 1984 – There is an increased risk of tubal endometriosis, especially after coagulation. Tubal surgery may be the surface disruption, traumatic or inflammatory event that facilitated the growth of endometriosis. See Munrós 2017, Long 2018, Hu & Taylor 2019, Munrós 2019, Guo and Martin 2019.
87. Daniell 1982, Daniell 1984, Tadir 1984, Martin 1985, Martin 1987 – The development of CO₂ laser vaporization for endometriosis began with vaporization and progressed to excision. Vaporization continued until healthy tissue was seen. High power density vaporization was needed to avoid carbonization, excess plume, and distortion at the base of a crater. Building on Semm's (1980) techniques, excision was found to be easier for excision than vaporization for deep lesions. See Martin 1985 for development of CO₂ laser excision.
88. Zinsser 1982 – Sixteen of 27 patients' omental specimens in 27 women had endosalpingiosis and two had endometriosis. All with endosalpingiosis had inflammatory tubal disease. None of 37 male specimens had either.

89. Halme 1983, Canis 2017 – Halme noted an increased activation of pelvic macrophages in infertile women with mild endometriosis. See Hogg 2020 review.
90. Badawy 1983 – Macrophages and lymphocytes were the dominant cells in peritoneal fluid of women. These cells were significantly increased in endometriosis patients, as compared with control subjects. In addition, peritoneal fluid acid phosphatase, PGF2 alpha and PGE2, and complement components C3c and C4 were significantly increased in patients with endometriosis. These cellular changes and their activation in peritoneal fluid may explain infertility associated with endometriosis.
91. Wheeler 1983 –Recurrence was at up to 9 years with an average of 35 months in women with no pregnancy, 44-47 months after one pregnancy, and 67 months after two pregnancies. Recurrence may have been higher as asymptomatic patient were not laparoscoped.
92. Hollis 1984 – Post-resection palpation is needed to confirm that palpable nodules have been removed. These can be too deep for visualization. Hollis’s three steps for nodules or focal tenderness on office exam:
- 1) Palpation on exam under anesthesia (EUA) for localization,
 - 2) Use a finger or probe to push the nodule up for better recognition/visualization and excision when needed.
 - 3) After excision, repeat palpation to confirm that the nodule was removed.
- Continue excision if the nodule is still present and then repeat palpation.
See Martin 1986a, 1989b, and 1990 for use and Martin 1988a for acknowledgment.
93. Halme 1984, Halme 1988– Halme noted that retrograde menstruation was more common than endometriosis. Therefore, other factors, either hormonal or immunologic, influence the development of endometriosis. See Koninckx 1980 for peritoneal fluid endometrial cells and Dmowski 1981 and Vinatier 1996 for the role of the immune system. See Dorien 2017 and Masuda 2021 for discussion of the possibilities of involvement of endometrial stem cells rather than endometrial epithelial/stromal cells, involvement of bone marrow stem cells, induction (initiation or activation) by other substances in menstrual fluid, and the findings being the consequence rather than the cause of endometriosis. See Simon 2015 and Brenhouse 2016 for neuroimmune maturation.
94. Semm 1984 (German), Semm 1987 (English) – *“The surgical excision of endometriosis implants is still considered the optimal treatment of pelvic endometriosis.”*
95. Martin 1985, 1986a, 1986b, 1986c, 1986d, 1987, 1988a, 1989 – Development of laparoscopic excisional techniques for deep endometriosis. The difference between CO₂ laser vaporization for excision, vaporization to turn the lesion into an aerosol plume, and coagulation (fulguration) was discussed and refined. See Semm 1980, 1981, 1984,1987.
96. Martin 1985, 1986b, 1986c, 1986d, 1987 – Development of laparoscopic excision resulted in confusion regarding the terms as they were different than those used in colposcopy. The current colposcopy terms were adopted. Initially, CO₂ laser vaporization was called ablation. This was used in colposcopy for cryotherapy. The terms evolved so that ablation included electrosurgical coagulation, cryotherapy, and focused sonogram. Although some still use ablation to be synonymous with vaporization, these are two different tissue techniques. Wide zone (low power density) vaporization is using a laser to turn tissue into a plume of vapor and carbon. Thin zone vaporization (high power density) is using a laser as a hot knife to

remove an intact tissue specimen. Although vaporization appears reasonable for superficial lesions, excision is better for deep lesions. (Barton-Smith 2010)

A recent adaptation of slide 041 in Martin 1986c is:



Adapted with permission from *Intra Abdominal Laser Surgery*, 1986, Renage Press, Richmond, www.danmartinmd.com

97. Batt 1985 – There are two types of endometriosis: the congenital (Müllerianosis) and the acquired forms. The human female may harbor endometriosis from embryonic life until death, the disease being active or inactive at various times. See Batt 1989, 2013 and 2015.
98. Vernon 1986 – There are differences in prostaglandin production in the four (4) surface phenotypes examined. “*Petechial implants may be more pathologically influential than older implants.*” *A patient who presents with severe, progressive dysmenorrhea but is shown at laparoscopy to have minimal disease may have exaggerated pain symptoms as a result of the presence of the more biochemically active, petechial implants, whereas a patient with extensive disease may have minimal pain symptoms due to the presence of primarily inactive, powder-burn implants.*” See Davis 1993
99. Taylor 1986 –CO₂ laser secondary thermal burn (cautery) using low power density can be more significant than the 0.1 mm theoretical intrinsic penetration. The thermal coagulation was 2.7 mm at 30 watts/cm². Also, see Luciano 1987
100. Murphy 1986 – Nonvisualized “microscopic” endometriotic lesion with a glandular opening of 350 μ and a bulge of 700 μ using loupes for magnification. See Redwine 1988a for “near-contact” laparoscopy, Nisolle 1990 and Redwine 1990 for microscopic endometriosis, Nezhat 1993 for nonvisualized peritoneal and retroperitoneal endometriosis, and Roman 2021 for nonvisualized but palpable bowel endometriosis.
101. Thomas 1987 – Hormonal suppression with gestrinone after laparoscopy decreases the risk of progression compared with no suppression. Spontaneous regression occurred in both groups. See Dmowski 1975.
102. Luciano 1987 – The thermal effect of CO₂ laser and electrosurgery are similar at high power density. The coagulation depths were less than 0.2 mm at > 58,000 watts/cm² but did not reach the 0.1 mm theoretic limit of penetration of a CO₂ laser. See Taylor 1986.
103. Martin 1988a, Angioni 2006 – Deep excision to the vagina can be performed with laparoscopic colpotomy. Acknowledgement (1988a) “Drs. Richard “Pete” Hollis, Harry Reich and Gordon Davis were instrumental in the development of these deep excisional techniques.”
104. Moore 1988 – Five patients had deep retroperitoneal involvement and rectovaginal lesions as large as 4 cm with little or no intraabdominal disease. Three of these patients had either complete ureteral obstruction, hydronephrosis or full thickness involvement of the rectum.

The disease was severely symptomatic, difficult to diagnose, and challenging at surgery. Four of the patients were over 40 years old and this appeared to be a late onset disease. See Griffiths 2007 for rectovaginal endometriosis missed at first laparoscopy but identified using a rectal probe in 14 (88%) of 16 cases. See Roman 2021 for nonvisualized but palpable bowel endometriosis prospectively missed at laparoscopy.

105. Halme 1988, Hill 1992, Vinatier 1996, Dmowski 1998, Gebel 1998, Giudice 2004, Northick 2016, Pavone 2016, Koninckx 2018, Masuda 2021 – Lack of immunologic competence results in an inadequate response of the peritoneal defense system to the normal retrograde flow that is present in most women. The inadequate immunologic response results in evasion of apoptosis allowing endometriosis cells to continue to live. According to the peritoneal immune surveillance hypothesis, only women with local and/or systemic immune defects develop late endometriosis. In Koninckx 2018 called late endometriosis “endometriotic disease.” See Simon 2015 and Brenhouse 2016 for neuroimmune maturation.
106. Redwine 1988a – Redwine’s “near-contact” is a more descriptive term than Goldstein’s 1980 “close-up” view needed for recognizing subtle, atypical, and petechial-like appearances of endometriosis. See Redwine 1990 for microscopic lesions. See Roman 2021 for nonvisualized but palpable bowel endometriosis missed at laparoscopy.
107. Redwine 1988b – Redwine proposed the term Mülleriosis for a model that included a Müllerian cell of origin and any observed defects in the differentiation, transition, or position of those cells. He also discussed metaplasia as a second model. See Redwine 2019 for change to a mesodermal theory.
108. Batt 1989 – Batt considered pockets to be congenital Müllerian remnants and not acquired lesions. He considered the acquired pockets in Martin’s 1988 slide set were due to surgical trauma. (<https://www.danmartinmd.com/files/lae1988.pdf>) This was later expanded into a theory of congenital Müllerianosis and acquired Müllerian diseases. Both include adenomyosis, endometriosis, endosalpingiosis, and endocervicosis. Medial ureteral position was due to an attenuated uterosacral ligament or as the medial border of a large fossa associated with endometriosis is congenital. See Batt 2013. Batt also graded the histologic certainty as:
 - Grade 1: Possible residual of resorbed endometriosis, i.e., hemosiderin, calcium, nerve, blood vessels, and smooth muscle.
 - Grade 2: Consistent with endometriosis, i.e., hemosiderin, characteristic glands, or stroma.
 - Grade 3: Definite endometriosis, i.e., characteristic glands AND stroma with hemosiderin.
 - Grade 4: Grade III with structures conveying an organoid pattern, i.e., glandular-stromal layer overlying a well-developed smooth muscle layer.
109. Martin 1989a – The diagnosis of endometriosis at laparoscopy increased from 42% in 1982 to 72% in 1988. The greatest change was in “subtle” lesions, which increased from 15% in 1986 to 65% in 1988. Thirteen of the 20 laparoscopic surface appearances of endometriosis were phenotypic. In 2018, we do not know if only some or all these have similar or contrasting characteristics. Vernon (1986) used four other descriptive superficial phenotypes. See Roman 2021 for lesions missed at laparoscopy.
110. Martin 1989b, Davis 1993 – The type of procedure should consider the depth of infiltration. The definition of deep decreased from 5 mm in 1989 to less than 3 mm in 1993. Clinically,

this definition was not overly useful as it could only be determined after the lesions were excised. The concept then changed over several years to peritoneal and infiltrating lesions. Infiltration and pain were generally associated with fibrosis and depth (Ripps 1991, Ripps 1992, Khare 1996, Viganò 2017, and Liu 2017). Furthermore, even superficial appearance could be associated with infiltration to 4 mm (Koninckx 1991). Manual palpation at laparotomy provided recognition of deep lesions, subperitoneal nodules, epiploic fat nodules, appendiceal nodules, and infiltrating bowel lesions. See Hollis 1984 for three steps of palpation for nodules or focal tenderness.

111. Cornillie 1990 – In-phase cyclic changes are different in deep (≥ 5 mm), intermediate (2 to 4 mm), and superficial (< 1 mm) endometriosis.
112. Martin 1990a – There was a 64% increase in histologic diagnosis of endometriosis between 1982 and 1986 associated with the appreciation of multiple appearances of endometriosis. See Stripling 1988a, Stripling 1988b, and Martin 1989a.
113. Martin 1990b – The gross characteristics of a chocolate cyst are not always predictive of histology. 25 (61%) of 41 chocolate cysts were histologically confirmed to be endometriosis, 5 cysts (12%) were nondiagnostic, whereas 11 (27%) were corpus luteum or albicans. Those with a flattened appearance and red or red and brown mottled ridges were usually endometriosis, while those with a dark uniform base, an intracavitary clot, or a yellowish rim generally were corpus lutea or albicans. See Lobstein (1820) in Redwine 2012.
114. Nisolle 1990 – Nisolle et al. focused on the multiple appearances documented in Jansen (1986), Martin (1989) and Stripling (1988a & 1988b). Despite this focus, histologically confirmed endometriosis was found in the normal peritoneum of 13% of women with other areas of endometriosis and 6% of women with no evidence of endometriosis. The size of endometriotic lesions 88 μ to 720 μ . See Murphy 1986, Redwine 1990, and Nezhat 1993.
115. Candiani 1990 – Small, deep ovarian endometriomas are not easily diagnosed. Endometriotic material was aspirated in 25 (48.0%) of 52 infertile patients with a normal appearing ovary with a smooth whitish surface. Eight (15%) had no other endometriosis and were rASRM 0-0 based on the appearance before the aspiration and rASRM I to III based on the aspiration. See Russell 1989 and Longo 1979.
116. Redwine 1990 – Three visually normal study biopsies had glandular structures identified histologically. Two of these study biopsies appeared to be mesothelial inclusions with one of 30 μ . The third gland had no obvious endometrial stroma, but a pathologist suggested that this might be endometriosis. The diameter was 120 μ . “*Visually normal peritoneum does not harbor a high prevalence of invisible microscopic endometriosis.*”
117. Redwine 1991 – Redwine reported 88 (55% by lifetime analysis) reoperations in 6.5 years. Of those, 35 had endometriosis with 33 (94.3%) of 35 persistence found in areas not previously treated and 2 (5.7%) recurrences in areas previously treated. Many, if not most, had abnormalities seen on previous pictures like the satellites and abnormal peritoneum missed by Martin (1988b) on [image 3b](#) in the first edition [Laparoscopic Appearance of Endometriosis](#). An additional 53 had no endometriosis discovered.
118. Cornillie 1991 – Endometrial protein PP14 positivity varies in deep (≥ 5 mm), intermediate (2 to 4 mm), and superficial (≤ 1 mm) endometriosis.

119. Koninckx 1991, Koninckx 1994, Vinatier 1996, Gordts 2017, Koninckx 2018 – Deep endometriosis is endometriotic disease (late endometriosis). Superficial (early) endometriosis is either stopped by the immune system or converts into endometriotic disease. See Holder 2014, Simon 2015, and Brenhouse 2016 for neuroimmune maturation.
120. Koninckx 1991 – Infiltration found in 4% of superficial appearing vesicles at 5-6 mm and 3% of polyploid lesions at 3-4 mm. The data is in table 3.
121. Portz 1991, Vitale 2018 – Reactive oxygen species (ROS) or free radicals may increase the growth and adhesion of endometrial cells in the peritoneal cavity, promoting endometriosis and infertility.
122. Ripps 1991 – Pain and tenderness are associated with fibrosis (scarring) of implants.
123. Suginami 1991 – Suginami concluded that the multiple sites of endometriosis were most compatible with coelomic metaplasia. Pulmonary implants may be from dissemination through cribriform fenestrations (called communication in Brews 1954 and perforations in Maniglio 2017) See Que 2019 for recent concepts of metaplasia, paligenesis, differentiation, transdifferentiation and transcommitment.
124. Oosterlynck 1991 – Natural killer (NK) activity and the cytotoxicity against autologous endometrial cells were similarly decreased in women with endometriosis and correlated with the severity of the disease. The decreased cytotoxicity to endometrial cells in women with endometriosis is mainly because of a defect in NK activity but is also partially because of a resistance of the endometrium to NK cytotoxicity. Oosterlynck 1994 and Gazvani 2002.
125. Ripps 1992 – Persistent focal tenderness is associated with implants having a mean depth of 5.3 mm and volume of 1.2 cm³.
126. Koninckx 1992 – Deep endometriosis in the area of the rectovaginal pouch has three phenotypes: “Type I is conical shaped and suggested to be formed by infiltration. Type II is deeply located and covered by extensive adhesions and probably formed by retraction. III is a form of adenomyosis externa with most of the volume hidden in a retroperitoneal location and is generally deeper than 2.0 cm. Type III is compatible with a Müllerian rest origin. Also see Donnez 1997 and Nisolle 1997.
127. Moen 1993 – Endometriosis or adenomyosis was disclosed in 3.9% of mothers of cases and in 0.7% of mothers of controls, in 4.8% of sisters of cases and in 0.6% of sisters of controls. Severe manifestations of endometriosis were found more often among patients with a positive family history than among those without.
128. Thomas 1993 – The only clear recommendation for treatment is in symptomatic patients. The short-term effects of medication and surgery may be placebo. See Thomas 1996 for a tendency for endometriosis to worsen over time if untreated.
129. Rier 1993 – Environmental toxins such as dioxin may increase the risk of endometriosis by modulating the immune response of altering tissue-specific responses to hormones. See Rier 1995 & 2001 for estrogenic toxicants, Umezawa 2011 for diesel fuel toxicology, Huang 2016 for comparison of dioxin-like and non-dioxin-like polychlorinated biphenyls (PCBs), Liang 2016, 2018, & 2019 for estrogen interactions, Smarr 2016 for endocrine disrupting chemicals, and Peinado 2020 for bisphenols. See Holder 2014, Simon 2015, and Brenhouse 2016 for neuroimmune maturation. See Hall 2023 for cadmium.

130. Hoshiai 1993 – Serial laparoscopies in symptomatic patients confirm that the development of endometriosis is non-linear, even when symptomatic. They have examples of progression, regression, and regression followed by progression. It is possible, if not likely, that asymptomatic patients could add progression followed by regression. See Evers 1994, Martin 1999, and the “Pimple Model” (Martin 2005)
131. Haney 1993 – Endometriosis is associated with a localized sterile inflammatory process, growth factors, cytokines, and activated macrophages in the peritoneal fluid. See Hogg 2020.
132. Davis 1993, Vercellini 1991 – Adolescents with functional pain, cyclic pain, abdominal pain, nausea, constipation, and diarrhea during menses have the greatest proportion of red lesions. See Vernon 1986.
133. Nezhat 1993 – Nonvisualized endometriosis included a 1 mm retroperitoneal nodule, too large to be called microscopic, and two surface stromal lesions of 200 μ and 300 μ . See Murphy 1986, Nisolle 1990, and Redwine 1990
134. Adamyan 1993, Martin 2001, Batt 2014 – Rectovaginal endometriosis is retrocervical. Some retrocervical endometriosis is not rectovaginal. The normal area of the rectovaginal septum is rarely, if ever involved, as the area is distal to the distal margin of most, if not all, endometriotic lesions. The only lesion that I treated in the normal area of the rectovaginal septum was a benign tender desmoid tumor.
135. Chan 1993 – Vitamins E and C constitute a strong line of defense in retarding free radical induced cellular damage. Also see Agarwal 2005, Mier-Cabrera 2009, Nishihara 2018.
136. Khare 1993 – Ablation with bipolar coagulation or CO₂ laser vaporization can damage vital structures without being seen during surgery.
137. Evers 1994 – “Endometriosis does not exist; all women have endometriosis” reflect the opinion that endometrial explants in the peritoneal cavity are a physiological finding in all menstruating women and that, as such, they do not constitute a disease in its proper sense.
138. Adamson 1994. – Surgery or no treatment is better than medical therapy for fertility.
139. Oosterlynck 1994 – CA 125 levels, but not natural killer (NK)-mediated cytotoxicity, are decreased after excision. These data suggest that natural killer activity is a primary deficiency in women with endometriosis and the elevated CA 125 is a consequence of endometriosis. See Oosterlynck 1991 and Margatho 2018 for response to etonogestrel (ENG) implant and levonorgestrel-releasing intrauterine system (LNG-IUS); review in Gazvani 2002: and Moss 2005 for comments on overuse of CA 125.
140. Wild 1994, Nisolle 2000, Witz 2002 – Endometrial stromal cells and epithelial cells can attach to the peritoneum within one hour, and the mesothelium can be replaced by 24 hours. These observations were in research on animals. Research at this level in humans will likely continue to be unethical without a significant paradigm shift in technology.
141. Sutton 1994 – Pain relief at three months is not significantly different between a patient who had endometriosis removed and those who had a diagnostic laparoscopy only. At six months the placebo response had resolved, and pain recurred in the diagnostic only group.
142. Shapiro 1994, Landin-Romero 2018 – Eye desensitization and reprocessing that was initially used for trauma and substance abuse has since been exported to areas including pain management.

143. Tran 1994, 2012 – Inflammatory appearance added to staging. Also see the review in Bouquet de Joliniere 2019.
144. Rier 1995 – TCDD (dioxin) is an environmental toxicant that alters the action of estrogen in reproductive organs and adversely affects immunocompetence. See Rier 1993, Rier 1995, Rier 2001 (TCDD), Caserta 2008, Smarr 2016, Bruner-Tran 2016, Peinado 2020 (bisphenols), and Rumph 2020 for endocrine disrupting chemicals. See Umezawa 2011 for diesel fuel toxicology; Huang 2016 for comparison of dioxin-like and non-dioxin-like polychlorinated biphenyls (PCBs); Liang 2016, 2018, & 2019 for estrogen interactions; Holder 2014, Simon 2015, and Brenhouse 2016 for neuroimmune maturation; and Hall 2023 for cadmium.
145. Lessey 1995 – Abnormal endometrial integrin expression was a frequent finding in women with unexplained infertility. These data suggest that defective uterine receptivity may be an unrecognized cause of infertility in this population of women. See Grandi 2016, Likes 2019, Lessey 2017, and Vargas 2022.
146. Perper 1995 – Menstrual cramps (dysmenorrhea) are related to the number of implants.
147. Fernandez 1995 – Bone marrow-derived (BMD) cells were found in endometriosis by Fernandez (1995) but not Ong et al (2018). The possibility that the BMD data is artifactual has been discussed at meetings. See Starzinski-Powitz 2001 & 2003 for differentiation, Meng 2007 & Chen 2019 for menstrual blood-derived stem cells, Hufnagel 2015 and Wang 2020 for BMD stem cells engrafted in endometriosis, Miyazaki 2018 for pluripotent stem cell, and Yin 2019 for CD34 (bone marrow derived stem cell marker) in endometrium. See Ong 2018 who concluded that it is unlikely that bone marrow cells are able to transdifferentiate into endometrial stroma, epithelium, and endothelium. Search file for “stem cell” for others. NOTE: Bone marrow-derived stem cells may engraft and *“differentiate into multiple cell types including endothelial, muscle, stromal, and epithelial cells.”* They are not specific for endometriosis. (Mamillapalli 2021)
148. Abu-Hijleh 1995 – Diaphragmatic lymphatics drain into retrosternal (parasternal) lymphatic trunks that carry lymph to the great veins after it filters through mediastinal lymph nodes may be the source of mediastinal cases such as Yasukawa 2018.
149. Khare 1996 – Differences in collagen types suggest that ovarian endometriosis may be metastatic while pelvic wall-infiltrating endometriosis is metaplastic.
150. Thomas 1996 – There is evidence of some improvement of endometriosis spontaneously, it was more marked with gestrinone therapy. The striking finding was that there is a tendency for endometriosis to worsen over time if untreated, but this does not occur in women on gestrinone therapy.
151. Noble 1996 & Noble 1997 – Aromatase is elevated in both endometriosis and eutopic endometrium of patients with endometriosis. See Bulun 1999, Attar 2006a, Attar 2006b, Maia 2008, Northnick 2016, Mori 2019
152. Vinatier 1996 – In some women refluxing endometrial cells are not destroyed, either because the patient is genetically programmed not to respond to endometrial antigens, or because the reflux is so abundant that the scavenging capacity of the peritoneal immune cells is overloaded.

153. American Society for Reproductive Medicine 1997 – Eight phenotypic laparoscopic appearances added to 1985 rAFS classification for the 1996 rASRM classification. Four images are from Martin 1990d (<https://www.danmartinmd.com/files/coloratlas1990.pdf>)
154. Nisolle 1997, Donnez 1997 – Peritoneal, ovarian, and rectovaginal nodules are three different entities. Rectovaginal nodules may be from Müllerian rests. See Koninckx 1992.
155. Gaetje 1997 – Invasion based on E-cad- epithelial cells
156. Regidor 1997 – The expression of gap junction connexins (Cx) in the human endometrium is highly regulated by steroid hormones. Aberrant expression of Cx43 was found in the epithelium of nearly all endometriotic glands whereas Cx26, typical for human uterine epithelium cells, was only detected in 18 cases; in 17 it was co-expressed with Cx43. The stromal compartment of the tissues did not express any connexins investigated. Staining for Cx32 was absent in all endometriotic tissues. The patterns described demonstrate an aberrant connexin expression and a different hormonal regulation pattern in endometriotic tissues compared to the normal cyclic uterine endometrium, thus indicating a high dedifferentiation from the normal situation. Although the connexin expression in the endometriotic implants was aberrant, this work suggests that it is still under hormonal control. Patients treated with GnRH agonists showed a complete down-regulation of the connexins studied and showed a significant improvement in their pain symptomatology. See Grund 2018 for cell-cell interactions.
157. Yamamoto 1997 – A 13-year-old had a right salpingectomy and para-ovarian cyst removal for right hematosalpinx. Clinically unrecognized tubal endometriosis was diagnosed in histology. The ovaries and uterus were completely normal by inspection.
158. Dmowski 1998 – Cell-mediated immunity in patients with endometriosis is decreased. The decrease in the capacity of monocytes to mediate cytolysis of the misplaced endometrial cells in the peritoneal locations and an increased resistance of these cells to apoptosis are fundamental to the pathophysiology of endometriosis.
159. Gebel 1998 – The susceptibility of endometrial and endometriotic tissue to spontaneous apoptosis is significantly lower in women with endometriosis than in fertile controls.
160. Leyendecker 1998, 2009, 2015, 2022 – Uterine dysfunction in women with archimetrosis (endometriosis and adenomyosis) is a result of archimetral hyperestrogenism. Intrauterine tissue injury and repair (TIAR) at the endometrium-muscularis interface due to intrauterine trauma produces estrogens that interfere in a paracrine fashion with the ovarian control over uterine peristaltic activity, resulting in permanent hyperperistalsis and a self-perpetuation of the disease process. Uterine peristalsis is part of directed sperm transport and occurs during menstruation in the non-pregnant uterus.
161. Vandivier 1998 – Vandivier quoted Dr. Frank Ling as discussing that ‘When in doubt, cut it out’ does not make sense when many patients are no better after surgery than before surgery. A team approach to pain management employing not just gynecologists, but also psychologists, nutritionists, and physical therapists is needed. See Surrey 2018 and Leuenberger 2022 for comorbidities.
162. Balas 1998, Balas 2000, Kaiser 2003, Brownson 2006, Green 2009, Owoeye 2020 – The slow adoption of new research findings is related to several factors including time delays that include the times from research to submission, acceptance, location, acquisition by bibliographic databases, incorporation into reviews and textbooks, and implementation. That

processes can result in an average delay to implementation of 17 years without direct marketing. Nobody wants inappropriate care, but there is not much evidence that insisting on appropriateness, which is the vaguely defined consensus of experts, can lead to better patient care. A major problem with appropriateness is that it based on consensus of experts—the lowest level of evidence-based medicine. See Kaiser 2003 for effect of the effect of direct-to-consumer (DTC) advertising.

163. Risch 1998, Cotreau 2003, Olsen 2008 – Risch’s 1998 hypothesis that androgens can stimulate ovarian epithelial cell proliferation and cancer was expanded to include danazol therapy for endometriosis by Cotreau (2003). But the androgen hypothesis and danazol conclusions were rejected by Olsen (2008).
164. Mathias 1998 – Mathias et al. (1998) found that bacterial overgrowth, assessed by breath hydrogen values, responded to eight weeks of treatment using dietary changes, balancing with omega 9 oils, adding of omega 3 fatty acids, as using drug therapy with clonazepam (0.25 mg 3 times per day). They also reduced glycemic carbohydrates and foods with caffeine and tyramine. After treatment, there was a significant reduction in the total endometriosis-associated bowel motility score. Antibiotics were not necessary. Post-treatment breath hydrogen was not reported; this may be clonazepam rather than the other changes. See van Haaps (2023) for an endometriosis diet positively affecting the quality of life.
165. Ling 1999 – Ling et al. found that 82% of a population of 18- to 45-year-old women seen by a gynecologic pain specialist with “moderate to severe chronic pelvic pain for at least 6 months” that was “incompletely relieved with nonsteroidal anti-inflammatory drugs” had endometriosis at laparoscopy. Lings’ inclusion criteria are an example of selection bias (Shafir 2018, Horne 2022, Ghiasi 2020) and resulted in a population with an 82% prevalence of endometriosis. Pain relieved with GnRNA was found in 82% of those with and 73% of those without endometriosis. The 2005 ACOG (CO 310) conclusion that GnRH agonists could be used to make a diagnosis of endometriosis was subsequently reversed in the 2010 ACOG Practice Bulletin 114 with the clarification that “empiric therapy does not confirm the diagnosis of endometriosis.” See Ferrero (2010) for 90% confirmation if suspected based on pelvic or uterine pain during menstruation, genital pain on deep penetration, pelvic pain for more than six months, painful bowel movements, and ultrasound. Also, see Jenkins 2008 and Momoeda 2014.
166. Evers 1999 – In an article that generally discussed infertility, Evers and Dunselman noted that Balasch et al.’s (1996) 5.5% positive biopsy rate in normal women without endometriosis confirmed Nisolle et al. (1990), who “*found 6% positive biopsies in non-endometriosis patients. These investigators only took one biopsy per patient. This means that, if they had taken > 16 biopsies per patient, and if sufficient sections had been studied, then all women would have had endometriosis.*” See Scott 1953, Evers 1994, Koninckx 1994, Evers 1999, Koninckx 1999, Harrison 2000, Nap 2004a, Koninckx 2018.
167. Knapp 1999 – Knapp concluded that 17th and 18th century reports of “ulcerated” inflammatory lesions were compatible with endometriosis. Although histology was in its infancy and was not discussed, Shroen’s 1690 descriptions of the occurrence in maturing women, symptomatology, distribution, and hemorrhage are more consistent with endometriosis than what we would now call a ulcerative disease. If the term “ulcer” in the 17th century can also mean any lesion, then the description was likely endometriosis. His

review includes Shroen 1690 and five 18th century references. Discussions are in Batt 2000, Brosens 2000, and Batt 2011a.

168. Martin 1999 – Discusses retroperitoneal endometriosis in a Rhesus monkey that converted to surface endometriosis when she bled and opened the cystic lesion, a rectovaginal nodule was not seen at laparoscopy or laparotomy, a 14-year old who progressed from a flat peritoneal stromal endometriosis to pockets with polypoid endometriosis at age 15, the patient with the two perirectal pockets with only one having an entrance, and deep endometriosis that failed to respond to coagulation. Of note, the 14-year old had a second laparoscopy at age 15, suppression for four years, a miscarriage at age 20, a son at age 21, and was doing well at age 22. See Roman 2021 for nonvisualized but palpable bowel endometriosis.
169. Bulun 1999 – The enzyme, aromatase, is aberrantly expressed in endometriotic stromal cells and catalyzes the conversion of C19 steroids to estrogens, which then stimulate cyclooxygenase-2 to increase the levels of PGE2. PGE2, in turn, is a potent inducer of aromatase activity in endometriotic stromal cells. The clinical relevance of local aromatase expression in endometriosis was exemplified by the successful treatment of an unusually aggressive form of recurrent endometriosis in a postmenopausal woman using an aromatase inhibitor. See Noble 1996 & 1997 1997, Attar 2006a, Attar 2006b, Maia 2008, Northnick 2016, Mori 2019
170. Vigano 1999 – Cell adhesion molecules can engage and transduce a signal that leads to cellular events to change “the phenotype, movement, gene expression or activation state of the cell. On the other hand, cytoplasmic signals regulate the functional activity and surface expression of these receptors.” These molecules transfer information in both directions across cell membranes to influence developmental and immune characteristics.
171. Treloar 1999 – Tetrachoric twin pair correlations for self-reported endometriosis suggest that 51% of the variance of the latent liability to endometriosis may be attributable to genetic influences.
172. Starzinski-Powitz 1999 – Like tumor metastasis, endometriotic cells can invade and metastasize. Cell adhesion molecules appear central for invasion and metastasis.
173. Starzinski-Powitz 2001, 2003 – Differentiation of stem cells into endometriotic cells. See Meng 2007 and Chen 2019 for menstrual blood-derived stem cells and Wang 2020 review. NOTE: Bone marrow-derived stem cells may engraft and “*differentiate into multiple cell types including endothelial, muscle, stromal, and epithelial cells.*” They are not specific for endometriosis. (Mamillapalli 2021) See Fernandez 1995 for the possibility that the BMD data is artifactual.
174. Martin 2001 – The retrovaginal (RV) length distal to a rectovaginal nodule is increased due to contraction of the RV pouch and may be lengthened RV septum. See Takeuchi 2005 for a conclusion that the septum fractured rather than lengthening. See Adamyan 1993 for retrocervical endometriosis and Batt 2014 for retrocervical septum.
175. Donnez 2001, Squifflet 2001 – Retroperitoneal adenomyotic disease (RAD) results from metaplasia in Müllerian remnants. See Koninckx 1992, Signorile 2010, and Signorile 2012. See Que 2019 for recent concepts of metaplasia, paligenosis, differentiation, transdifferentiation and transcommitment.

176. Rier 2001 – TCDD-exposed rhesus monkeys with endometriosis exhibit long-term alterations in systemic immunity associated with elevated serum levels of specific PHAH congeners. Exposure to 2,3,7,8-tetrachlorodibenzo-p-dioxin (TCDD) correlated with increased peripheral blood mononuclear cells (PBMC) tumor necrosis factor-alpha (TNF-alpha) secretion in response to stimulation by T-cell mitogen and decreased cytolytic activity against NK-sensitive target cells.
177. Redwine 2002 – Thirty-eight differences between eutopic endometrium and endometriosis in humans are reviewed. Does not discuss that Sampson (1921a) saw that endometrium and endometriosis were different. Sampson (1921a) published this first.
178. Gazvani 2002 – The peritoneal environment can influence the development of endometriosis. In women with endometriosis, there appears to be an alteration in the function of peritoneal macrophages, natural killer cells, and lymphocytes. Furthermore, growth factors and inflammatory mediators in the peritoneal fluid, produced mainly by peritoneal macrophages, are altered in endometriosis, indicating a role for these immune cells and mediators in the pathogenesis of this disease. See the “[Subtle Inflammatory Lesions](#)” section of this document. See Holder 2014, Simon 2015, and Brenhouse 2016 for neuroimmune maturation.
179. Kats 2002 – Macrophage migration inhibitory factor is higher in early (subtle red) than in late (blue, black, or white) lesion appearances. See Hogg 2020 review.
180. Sumathi 2002 – CD10 is a useful immunohistochemical marker of normal endometrial stroma and of endometrioid stromal neoplasms. Endometriotic stromal cells were positive for CD10 in 22 of 25 cases. See Potlog-Nahari 2004.
181. Tosh 2002 – See Tosh 2014 for metaplasia as replacement by differentiation of stem cells rather than the transdifferentiation of differentiated cell types. See Que 2019 for recent concepts of metaplasia, paligenosis, differentiation, transdifferentiation and transcommitment.
182. Sinaii 2002 – Hypothyroidism, fibromyalgia, chronic fatigue syndrome, autoimmune diseases, allergies and asthma are more common in women with endometriosis. Women with endometriosis had higher rates of hypothyroidism (9.6% vs 1.5%), fibromyalgia (5.9% vs 3.4%), chronic fatigue syndrome (4.6% vs 0.03%), rheumatoid arthritis (1.8% vs 1.2%), systemic lupus erythematosus (0.8% vs 0.04%), Sjögren’s syndrome (0.6% vs 0.03%) and multiple sclerosis (0.5% versus 0.07%), but not hyperthyroidism or diabetes. Allergies and asthma were more common among women with endometriosis alone (61% and 12% respectively) and highest in those with fibromyalgia or chronic fatigue syndrome (88% and 25%) than in the USA female population (18% and 5%).
183. Moen 2002 – At 12 to 14 years, women with asymptomatic endometriosis at sterilization had no significant difference in dysmenorrhea, premenstrual pain, dyspareunia, or hysterectomy rate compared with women with no endometriosis. Unexpectedly, pelvic pain was more frequently reported by control women than by women with endometriosis (28% vs. 6%). The chance of future surgery is 3% for asymptomatic mild endometriosis seen at tubal ligation. See Fedele 2004a for asymptomatic rectovaginal endometriosis.
184. Batt 2003 – Congenital anomalies associated with possible Müllerian defects or rests include peritoneal pockets. These findings suggest Müllerian anomaly as the source for these focal lesions. See Martin 1988b, pages 5&6, for acquired pockets.

185. Kaiser 2003 – Direct-to-consumer (DTC) advertising increased drug sales on average by 1% for every 10% increase in DTC advertising. DTC advertising accounted for 12% of the total growth in drug spending in 2000. A similar method using cheaper social media can likely speed the average delay to implementation of 17 years in Balas 1998, Balas 2000, Brownson 2006, and Green 2009.
186. Giudice 2004 – A growing body of evidence indicates that a combination of genetic, hormonal, environmental, and immunologic factors play a role in the pathogenesis of this disorder. A lack of adequate immune surveillance in the peritoneum is thought to be a cause of the disorder. According to this hypothesis, only women with a local and/or systemic immune defect develop endometriosis. The endometrium of women with endometriosis is believed to be abnormal and predisposes to successful establishment of ectopic disease. This view is compelling, especially since most women have some degree retrograde menstruation but only 6 to 10% of endometriosis. Conditions that might predispose to establishment include genetics, environmental factors, and immune surveillance (activation of peritoneal macrophages with increased cytokine production). See Holder 2014, Simon 2015, and Brenhouse 2016 for neuroimmune maturation.
187. Bulun 2004, Nothnick 2016 – Inflammatory reaction exponentially increases local aromatase activity. Also see Noble 1996 & 1997 1997, Bulun 1999, Attar 2006a, Attar 2006b, Maia 2008. Nothnick 2016 is open access <https://www.ncbi.nlm.nih.gov/pmc/articles/PMC4760268/>
188. Chan 2004 – Endometriosis is clonal.
189. Potlog-Nahari 2004 – The addition of CD10 immunohistochemistry detected more positive endometriosis lesions than H&E staining alone. CD10 staining led to the diagnosis of endometriosis in 11 of 70 specimens. See Sumathi 2002, Signorile 2010, and Signorile 2012 for CD10.
190. Fedele 2004a – There is an age-associated decreased recurrence of pain or surgery/GnRH from 56% and 54%, respectively, at <25 years of age to 0% and 0% at >35 years of age. See Moen 2002, Shakiba 2008, Yeung 2011, and Martin 2015.
191. Fedele 2004b – Fedele et al. followed 88 patients with untreated asymptomatic rectovaginal endometriosis for 1 to 9 years and found that only 2% of them had specific symptoms attributable to rectovaginal endometriosis and associated with an increase in lesion size. Those two patients underwent surgery. An additional 5% had an increase in lesion size but remained symptom-free, and 93% showed no clinical or imaging changes.
192. Law 2004 – John Law (2004) states that the world can be vague, ephemeral, slippery, emotional, and indistinct. It can change like a kaleidoscope or might not have much of a pattern. Research must embrace this reality and avoid oversimplification. Schuurman (2023) uses similar concepts embracing the complexity of how this translates into understanding sepsis. The concepts in Endometriosis Concepts and Theories support Law's premise. Luckily, for most activities, Atul Gawande is correct; checklists (2009) work. Complexity can often be boiled down into finite, actionable events; A trivial example is a light switch. All we need to know for everyday use is how to throw the switch and occasionally how to locate a ladder, find backup bulbs, and change the bulb. We might need secondary plans for broken bulbs or other uncommon events, but we do not need a working knowledge of nuclear fission, nuclear power, turbine engines, dynamos, high-voltage transmission lines,

transformers, alternating current, direct-current, step-up voltage, copper wiring, conductivity, and many other concepts.

193. Petta 2005 – Levonorgestrel-releasing intrauterine system is useful for the treatment of pain.
194. Takeuchi 2005 – Takeuchi saw no continuity between the rectovaginal septum and the lesion. Endometriosis in the contracting rectovaginal pouch may tear away from the septum, and the tissue behind the upper vagina may be loose connective tissue or scar rather than elongated septum.
195. Martin 2005 – The pimple model is one of several comparisons of endometriosis to other diseases that can have limited or chronic phases. Almost everyone has pimples, most are mild and resolve spontaneously, some get worse, and some come and go (Hoshiai 1993, Martin 1999). Also, some are inflammatory, some get better on medication (estrogenic BCPs, Accutane, antibiotics including tetracycline possibly more for its anti-inflammatory than its antibacterial properties), some cause pain, others do not, pain is not always related to the appearance, some cause scarring, some are treated with surgery (dermabrasion), and some are chronic and nonresponsive.
196. Marsh & Laufer 2005, Cabana 2010 – Inflammation may be a precursor, facilitator, or early presentation. Inflammatory induction (initiation or activation) of coelomic metaplasia or of a damaged peritoneum as a fertile ground for implantation may precede endometriosis. Endometrial or endometrioid stroma can be challenging to recognize in inflammation (Clement 2007), and the conclusion that inflammatory and reactive lesions are endometriosis is reasonable. However, neither Marsh and Laufer (2005) nor Cabana et al. (2010) used stromal markers such as CD10. Nor did they exclude infection, endotoxins, or other causes of inflammation (Khan 2010, Khan 2014, Khan 2016, Canis 2017, Leonardi 2020a) as the source of the inflammation.
197. Agrawal 2005 – Before clinicians recommend antioxidants, randomized controlled trials with sufficient power are necessary to prove the efficacy of antioxidant supplementation in disorders of female reproduction.
Open Access: <https://rbej.biomedcentral.com/articles/10.1186/1477-7827-3-28>
198. Moss 2005 – Moss reviewed the high false positive rate and poor sensitivity and specificity associated with CA 125 screening. The substantial inappropriate usage of CA 125 has led to results that are useless to the clinician, have cost implications, and add to patient anxiety and clinical uncertainty. In female patients having a CA125 for suspicion of malignancy/ovarian cancer, only 39 (20%) of the abnormal results were caused by ovarian cancer. Transvaginal ultrasonography has a greater sensitivity and specificity than CA125 for diagnosing ovarian cancer. Open Access: <https://jcp.bmj.com/content/58/3/308.long>. See Sasamoto 2020.
199. Guo 2006 – Guo and Wang clarified the heterogeneous sources of the 2%–22% variance of the overall prevalence of diagnosed endometriosis with 2.1% to 77.1% in infertile women and 1.4% to 50.0% in fertile women.
200. Klemmt 2006, Akoum 2006, Klemmt 2007, Grümmer 2012, Klemmt 2018 – Changes in the eutopic (within the uterus in the usual location) endometrium can be associated with changes in ectopic endometrium (endometriosis). Klemmt (2018) is Open Access at <https://www.ncbi.nlm.nih.gov/pmc/articles/PMC5925869/>
201. Martin 2006 – Discusses the use of standards for reporting of diagnostic accuracy (STARD) criteria such as specific and recorded features for a normal or abnormal laparoscopy,

histologic criteria, distance of observation, clinical palpation, exam under anesthesia, intra-operative palpation, and palpation with instrumentation.

202. Attar 2006a and 2006b – Steroidogenic acute regulatory protein (StAR) and aromatase are essential for E2 production and are expressed in endometriosis. There is a positive feedback loop that favors continuous formation of E2 and PGE2 in endometriosis. Also, the eutopic endometrium of patients with endometriosis is capable of aberrantly expressing the enzyme aromatase. See Noble 1996 & 1997, Bulun 1999, Maia 2008, Northnick 2016, Mori 2019.
203. Batt 2007 –There was “no evidence of pelvic endometriosis found at the time of a bilateral oophorectomy” and therefore, Agrawal’s (2006) case of intramedullary endometriosis of the conus medullaris argues 1) for Müllerianosis and against a pelvic source for hematogenous or lymphatic dissemination or 2) for undiagnosed pelvis endometriosis as a source of venous or lymphatic dissemination.
204. Muzii 2007 – Endometriotic tissue covered the inner cyst wall for a surface that varies between 10% and 98% of the entire wall (median value 60%). The mean cyst wall thickness was 1.4 mm. The mean value of maximal depth of endometriosis penetration in the endometrioma wall was 0.6 mm. In 99% of the cases the maximal penetration of the endometriotic tissue was <1.5 mm. The maximum penetration was 2 mm. See Martin 1990b, Martin 1991, and Muzii 2013.
205. Meng 2007 – Menstrual blood-derived stem cells (MenSCs) may contribute to endometriosis. See Chen 2019 for discussion of their use as an alternative source for research and application in regenerative medicine.
206. Griffiths 2007 – Rectovaginal endometriosis was missed at first laparoscopy in 14 (88%) of 16 cases. This is likely due to scarring of the rectum to the posterior uterus creating a pseudo-pouch of Douglas and obscuring the nature of the disease. Griffiths et al. suggest using a rectal probe to determine the degree of obliteration of the pouch of Douglas and increase diagnostic accuracy. Transvaginal sonography and MRI may also be useful in detection of deep endometriosis (Bazot 2005).
207. Possover 2007 – Three cases of isolated sciatic endometriosis with no other evidence of endometriosis. See Possover 2021 for no connection to the peritoneum found in 267 (59%) of 452 patients with sciatic endometriosis, including 36 (54%) of 67 in group 1 with no other evidence of endometriosis.
208. Caserta 2008 – The currently available human data are inadequate to support a conclusion about whether the female reproductive system is adversely affected by exposure to endocrine disruptors (EDCs). EDCs include persistent pollutants, agrochemicals and widespread industrial compounds. Even though potential EDCs may be present in the environment at only very low levels, they may still cause harmful effects, especially when several different compounds act on one target. See Rier 1993, Rier 1995, Rier 2001 (TCDD), Caserta 2008, Smarr 2016, Bruner-Tran 2016, Peinado 2020 (bisphenols), and Rumph 2020 for endocrine disrupting chemicals.
209. Markovic 2008 – Normalization of menstrual pain by young women, their families and health professionals results in delay to diagnosis and long-term exposure to biomedical treatments. The main characteristics of endurance of pain are delayed presentation to a health professional and women’s initial acceptance of health professionals’ advice about the lack of any abnormality. Women who contest the normalization believe they are

experiencing unusually painful periods, reject health professionals' assessments that the cause of pain was psychosomatic rather than pathological, and once diagnosed with endometriosis, while receiving biomedical care, also explored complementary and alternative treatments. Sachedina (2020) adds the missed educational, social and vocational opportunities due to normalization of dysmenorrhea. See Brosens 2013, Shafirir 2018, Knox 2019, Simpson 2021, and Wüest 2023.

210. Nair 2008 – Whole explants of human peritoneum, as well as peritoneal mesothelial cell (PMC) monolayer cultures, demonstrate that whole fragments of proliferative, secretory, and menstrual phase endometrium, as well as cultured endometrial stromal cells (ESC) and endometrial epithelial cells (EEC), adhere to intact PMCs within 1 hour. After attachment to PMCs, endometriotic cells begin to invade PMCs and the basement membrane within 6 hours. By 24 hours, PMC growth over the invaded endometrial cells is well established. These studies strongly suggest that PMC attachment and transmesothelial invasion are the initial steps in the genesis of peritoneal endometriotic lesions. The transition from attachment to invasion likely occurs too rapidly to permit observation of endometrial cell attachment to peritoneal mesothelium in vivo. Disruption of the peritoneal mesothelium, and exposure of the basement membrane, is not required. Invasion by endometrial cells (both ESCs and EECs) is increased through MTGL (modeled basement membrane) when the MTGL is covered by PMCs. These results suggest that PMCs are not a barrier to peritoneal invasion. Rather, PMCs play a significant role in enhancing endometrial invasion into the peritoneal extracellular matrix. PMC-endometrial attachment leads to signal transduction resulting in this altered transcription. Also, ESCs from patients without endometriosis can invade through PMCs.
211. Kodati 2008 – Theory that menstrual, endometrial cells can adhere to peritoneum traumatized by Shigella or Shigella-like microorganisms.
212. Maia 2008 – Aromatase expression is elevated in the eutopic endometrium of patients with endometriosis Oral contraceptives containing gestodene are effective in decreasing that aromatase expression. See Noble 1996 & 1997 1997, Bulun 1999, Attar 2006a, Attar 2006b, Northnick 2016, Mori 2019
213. Olsen 2008 – Olsen found no evidence that PCOS, acne, hirsutism or danazol use was associated with ovarian cancer except for serous borderline tumors that were positively associated with a history of PCOS. The results do not support the hypothesis that androgen-related disorders increase the risk of ovarian cancer. See Risch 1998 and Cottreau 2003.
214. Noël 2008 – Lymph node involvement by endometriosis was observed in 42.3% of deep infiltrating rectosigmoid endometriosis cases and correlated with the size of the lesions, the number of lymph nodes retrieved, and the presence of lymphovascular invasion. Lymphovascular invasion was observed in 36.3% of cases. See Taussig 1906, Sampson 1926, Javert 1949, Noël 2008, Rossini 2016, and Lenz 2020
215. Shakiba 2008 – Early surgery is associated with increased repeat surgery. The chance of repeat surgery at 7-years was 72% at ages 19-29, 56% at ages 30-39, and 24% at ages ≥ 40 . Similar age-related increases are seen in Yeung 2011, Martin 2015, and Fedele 2004a. Also see Moen 2002 for 3% for asymptomatic at tubal ligation and Fedele 2004a for 2% reoperations and 9.7% symptomatic after asymptomatic nodules.

216. Montagna 2008 – There is a correlation between the expression of ERbeta and proinflammatory cytokines both in women with and without endometriosis. The expression of ERalpha correlates with cytokine production selectively in women with endometriosis but not in controls.
217. Gawande 2009 – Checklists make explicit the minimum expected steps in complex processes. Checklists add clarification, consistency and documentation of attention while decreasing memory recall. Good checklists are precise, efficient, to the point, easy to use, and practical. Dangerous issues include “*a kind of silent disengagement, a consequence of specialized technicians sticking narrowly to their domains. "That's not my problem" is possibly the worse thing people can think.*” Contrast with Law 2004 and Schuurman 2023.
218. Guo 2009 – There is a need for identification of prognostic biomarkers for recurrence. See Hughes 2015 for markers of diagnosis, response to treatment, and disease progression and Zhang 2018 for prognosis marker.
219. Mier-Cabrera 2009 – A high antioxidant diet at 150% of the suggested daily intake of vitamin A (1050 microg retinol equivalents), 660% of the recommended daily intake (RDI) of vitamin C (500 mg) and 133% of the RDI of vitamin E (20 mg) was associated with diminished peripheral oxidative stress markers and enhanced antioxidant markers in women with endometriosis. See Mier-Cabrera 2009 Nishihara 2018 & Samimi 2019
220. Burney 2009 – MicroRNAs (miRNAs) have significant regulatory influence on the expression of target genes involved in both physiologic and pathologic conditions. There is incomplete transitioning from proliferative to secretory phase endometrium in women with endometriosis. Early secretory endometrium (ESE) from women with endometriosis is characterized by a miRNA expression profile that differs from that of healthy ESE. Among the miRNAs underexpressed in ESE in the setting of endometriosis are members of the miR-9 and miR-34 families. See Ohlsson Teague 2009, Saare 2017, Agrawal 2018, Hu 2019
221. Ohlsson Teague 2009 – MicroRNAs (miRNAs) and their cognate mRNA target sequences appear to constitute pathways that promote endometriosis. Functional analysis suggested that the 673 miRNA targets constitute molecular pathways previously associated with endometriosis, including c-Jun, CREB-binding protein, protein kinase B (Akt), and cyclin D1 (CCND1) signaling. These pathways appeared to be regulated both transcriptionally as well as by miRNAs at posttranscriptional level. See Burney 2009, Agrawal 2018, Hu 2019
222. Novella-Maestre 2009 – Dopamine agonist administration causes a reduction in endometrial implants by decreasing angiogenesis in experimentally induced endometriosis. Hum Reprod. 2009;24(5):1025–1035. doi:10.1093/humrep/den499. Dopamine agonist (cabergoline) decreases neoangiogenesis. Reviewed in Laganà 2020.
223. Fagervold 2009 – After menopause, 96.9% were free from pain at 15 years.
224. Khan 2010 – Bacterial endotoxins such as lipopolysaccharide in the pelvis across the phases of the menstrual cycle. This lipopolysaccharide derived from higher colony formation of Escherichia coli in menstrual blood may promote the growth of endometriosis after its binding with toll-like receptor 4 (TLR4). Also see Khan 2016 for bacterial contamination hypothesis; Koninckx 2019b for a review of microbiome, infection, and bacterial endotoxin; and Leonardi 2020a for a review of the microbiome.
225. Chapron 2010 – Among 15 patients with non-operated associated asymptomatic posterior DIE lesions, a second surgical procedure indicated for pain symptoms was necessary for

- only one patient (6.7%). See Evers 1994, Thomas 1996, Fedele et al. 2004b, Evers 2005, Martin 2005, Chapron 2010, Abrão 2015 and Netter et al. 2019.
226. Signorile 2010 & 2012 – Fetal tissue compatible with endometriosis on H&E, H&VG and immunohistochemistry stains (CD10, Era, CA 125, cytokeratin 7, vimentin, and desmin) was found in the rectovaginal septum, proximity of the Douglas pouch, and the mesenchymal tissue close to the posterior wall of the uterus. This is the same anatomic area studied by Koninckx (1992) with Type III being the most suggestive of a congenital rest and Donnez (2001) on metaplasia from Müllerian remnants. See Sumathi 2002 and Potlog-Nahari 2004 for CD10.
227. Adamson 2010 – The Endometriosis Fertility Index is the only validated tool to determine fertility after surgery. Fertility rates after endometriosis surgery are based 50% of the surgical findings and 50% on history. [https://www.fertstert.org/article/S0015-0282\(09\)03714-5/fulltext](https://www.fertstert.org/article/S0015-0282(09)03714-5/fulltext)
228. Surrey 2010 – Add back therapy adds to patient acceptance & safety of GnRH therapy.
229. Ferrero 2010 – The symptoms of endometriosis can be subtle with only 1.4% having a history of endometriosis and an additional 2.4% (62% increase) based on a focused search for four pain symptoms: pelvic or uterine pain during menstruation, genital pain on deep penetration, pelvic pain for more than six months, painful bowel movements. If one of four symptoms was present, they were referred for gynecologic exam, transvaginal sonogram, and possible MRI. See Ling 1999 for 82% if seen in tertiary care with chronic pain non-responsive to NSAIDs.
230. Umezawa 2010 – Prenatal in utero and postnatal diesel exhaust exposure is toxic and enhances the activation of mast cells and prolongs the persistence of collagen fibers in the induced rat model of endometriosis. See Upson 2015 and Ottolina 2020 for human in utero and postnatal exposures.
231. Barton-Smith 2010 – Vaporization showed better improvement for deep endometriosis but similar improvement for superficial disease when compared with excision. Although vaporization appears reasonable for superficial lesions, excision is better for deep lesions.
232. Batt 2011a – Dr. Batt’s book “*A History of Endometriosis*” presents the great leap forward that occurred from 1860 to 1946 from a statistical grouping of signs and symptoms through treating symptoms to treating diseases. The pathophysiology of endometriosis was initially defined in an era when surgery was the only treatment. <https://www.springer.com/us/book/9780857295842>
233. Coccia 2011 – Menopause occurred earlier in women who had bilateral cystectomy than those with unilateral endometrioma (42.1 versus 47.1 years of age). Primary ovarian insufficiency was more common after bilateral cystectomy. The relationship between the preoperative ovarian endometriomas total diameter and menopausal age was significant in case of surgery for bilateral endometriomas.
234. Acién 2012 – Accessory and cavitated uterine masses (ACUM) are non-inflammatory, organoid examples of how Müllerian remnants can appear. These may rarely have accessory tubes resulting in pregnancy (Alkhateeb 2005, Branquinho 2012, Dadhwal 2017). Juvenile cystic adenomas (JCA) may be a form of ACUM or an acquired form of adenomyosis. See Arya 2021 and Martin 2021. These may also be a form of endomyometrioma that can also occur in males. See González 2014 and La Greca 2021.

235. Redwine 2012, Nezhat 2012 – Clinical descriptions suggesting the presence of endometriosis were found in the oldest known medical text the Medical Papyrus (1825 BC) or Egyptian concepts (1855 BC). These are introduced in [Redwine 2012](#) and [Nezhat 2012](#).
236. Kubota 2012 – Royal jelly changes the phenotype from a genetically identical female honeybee to a fertile queen possibly by erasing global DNA methylation. (Farahani 2021) It also has antioxidant, anti-tumoral, anti-inflammatory, analgesic, and neuronal protective effects. It can decrease the mean lesion size and the mean pain score in the late phase in rats. (Farahani 2021) Also see Wu 2006, Iszawa 2008, Iszawa 2011, Koukoura 2016, Guo 2020b and Esfandiari 2021a.
237. Batt 2013, Laganà 2017 – Müllerianosis is an organoid remnant of Müllerian tissue in the native area of embryologic Müllerian development. Remnants include adenomyosis, endometriosis, endosalpingiosis, and endocervicosis. The four developmental Müllerian diseases complement the four acquired Müllerian diseases. See Batt 1985. Batt did not discuss organoid remnants such as accessory and cavitated uterine masses (Acién 2012).
238. Batt 2013 – Hamartoma is a neoplastic Müllerian growth in the native Müllerian area.
239. Brosens 2013 – Endometriosis is a progressive disease. A delay of several years before diagnosis is associated with advanced endometriosis in adolescents. Brosens suggests early ultrasound and endoscopy for diagnosis and therapy. This tertiary care study of patients seen after years of delay for pelvic pain and pelvic masses can be contrasted with Knox 2019 that followed adolescents with dysmenorrhea for an average of 10.2 years during which time 18.6% were diagnosed with endometriosis. All of Knox’s cases of endometriosis were mild. See Markovic 2008, Brosens 2013, Shafir 2018, Sachedina 2020, Simpson 2021, and Wüest 2023.
240. Raposo 2013 – Extracellular vesicles involved in intercellular communication (signaling)
241. Zamecnik 2013 – Endometriosis occurring in paratesticular mesothelial cyst in a man had endometrioid epithelial cells expressing a mesothelial type that favored metaplastic pathogenesis of the lesion. Reviewed in Rei 2018.
242. Muzii 2013 – Ovarian damage can be due to both endometriosis and surgery.
243. Gazvani 2013 – *C. albicans* may contribute to the pathogenesis of endometriosis by modulating cytokine production. See the “[Subtle Inflammatory Lesions](#)” section.
244. Young 2013 – Differential expression of peritoneal mesothelial adhesion factors, including loss of tight junctions, may provide ectopic endometrial cell attachment sites for the establishment of endometriosis lesions. Epithelial-to-mesenchymal transition of peritoneal mesothelial cells may also lead to an increase in lesion invasion and formation of fibrotic tissue in and around the lesion. Peritoneal mesothelium may produce MMPs increasing local tissue remodeling. Peritoneal immune scavenging function may be lowered in women with endometriosis.
245. Batt 2014 – Concluded that the retrocervical location of rectovaginal endometriosis implied that this is the retrocervical septum. See Adamyan 1993 and Martin 2001 for retrocevic position.
246. Chaudhury 2013 – Cerium oxide nanoparticles (nanoceria) have unique free radicals (specifically superoxide radical and hydrogen peroxide) scavenging property in biological system. Free radicals have been implemented in the pathogenesis of endometriosis. Cerium

- oxide nanoparticles (nanoceria) successfully treat endometriosis in rodents by decreasing oxidative stress and inhibiting angiogenesis. Moreover, nanoceria also protect oocytes from endometriosis-related adverse effects, which is critical for successful pregnancy. See Moses 2021 for delivery of drugs and imaging agents to disease sites in rodents.
247. Evers 2013 – In randomized clinical trials, with laparoscopies before and after a period without treatment, there was a 42% spontaneous regression rate. In addition, 29% remained stable and 29% progressed. Overall, 71% did not progress between laparoscopies. There was no way of predicting who would progress and who would not.
 248. Becker 2014 – Harmonization to six surgical phenotypes (clear, red, white, blue/black, brown, and vascular) are discussed. Becker is an open access at <https://www.ncbi.nlm.nih.gov/pmc/articles/PMC4230690/>
 249. Kobayashi 2014 – Infectious precursors or infectious induction (initiation or activation) of endometriosis. See the “[Subtle Inflammatory Lesions](#)” section and Kobayashi 2023a & b.
 250. Gargett et al. 2014, Brosens 2015 – Perinatal retrograde dissemination is like Sampson but suggests an earlier occurrence shortly after birth.
 251. Forte 2014 – Chromosomal anomalies and instability can alter gene expression.
 252. Khan 2014 – Occult non-recognized endometriosis found in 15.2 % of women with visible endometriosis (15.2%) and 6.4% of controls (6.4%). There are three patterns of occult microscopic endometriosis based on patterns of Ber-EP4 (epithelial cell marker), CD10 (stromal cell marker), Calretinin (mesothelial cell marker), estrogen/progesterone receptors (ER/PR) and Ki-67 (cell proliferation marker). See the “[Subtle Inflammatory Lesions](#)” section. Also see Martin 1989a for increase with awareness of subtle appearances, Khan 2010 for endotoxins, Hopton 2014 for “near-contact” laparoscopy, Khan 2016 for crosstalk between inflammation and ovarian steroids or the stress reaction, and Leonardi 2020a for a review of the microbiome.
 253. Hopton & Redwine 2014 – Khan (2014) confirms that most (84.8%) women with endometriosis do not have occult endometriosis.
 254. Signorile 2014 – Anti-müllerian hormone (AMH) in native endometrium acts in a paracrine fashion negatively regulating cellular viability. Treatment of endometriosis with AMH decreases growth.
 255. Parra-Herran 2014 – There is a high sensitivity and specificity of interferon-inducible transmembrane protein 1 (IFITM1) comparing normal and sarcomatous endometrial samples with leiomyoma, usual type, and cellular leiomyoma. See Sun 2019. CD10 expression is not specific to endometrial stromal cells and is found in other cells such as vascular endothelial cells, uterine fibroids, leiomyosarcoma. hematopoietic, renal tubular and smooth muscle cells. IFITM1 is more specific for endometrial stromal cells than CD10.
 256. Bobek 2014 – The occurrence of circulating endometrial cells (CECs) as small as 8 μ in peripheral blood (PB) in evidence of an active endometrial disease and may be useful as a marker for endometriosis. See Pospisilova 2019 for increased sensitivity of tests for CECs. Also see Sampson 1918, Sampson 1927b, Chen 2017, Samani 2017, Pospisilova 2019, Vallvé-Juanico 2019, and Kiss 2020.
 257. Khan 2014 – Occult non-recognized endometriosis found in 15.2 % of women with visible endometriosis (15.2%) and 6.4% of controls (6.4%). There are three patterns of occult

- microscopic endometriosis based on patterns of Ber-EP4 (epithelial cell marker), CD10 (stromal cell marker), Calretinin (mesothelial cell marker), estrogen/progesterone receptors (ER/PR) and Ki-67 (cell proliferation marker). Also see Khan 2010 for endotoxins, Khan 2016 for crosstalk between inflammation and ovarian steroids or the stress reaction, and Leonardi 2020a for a review of the microbiome.
258. Leconte 2014 – Chemokines and growth factors are found in elevated levels in the peritoneal fluid of women with endometriosis, and these may contribute to the proliferation and implantation of endometriotic implants and neoangiogenesis in the peritoneal cavity. CXCR-4, an alpha-chemokine receptor, and its target chemokine protein CXCL12 have chemotactic activity for lymphocytes produced in the inflammatory peritoneal environment. CXCL12 is higher in DIE peritoneal fluids than in controls. CXCR4 was downregulated in deep infiltrating endometriotic stromal cells. The CXCL12-CXCR4 axis plays a role in the attraction of eutopic endometrial cells into the peritoneal cavity, and the downregulation of CXCR4 in resident endometriotic cells could cause their arrest in situ.
259. Tosh 2014 – Tosh and Slack (2002) and Tosh and Horb (2014) discussed the versatility of adult stem cells and possibly differentiated cells. They discuss metaplasia as both the conversion of one cell type to another including conversions between tissue-specific stem cells and theoretically transdifferentiation or the conversion of differentiated cell types to another cell type. They concluded that some past examples of transdifferentiation (e.g., cervical squamous metaplasia seen as transdifferentiation would be mature columnar cells changing into mature squamous cells) may have been artifacts. See Liu 2017 for fibroblast-to-myofibroblast transdifferentiation and different lesional microenvironments. See Tosh 2002 and Tosh 2014 for phenotypic metaplasia compared with transdifferentiation. See Que 2019 for recent concepts of metaplasia, paligenosis, differentiation, transdifferentiation and transcommitment.
260. da Silva 2014 – Inflammation and angiogenesis markers are in the menstrual blood of women with endometriosis and controls. Macrophage and leukocyte activities were significantly greater in menstrual blood of women with endometriosis than in their peripheral blood, reflecting increased local inflammatory activity. See Noyes 1950 for endometrial inflammation days 25 to 5. See Khan 2010 Khan 2016, and Koninckx 2019b for Escherichia coli bacterial endotoxins in menstrual blood. See Merrill 1966 for “Merrill factor,” a metaplasia-inducing substance such as estrogen and a factor liberated from degenerating menstrual endometrium.
261. Fuentes 2014 – 589 (5.8%) of 10,156 fertile women in 16 tubal ligation studies had asymptomatic or relatively asymptomatic endometriosis. Eight studies that clarified “asymptomatic” endometriosis had a 16.9% occurrence.
262. Yuan 2014 – Yuan et al. (2014) found two patterns of expression of the biomarkers MO3 and DMBT1 in fallopian tube, endometrium, and ovarian endometriosis. The findings suggested that 60% of ovarian endometriosis was derived from the fallopian tube while 40% may be of endometrial origin. See Wang 2023.
263. Batt 2015 – Ron Batt’s 2015 presentation on the four forms of Müllerianosis—embryonic endometriosis, adenomyosis, endosalpingiosis, and endocervicosis—is at <https://www.endofound.org/video/ronald-batt-md-mullerianosis-embryonic-endometriosis-adenomyosis-endosalpingiosis-and-endocervicosis/1254>

264. Sugamata 2015 – Leukotriene receptor antagonist (LTR-A), an anti-allergic drug, is associated with apoptotic fibroblasts and degeneration of collagen fibers and may this decrease the transition to deep infiltrating endometriotic disease.
<http://dx.doi.org/10.4236/ojog.2015.56045>
265. Abrão 2015 – In women with deep endometriosis, surgery is the therapy of choice for symptomatic patients when deep lesions do not improve with medical treatment. They determined that “a woman with severe pain, defined by a visual analog scale score of ≥ 7 , benefited from surgery and described a surgical treatment algorithm based on the depth and size of a rectal disease.” Women with a VAS ≤ 6 and no increase in pain or size are treated medically. Some patients with extensive rectosigmoid endometriosis can be almost asymptomatic.
266. Guo 2015 – Repeated tissue injury and repair (ReTIAR) due to cyclic bleeding in endometriosis. Also see Canis 2016, Canis 2017
267. Laux-Biehlmann 2015 – Pain due to activation of peripheral nerve endings in response to retrograde and extra-uterine menstruation
268. Deans 2015 – Deans and Maggert discuss epigenetics definitions that require heritability as contrasted those definitions that are more concerned with environmentally mediated phenotypes and plasticity. They concluded that the latter definition is of gene regulation rather than epigenetics and note that definition is more commonly used in such fields as ecology, physiology, and psychology. Those in the field of genetics are more commonly concerned about inter-generational heritability. Understanding the differences between the definitions is important in interpreting the mechanisms. Most studies of endometriosis fit the gene regulation definition rather than a heritable definition.
269. Upson 2015 – This analysis of 310 women in western Washington State observed that women who were regularly fed soy formula as infants had over twice the risk of endometriosis compared to unexposed women. There was also an increased endometriosis risk with prematurity and maternal use of diethylstilbestrol (DES, a synthetic estrogen). This is confirmed in Ottolina 2020. See Karnaky 1948 and Karnaky 1969 for mid-1900s use of DES to treat endometriosis.
270. Hufnagel 2015 – Hufnagel et al. reviews the role of stem cells in the etiology and pathophysiology of endometriosis. See Fernandez 1995 for endometriosis, Starzinski-Powitz 2001 & 2003 for differentiation, Meng 2007 & Chen 2019 for menstrual blood-derived stem cells, Hufnagel 2015 and Wang 2020 for BMD stem cells in endometriosis, Miyazaki 2018 for pluripotent stem cell, and Yin 2019 for CD34 (bone marrow derived stem cell marker) in endometrium. Search this file for “stem cell” for others. NOTE: Bone marrow-derived stem cells may engraft and “differentiate into multiple cell types including endothelial, muscle, stromal, and epithelial cells.” They are not specific for endometriosis. (Mamillapalli 2021) See Fernandez 1995 for the possibility that the BMD data is artifactual.
271. Hughes 2015 – Markers for diagnosis, response to treatment, and disease progression are needed. See Guo 2009 for recurrence marker and Zhang 2018 for prognosis marker.
272. Simon 2015 – Immune response changes through life, including adolescence and ends with the decline in old age. See Brenhouse 2016.
273. Li 2015 – Li et al. reviewed stem and epithelial cells of 1 μ to 30 μ . Stem cells smaller than 10 μ can pass through the pulmonary capillaries. See Wirtz 2011 for 10 μ capillaries.

274. Brenhouse 2016 – Adolescence is a unique period of neuroimmune development with brain and immune maturation. Our immune system communicates with our nervous system to regulate responses to the environment.
- There are understudied components of neuro-immune interactions during adolescence. Synaptic pruning, neurite outgrowth, and neurotransmitter release during adolescence all regulate-and are regulated by-immune signals, which occur via blood-brain barrier dynamics and glial activity.
275. Liang 2016, 2018, 2019 – Estrogen plays a role in maintaining balance of nerve interaction and can also be part of dysfunction of nerve interaction and the pro-endometriotic niche in endometriosis. Blocking the molecular components derived from the endometriotic lesion, suppressing the recruitment and activity of immunosuppressive cells, inhibiting the mobilization of BMSC and constricting the angiogenesis process may represent potential approaches to preventing the progression of endometriosis.
276. Huang 2016 – Dioxin-like CB126, but not non-dioxin-like CB153, significantly enhanced 17 β -estradiol (E2) biosynthesis in a dose-dependent manner. CB126 triggered the inflammatory response by directly stimulating the secretion of inflammatory factors and indirectly reducing the level of lipoxin. A PCB-treated endometriosis mouse model confirmed that CB126 rather than CB153 increased the levels of both E2 and inflammatory factors in peritoneal fluid and promoted the development of endometriotic lesions. These effects were mediated by the AhR receptor
277. Canis 2016, Canis 2017 – Endometriosis may not be a chronic, recurrent disease. The extent or the surgical phenotype of the disease may be related to the initial anatomic localization, type, and severity of the trauma. Various traumas including delivery, uterine curettage or incision, intraperitoneal hemorrhage, or occult pelvic inflammatory diseases could be involved. The healing process, particularly growth factors and the associated estrogen production, may facilitate the implantation and the growth of ectopic endometrial cells. Also see Guo 2015
278. Koninckx 2016 – There are four phenotypic types of endometriosis: subtle, typical, cystic ovarian, and deep infiltrating.
279. Nerune 2016 – Persistent Müllerian Duct Syndrome (PMDS), a rare form of internal male pseudohermaphroditism in men. This includes references from 2009. Also, see Melicow 1967 and Olikier 1971 for 46 XY males.
280. Khan 2016 – The bacterial contamination hypothesis reviews the lipopolysaccharide regulation of the pro-inflammatory response in the pelvis and growth of endometriosis via the LPS/TLR4 cascade. Menstrual blood was highly contaminated with *Escherichia coli* and the endometrial samples were colonized with other microbes. Crosstalk between inflammation and ovarian steroids or the stress reaction was also observed in the pelvis. GnRHa treatment may worsen intrauterine microbial colonization, with the consequent occurrence of endometritis in women with endometriosis.
281. Pavone 2016 – Retinoid analogs may induce apoptosis in endometriotic cells and tissues, thereby reducing disease burden. See Halme 1988 & Gebel 1998.
282. Tiboni 2016 – Animal defects on therapeutic or lower levels doses of aromatase inhibitors include skeletal anomalies, abnormal head morphology, increased anogenital distance in female fetuses, urinary tract system anomalies, and placental enlargement.

283. Bruner-Tran 2016 – Bruner-Tran, et al., investigated heritable, germline, epigenetic changes such as reduced progesterone sensitivity, in mice after exposure to the environmental endocrine disruptor 2,3,7,8-tetrachlorodibenzo-p-dioxin (TCDD) and demonstrated a transgenerational occurrence. They could not determine if those changes lead to the development of endometriosis or were a consequence of the inflammatory nature of the disease. See Deans 2015 for clarification of definitions of “*epigenetics*.” See Rier 1993, Rier 1995, Rier 2001 (TCDD), Caserta 2008, Smarr 2016, Bruner-Tran 2016, Peinado 2020 (bisphenols), and Rumph 2020 for endocrine disrupting chemicals. See Umezawa 2011 for diesel fuel toxicology; Huang 2016 for comparison of dioxin-like and non-dioxin-like polychlorinated biphenyls (PCBs); Liang 2016, 2018, & 2019 for estrogen interactions; Holder 2014, Simon 2015, and Brenhouse 2016 for neuroimmune maturation; and Hall 2023 for cadmium.
284. Smarr 2016 – Endocrine disrupting chemicals (EDCs), such as 2,3,7,8-tetrachlorodibenzo-p-dioxin (TCDD), dioxin-like polychlorinated biphenyls (PCBs), organochlorine pesticides (OCPs), polybrominated diphenyl ethers (PBDEs), perfluoroalkyl and polyfluoroalkyl substances (PFAAs), and select metals may be involved in the development and severity of endometriosis. See Rier 1993, Rier 1995, Rier 2001 (TCDD), Caserta 2008, Smarr 2016, Bruner-Tran 2016, Peinado 2020 (bisphenols), and Rumph 2020 for endocrine disrupting chemicals.
285. Badescu 2016 and 2018 – Badescu et al. documented histologically positive but clinically unrecognized bowel lesions in all 26 patients (100%) studied. The lesions were up to 5 cm from the primary nodule and were 1 mm to 1 cm in size. Four patients (15%) had nodules at the margins.
286. Koukoura 2016 – Aberrant DNA methylation represents a possible mechanism responsible for endometriosis, linking gene expression alterations observed in endometriosis with hormonal and environmental factors. Endometriosis may partially be due to selective epigenetic deregulations influenced by extrinsic factors and aberrant hormonal, immunologic and inflammatory factors. Whether these molecular changes represent the cause or merely the consequence of the disease remains to be known. Also see Wu 2006, Iszawa 2008, Iszawa 2011, Kubota 2012, Turco 2017, Boretto 2019, Guo 2020b, Farahani 2021, Esfandiari 2021a, and Esfandiari 2021b.
287. Grandi 2016 – The inflammatory cytokines tumor necrosis factor α (TNF α) and interleukin 1 β (IL-1 β) reduce the expression of progesterone receptors and increased the expression of the glucocorticoid receptors in the endometrial stromal cells. This could contribute to progesterone resistance. See Grandi 2016, Flores 2018, Likes 2019, Marquardt 2019, Yilmaz 2019, Donnez 2021, Bulun 2021, Zhang 2023 for progesterone resistance.
288. Long 2016 – Angiogenesis and growth of endometriosis lesions increases when the adrenergic signaling is increased by surgery in a mouse. This is stopped with β -blockade using propranolol, a medicine that can be used for anxiety.
289. Rossini 2016 – Seventy (50%) 140 cases of colorectal resection had lymph node involvement. The presence of positive nodes was not associated with intestinal stenosis, histopathological infiltration, depth of infiltration or intestinal recurrence. See Taussig 1906, Sampson 1926, Javert 1949, Noël 2008, Rossini 2016, and Lenz 2020.

290. Hirsch 2016 – Hirsch, Duffy, et al. (2016) concluded that variation in outcome reporting within published endometriosis trials prohibits comparison, combination, and synthesis of data. This limits the usefulness of research to inform clinical practice, enhance patient care, and improve patient outcomes. In the absence of a core outcome set for endometriosis we recommend the use of the 3 most common pain (dysmenorrhea, dyspareunia, and pelvic pain) and subfertility (pregnancy, miscarriage, and live birth) outcomes. International consensus among stakeholders is needed to establish a core outcome set for endometriosis trials.
291. As-Sanie 2016 – Endo brain may be due to the altered brain chemistry and function that is seen in chronic pain. Endo brain is the fog, inability to remember words, forgetting the middle of sentences, and inability to concentrate related to chronic fatigue and stress. These happen to everyone but increase when you have no energy because of the pain of endometriosis. In contrast to women with relatively asymptomatic endometriosis, women with endometriosis-associated chronic pelvic pain (CPP) exhibit nonpelvic hyperalgesia and decreased gray matter volume in key neural pain processing regions.
292. Laganà 2017 – “Unus pro omnibus, omnes pro uno” is a combination of many concepts into a process that begins during embryogenesis. Components include Hox (homeobox) genes, Wnt (wingless) genes, Müllerian derivatives and remnants, genital ridge leakage during organogenesis, human embryonic stem cells (hEmSC), endometrial stem progenitor cells (hESP), stem/progenitor cells residing in adult uterus, mesenchymal stem cells from bone marrow, and embryonic ectopic implantation. Updated at Laganà 2018
293. Gordts 2017 – Whether the original cell comes from the endometrium, endometrial pale cells, other stem cells, bone marrow cells, embryonic cells, neonatal cells, adult cells or another source of endometrial or potentially endometrial cells is not as important as the genetic and epigenetic changes associated with the specific phenotypes of endometriosis. See Deans 2015 for clarification of definition of “*epigenetics*.” See Wang 2020 stem cells. NOTE: Bone marrow–derived stem cells may engraft and “*differentiate into multiple cell types including endothelial, muscle, stromal, and epithelial cells.*” They are not specific for endometriosis. (Mamillapalli 2021) See Fernandez 1995 for the possibility that the BMD data is artifactual.
294. Dorien 2017 – Dorien et al. confirms the previous literature on the presence of endometrial cells in the peritoneal fluid of most women using with primary antibodies against epithelial cell adhesion molecule (Ep-CAM; endometrial epithelial cells), CD10 (endometrial stromal cells), prekeratin (epithelial/mesothelial cells), vimentin (endometrial/mesothelial/immune cells), calretinin (mesothelial cells), and CD68 (macrophages). They also reviewed the literature on the possibilities of involvement of endometrial stem cells rather than endometrial epithelial/stromal cells, involvement of bone marrow stem cells, induction (initiation or activation) by other substances in menstrual fluid, and the finding being the consequence rather than the cause of endometriosis. See Koninckx 1980 for unruptured luteinized follicle and Halme 1983 & 1984 for hormonal or immunologic factors. See Wang 2020.
295. Liu 2017 – Epithelial-mesenchymal transition, fibroblast-to-myofibroblast transdifferentiation, smooth muscle metaplasia, fibrosis, vascularity, hormonal receptors, and proteins involved in epigenetic modifications. Differences may result from the different

- lesional microenvironments. See Que 2019 for recent concepts of metaplasia, paligenosis, differentiation, transdifferentiation and transcommitment.
296. Makiyan 2017 – Congenital endodermal primordial germ cells remnants are speculated as the embryological source of endometrium and endometriosis. This contradicted the generally accepted Müllerian theory that the endometrium, uterus, tubes, and upper vagina are mesodermal Müllerian derivatives.
297. Anglesio 2017 – Cancer-associated driver mutations can be present in deep infiltrating endometriosis. See Guo 2018b, Lac 2019, Bulun 2019, Guo 2020a. See Suda 2020 for genetic somatic copy number variations.
298. Aoyagi 2017– Kistner proposed a state of “pseudopregnancy” to reproduce the improvement noted in endometriosis during and after pregnancy. He postulated that decidualization results in necrosis and elimination of early, superficial endometriotic implants. Also, see Kistner 1958 & Klemmt 2006
299. Kohl Schwartz 2017 – Mild endometriosis, as in superficial lesions, is related to a great extent to an inflammatory disorder, possibly leading to defective folliculogenesis, fertilization, or implantation, presenting an increased risk of miscarriage. See Berlanda 2021 for increased obstetric risks of preterm delivery, neonatal admission to intensive care unit, placenta previa and cesarean delivery.
300. (18) (PDF) Impact of endometriosis on obstetric outcome after natural conception: a multicenter Italian study Endometriosis Treatment Italian Club (ETIC). Available from: https://www.researchgate.net/publication/355162941_Impact_of_endometriosis_on_obstetric_outcome_after_natural_conception_a_multicenter_Italian_study_Endometriosis_Treatment_Italian_Club_ETIC (accessed Oct 14, 2021).
301. Parasar 2017 – Mouse embryonic stem cells (mESCs) express both glandular (CD9) and stromal (CD13) markers of human endometrium, suggestive of an endometrial precursor cell population. See Fernandez 1995 for endometriosis, Starzinski-Powitz 2001 & 2003 for differentiation, Meng 2007 & Chen 2019 for menstrual blood-derived stem cells, Hufnagel 2015 and Wang 2020 for BMD stem cells in endometriosis, Miyazaki 2018 for pluripotent stem cell, and Yin 2019 for CD34 (bone marrow derived stem cell marker) in endometrium. Search file for “stem cell” for others.
302. Gruber-Dujardin 2017 – Gruber-Dujardin et al. characterized spontaneous endometriosis in rhesus macaques. Immunohistochemical coexpression of epithelial and mesenchymal markers (CK, vimentin, sometimes together with SMA and desmin), most obvious in poorly differentiated endometriosis and resembling distinct mesothelial cell properties, are associated with induced differentiation of peritoneal cells into endometrial tissue and support the theory of coelomic metaplasia. See Que 2019 for recent concepts of metaplasia, paligenosis, differentiation, transdifferentiation and transcommitment.
303. Burlev & Ilyasova 2017, Burlev, et al. 2018 – Burlev, et al. concluded that serum and eutopic endometrial vasoactive intestinal peptide (VIP) can be used to assess pain and neuroangiogenesis in endometriosis. They found elevated vasoactive intestinal peptide (VIP) transcript and protein levels in serum, eutopic endometrium, and endometriosis were associated with chronic pain indicated an elevated inflammation in the pelvic microenvironment. See Novella-Maestre 2009 and Laganà 2020.

304. Munrós 2017, Munrós 2019 – A generalized inflammatory state is suggested by the elevated total circulating microparticle levels in patients with deep infiltrating endometriosis. Those levels increase after excisional surgery compared with CO2 laser vaporization. Also see Rock 1981, Donnez 1984, Long 2018, Hu & Taylor 2019, Guo and Martin 2019.
305. Saare 2017 – The limited overlap between the proposed disease-related miRNAs could be due to the heterogeneity in tissue composition, as some studies have compared highly heterogeneous whole-lesion biopsies with endometrial tissue, some have compared the endometrium from patients and controls, and some have used pure cell fractions isolated from lesions and endometrium. This review concludes that the experimental design should be changed and should move from highly heterogeneous tissues to studies using specific cell populations. See Ohlsson Teague 2009, Burney 2009, Agrawal 2018
306. Power 2017 – Review of microbiome interactions. See the “[Subtle Inflammatory Lesions](#)” section of this document.
307. Samani 2017 – Samani et al. demonstrated that endometriosis-derived cells are capable of migration (micrometastasis) to extrapelvic organs including the lung, spleen, liver, and brain in a mouse model. They speculate that some of the non-pelvic pain, fatigue, malaise, eating disorders, anthropometric variation, endocrine and metabolic dysfunction, immunologic defects, and sociopsychological issues may be due to undiagnosed, distal cellular infiltration with endometriosis. See Li 2018 for hematogenous dissemination of mesenchymal stem cells from endometriosis. NOTE: Bone marrow–derived stem cells may engraft and “*differentiate into multiple cell types including endothelial, muscle, stromal, and epithelial cells.*” They are not specific for endometriosis. (Mamillapalli 2021) See Fernandez 1995 for the possibility that the BMD data is artifactual.
308. Surrey 2017 – GnRHa before embryo transfer in freeze-all cycles resulted in implantation and ongoing pregnancy rates that were similar among the three groups and compared favorably to Group 4 (all transfers after comprehensive chromosomal screening (CCS) for descriptive comparison only). A non-significant trend towards improved outcomes was noted in Group 1 (+ CCS +endometriosis) Prolonged GnRHa after freeze-all in these patients avoids excessive ovarian suppression and results in excellent outcomes.
309. Turco 2017 – Human adult stem-cell-derived organoid cultures can be used to generate three-dimensional cultures of normal and decidualized human endometrium. These organoids expand long-term, are genetically stable and differentiate following treatment with reproductive hormones. Single cells from both endometrium and decidua can generate a fully functional organoid. Transcript analysis confirmed great similarity between organoids and the primary tissue of origin. Although limited and having no stroma, blood vessels, innervation, and immune cells, these may be useful in studying endometriosis etiology, modeling, and therapeutics. See Boretto 2019 for organoids from endometriosis.
310. Chen 2017 – The circulating endometrial cell hypothesis is that endometrial cells enter the circulation, escape immune attack, survive, and transfer for ectopic implantation in a suitable microenvironment and develop into endometriosis. See Holder 2014, Simon 2015, and Brenhouse 2016 for neuroimmune maturation. See Sampson 1918, Sampson 1927b, Bobek 2014, Pospisilova 2019, Vallvé-Juanico 2019 and Kiss 2020.
311. Lessey 2017 – Chronic inflammation is disruptive to endometrial receptivity and promotes progesterone resistance and estrogen dominance through aberrant cell signaling pathways

- and reduced expression of key homeostatic proteins. See Lessey 1995, Grandi 2016, Likes 2019, Lessey 2017, and Vargas 2022.
312. Yang 2017 – Autophagy, which is known as the non-apoptotic form of programmed cell death induced by a large number of intracellular/extracellular stimuli, is the major cellular pathway for the degradation of long-lived proteins and cytoplasmic organelles in eukaryotic cells. See Gebel 1998, Matsuzaki 2018, Foster 2018, Luo 2018, Matsuzaki 2018, Sui 2018.
313. Kotlyar 2017 – The administration of disease-modifying anti-rheumatic drugs (DMARDs) for at least 6 weeks before surgery is associated with decreased opioid usage among women with endometriosis. Immunomodulators that may be useful in decreasing the elevated level of inflammation in endometriosis include DMARDs, cytokines, mTOR inhibitors, nucleotide analogs, and various other small molecules. See Kotlyar 2019.
314. Arévalo 2017 – A mushroom cap appearance is seen with deep rectosigmoid endometriosis and may be useful in planning surgery.
315. Bendifallah 2017 – The cumulative live birth rates at the first ART (ICSI-IVF) cycle in the first-line surgery group compared with the first-line ART were, respectively, 32.7% versus 13.0%; at the second cycle, 58.9% versus 24.8%; and at the third cycle, 70.6% versus 54.9%. The cumulative live birth rates were significantly higher for women who underwent first-line surgery followed by ART compared with first-line ART in the subset of women with good prognosis (age \leq 35 years and AMH \geq 2 ng/mL and no adenomyosis) and women with AMH serum level $<$ 2 ng/mL.
316. Agrawal 2018 – Despite numerous studies on circulating miRNAs in endometriosis, no single miRNA or any panel of them seems to meet the criteria of a diagnostic biomarker. The disagreement between the various studies upholds the demand of larger, well-controlled systematic validation studies with uniformity in the research approaches and involving diverse populations. See Ohlsson Teague 2009, Burney 2009, Saare 2017.
PMC Open Access: <https://www.ncbi.nlm.nih.gov/pmc/articles/PMC5855821/>
317. Viganò 2018 – Endometriosis should be defined as a fibrotic condition with endometrial stroma and epithelium. See Sampson 1921, Sampson 1927a, Koninckx 1994, Koninckx 1999, Sugamata 2015, Guo 2018a, and Koninckx 2019.
318. Guo 2018b – The six driver genes reported to be mutated in endometriosis (the RP set) may play important roles in fibrogenesis but not necessarily malignant transformation. See Guo 2020a for review including mutations in endometriomas and normal tissue.
319. Klemmt 2018 – Other stem cell concerns include lack of apoptosis, evasion of immunosurveillance, angiogenesis, neurogenesis, exosomes, plasticity, stem cell signaling, aberrantly activated signaling pathways, stem cell migration, immunogenicity, peritoneal cavity homeostasis, dysregulation of Wnt and Hox genes, phenotype and microRNA analysis. Free download at <https://www.ncbi.nlm.nih.gov/pmc/articles/PMC5925869/>
320. Brosens 2018 – Progression requires active neo-angiogenesis.
321. Panir 2018 – Non-coding RNA is associated with endometriosis.
322. Foster 2018, Luo 2018, Matsuzaki 2018, Sui 2018 – Endometrial implant survival, growth, evasion from apoptosis, and immune dysregulation are estrogen-dependent processes. Either autophagy or apoptosis can be a cause of cell death. See Holder 2014, Simon 2015, and

- Brenhouse 2016 for neuroimmune maturation. See Gebel 1998 for apoptosis differences in endometrium and endometriosis.
323. Matsuzaki 2018 – Autophagy may be required for regrowth of endometriosis. Autophagy inhibition with MK2206 (an AKT inhibitor) and chloroquine may decrease the chance of recurrence. See Gebel 1998, Yang 2017, Foster 2018, Luo 2018, Matsuzaki 2018, Sui 2018.
 324. Baranov 2018 – A genetic program governs the origin of stem cells, transition into mesenchymal stem cells, invasion of the peritoneum and progression to late, endometriotic lesions. Baranov discusses the possibility that stem cells could be disseminated during organogenesis or from the endometrium during retrograde menstruation.
 325. Rei 2018 – Male endometriosis is rare. Rei found only 17 cases in men in the world literature from 1971 to 2018. Rei discusses Müllerian embryonal rests, induction (initiation or activation), immune dysfunction, and coelomic metaplasia theories. Seven of the most recent eight had markers compatible with Müllerian source. One (see Zamecnik 2013) of the seven had markers compatible with coelomic metaplasia. Even in men, more than one theory may be necessary. Open access at <https://www.ncbi.nlm.nih.gov/pmc/articles/PMC5833878/>
 326. Zhang 2018 – Metastasis-associated gene 1 (MTA1) may serve as a prognosis marker. The conclusion that a prognosis marker may be more important than a diagnostic marker was discussed at the 2017 World Congress of Endometriosis in Vancouver. See Guo 2009 for recurrence markers and Hughes 2015 for markers of diagnosis, response to treatment, and disease progression.
 327. Christofolini 2018 – Differences in allelic genetic distribution between fertile women and women with endometriosis and infertility are seen in the KAZN gene for grades 1 and 2 and LAMA5 gene for grades 3 and 4. Infertility may be genetic.
 328. Margatho 2018 – CA 125 decreases more on etonogestrel (ENG) implant than on levonorgestrel-releasing intrauterine system (LNG-IUS). However, the decrease in soluble CD23 and endometrial nerve fiber density were similar. CD23 and nerve fiber density may be a surrogate marker for response to hormonal suppression with implantable progestational devices. See Oosterlynck 1994 for CA 125 and natural killer activity response to excision. See Sasamoto 2020 for lack of discrimination.
 329. Chen 2018 – Women affected by endometriosis have an independently elevated risk of placenta previa in pregnancy. See Berlanda 2021 for increased obstetric risks of preterm delivery, neonatal admission to intensive care unit, placenta previa and cesarean delivery.
 330. Sui 2018 – Autophagy-related proteins, microtubule-associated protein light chain 3 (LC3) and Beclin1 were lower while matrix metalloproteinase-2 (MMP-2) was higher in women with endometriosis. See Bałkowiec 2018.
 331. Bałkowiec 2018 – Aberrant regulation of matrix metalloproteinases and tissue remodeling may cause endometrial lesion formation. A successful pregnancy is based on factors enhancing and suppressing matrix turnover in the cyclic preparation of the endometrium. Furthermore, endometriosis can induce aberration of the matrix balance and lead to adhesion formation, ovulatory dysfunction and fertility impairment. See Starzinski-Powitz 1999 and Koppolu 2021
 332. Nishihara 2018 – Oxidative stress in women with infertility is associated with endometriosis. See Mier-Cabrera 2009 & Samimi 2019

333. Jiang 2018 – IL-37 regulated the biological behavior of ectopic endometrial stromal cells through multiple signaling pathways such as β -catenin, p-p38, p-ERK1/2, and p-JNK, and this signaling was abolished by a Wnt/ β -catenin inhibitor.
334. Rekker 2018 – Cell-type-specific analysis revealed differences in miRNA expression patterns between stromal cells isolated from the endometrium and endometriomas. Two molecular mechanisms are involved in endometriosis pathogenesis. First, HOXA9 and HOXA10 genes are regulated by miR-139-5p among other factors and are potentially involved in endometriosis-associated infertility. Second, the aberrant expression of miR-375 in ectopic stromal cells may contribute to higher levels of EDN1 in lesions, which can be associated with pain mechanisms or be involved in the regulation of invasive growth and cell proliferation in endometriosis development. See Esfandiari 2021a for methylation of HOX cluster.
335. Gibson 2018 – ‘Intracrine’ is a 1980s concept based on the ability of cells within non-gonadal tissues to both produce and respond to the same hormone. Intracrinology is the way that tissue such as endometriosis can utilize inactive steroids present in the blood to respond to local physiological demands and ‘fine-tune’ the activation or inhibition of steroid hormone receptor-dependent processes.
336. Flores 2018 – Symptomatic response to progestin has been unpredictable. However, a progesterone receptor status can predict clinical response and, therefore, be useful in clinical management. See Marquardt 2019 for molecular mechanisms.
337. Arosh 2018 – Dual inhibition of ERK1/2 and AKT pathways, which regulate signaling proteins in human endometriotic cells in an epithelial cells and stromal cell specific pattern, can decrease the growth and survival of endometriotic lesions by decreasing proliferation and inducing apoptosis of epithelial cells and stromal cells of the endometriotic lesions.
338. García-Solares 2018 – Endometriotic gland invasion is dominated by collective cell migration. If the lead edge loses contact with the dominant central portion, expansion ceases.
339. Jaeger-Lansky 2018 – There were higher local levels of inflammatory IL-6, IL-8, IL-10 and TNF- α levels in peritoneal lavage fluid of endometriosis patients but not in plasma levels. There was no elevation of tissue damage markers (“Danger signals” HMGB1, IL-32 α , and IL-33) associated with cell death in response to strong inflammation.
340. Suda 2018 – Suda et al. identified numerous cancer-associated mutations in epithelial cells from ovarian endometriosis and normal endometrium. They describe a heterogeneous and mosaic-like uterine endometrial epithelium, shaped by endometrial glands with distinct somatic mutations. They suggest clonal expansion of epithelial cells with cancer-associated mutations leads to the development of endometriosis. See Hapangama 2018 for basal-like cells in the endometrium of endometriosis patients. See Anglesio 2017, Suda 2020 and Yachida 2021.
341. Hapangama 2018 – Women with endometriosis demonstrated higher number of basal-like cells (SSEA1+, nSOX9+) in the functionalis layer of the eutopic endometrium compared with the healthy women without endometriosis in the secretory phase of the cycle ($P < 0.05$). Induction (initiation or activation) of endometriosis resulted in a similar increase in basal-like epithelial cells in the eutopic baboon endometrium. See Suda 2018 for cancer-associated mutations.

342. Manavella 2018 – A two-step ovarian tissue transplantation procedure using adipose tissue-derived stem cells in xenografted frozen–thawed human ovarian tissue enhances vascularization in the early post-grafting period. A parallel implication is that the combination of local or hematogenous stem cells combined with retrograde menstruation may be necessary for or may increase the rate of implantation of endometriosis.
343. Marcellin 2018 – Marcellin, Méhats, and Gogusev found histopathological alterations (fibrinoid necrosis and connective tissue accumulation in the amnion, chorion, and decidual layers) in the fetal membranes of women with endometriosis, but none in controls at Cesarean-section. Fifteen (89%) of 19 were previously diagnosed at surgery while 4 (21%) of 19 women were diagnosed using clinical and imaging evaluation.
344. Nirgianakis 2018 – Nirgianakis et al. is a retrospective analysis of the complications of pregnancy after laparoscopic excision of deep infiltrating endometriosis (DIE). They conclude that excision of DIE does not decrease the increased risk of placenta previa, gestational hypertension and intra uterine growth retardation (IUGR) associated with endometriosis. See Chen 2018 and Berlanda 2021 for increased obstetric risks of preterm delivery, neonatal admission to intensive care unit, placenta previa and cesarean delivery.
345. Laganà 2018 – Updated article on molecular and cell biology insights.
Open access <https://www.mdpi.com/1422-0067/20/22/5615/pdf>
346. Miyazaki 2018 – Defective endometrial stromal fibroblasts (EMSFs) contribute to uterine factor infertility, endometriosis, and endometrial cancer. Induced pluripotent stem cells (iPSCs) derived from skin or bone marrow biopsies can provide a patient-specific source that can be differentiated to various cell types.
347. Long 2018 – Perioperative use of a nonspecific b-blocker and/or a nuclear factor-kB (NF-kB) inhibitor can retard the growth of residual endometriotic lesions that are left intact in the primary surgery in mice. Also see Rock 1981, Donnez 1984, Hu & Taylor 2019, Munrós 2017, Munrós 2019, and Guo and Martin 2019.
348. Grund 2018 – Cell contacts (tight junctions, adherens junctions, desmosomes, and gap junctions) exhibit a considerable influence on tissue physiology and homeostasis by controlling paracellular and intercellular transport processes, as well as by affecting signaling pathways. Since they maintain cell polarity, they play an important role in cell plasticity. In contrast to most other tissues, the endometrium undergoes extensive physiological changes and reveals an extraordinary plasticity due to its crucial role in the establishment and maintenance of pregnancy. These complex changes are accompanied by changes in direct cell–cell contacts to meet the various requirements in the respective developmental stage. Impairment of this sophisticated differentiation process may lead to failure of implantation and embryo development and may be involved in the pathogenesis of endometrial diseases. See Regidor 1997 for expression pattern of gap junction connexins in endometriotic tissues.
349. Warren 2018 – Flow cytometry analysis of cell subsets within the CD45+ fraction of menstrual effluent (ME) revealed a significant decrease in the number of uterine NK cells in endometriosis patients compared with controls. Menstrual effluent can be useful for investigating the pathobiology of endometriosis and for developing a non-invasive diagnostic for endometriosis. See Leyendecker 1998, 2009, 2015, 2022 and Canis 2016, 2017

350. Lin 2018 – Mesenchymal stem cell (MSC) based therapies are suggested for potential endometriosis treatment because of their immunomodulatory effects and tropism toward inflamed lesion foci. MSCs can be derived from bone marrow, adipose tissue, umbilical cord including Wharton’s jelly, and amnion). MSCs from different sources may respond differently to an inflammatory niche and the same MSCs can have behavioral differences because of their plasticity. Cytokine–receptor interactions for different MSC origins must be defined. Antiproliferative and antiangiogenic activity may be modified by gene-editing of MSCs.
351. Stylianou 2018 – The initiation of inflammation involves an intricate network of molecular and cellular pathways and interactions. Many of these, from the outset, contribute to both initiation and resolution of the inflammatory response. The molecular mechanisms that dysregulate a physiological, beneficial, inflammatory response, and render it to a chronic inflammatory pathology, are, at least to some degree, mediated by epigenomic changes, particularly the later stages.
352. Ong 2018 – Ong et al. (2018) concluded that it is unlikely that bone marrow cells are able to transdifferentiate into endometrial stroma, epithelium, and endothelium. This did not confirm previous work by Fernandez et al. (1995) who found bone marrow-derived cells in endometriosis. See Starzinski-Powitz 2001 & 2003 for differentiation, Meng 2007 & Chen 2019 for menstrual blood-derived stem cells, Hufnagel 2015 and Wang 2020 for BMD stem cells engrafted in endometriosis, Miyazaki 2018 for pluripotent stem cell, and Yin 2019 for CD34 (bone marrow derived stem cell marker) in endometrium. NOTE: Bone marrow–derived stem cells may engraft and “*differentiate into multiple cell types including endothelial, muscle, stromal, and epithelial cells.*” They are not specific for endometriosis. (Mamillapalli 2021)
353. Li 2018 – Hematogenous dissemination of mesenchymal stem cells from endometriosis. See Samani 2017 for migration (micrometastasis) to extrapelvic organs including the lung, spleen, liver, and brain in a mouse model. See Sampson 1918, Sampson 1927b, Bobek 2014, Chen 2017, Samani 2017, Pospisilova 2019, Vallvé-Juanico 2019 and Kiss 2020.
354. Taylor 2019 – Endometriosis is a complex systemic disease with manifestations including pain, fatigue, powerlessness, social support, emotional well-being and self-image impairment on the Endometriosis Health Profile 30; psychological manifestations; depression and anxiety; multiple organ system involvement; central sensitization; lower average body weight; and cardiovascular abnormalities. These likely involve circulating inflammatory cytokines and microRNAs. See McNamara 2021 for review of peripheral sensitization, central sensitization, cross organ sensitization, and comorbidities.
355. Zondervan 2018 and 2020 – The definition of endometriosis as “*endometrium-like tissue outside the uterus*” is inadequate to cover the complex symptomatology, pathobiology, and multisystemic nature of endometriosis. “*Whether these factors are pathogenic (causal) or merely represent a feature of the pathophysiological process typically measured years after symptom onset remains uncertain.*”
356. Surrey 2018 – The risk a comorbid condition among endometriosis cases was statistically significantly higher for 22 comorbidities and at least twice as large for nine comorbidities (infertility/subfertility, ovarian cyst, uterine fibroids, pelvic inflammatory disorder, interstitial cystitis, irritable bowel syndrome, constipation/dyschezia, ovarian cancer, and endometrial cancer). See Leuenberger 2022 for comorbidities review and Vandivier 1998

for team management. See Markovic 2008 and Sachedina 2020 for delay due to normalization of pain.

357. Liang 2018 – Estrogen can promote secretion of chemokines from peripheral nerves, enhancing the recruitment and polarization of macrophages in endometriotic tissue. Macrophages have a role in the expression of multiple nerve growth factors (NGF), which mediates the imbalance of neurogenesis in an estrogen-dependent manner. Under the influence of estrogen, co-existence of macrophages and nerves induces an innovative neuro-immune communication. Persistent stimulation by inflammatory cytokines from macrophages on nociceptors of peripheral nerves aggravates neuroinflammation through the release of inflammatory neurotransmitters. This neuro-immune interaction regulated by estrogen sensitizes peripheral nerves, leading to neuropathic pain in endometriosis. See Liang 2016, Smarr 2016, Liang 2019, Peinado 2020
358. Alberico 2018 – Women with endometriosis experience symptoms relief during and immediately after pregnancy. However, 37% had a clinically relevant recurrence of symptoms requiring medical or surgical treatment. Moreover, 84% of women reported at least one moderate-severe pain symptom at two years after delivery.
359. Hu & Taylor 2019 – Decreased miR-370-3p, is associated with an increased risk of endometriosis and was found in the circulation of women with endometriosis, indicating the potential for remote effects far removed from the areas affected by endometriosis. Steroidogenic factor 1 (SF-1), an essential transcriptional regulator of multiple genes involved in estrogen biosynthesis, is aberrantly increased and plays an important role in the pathogenesis of endometriosis. The expression of SF-1 in endometriosis is regulated by miR-370-3p. miR-370-3p levels are decreased in the serum of patients with endometriosis while SF-1 mRNA levels are inversely upregulated in endometriotic lesions compared to respective controls. Overexpression of miR-370-3p inhibits cell proliferation and induces apoptosis in endometriotic cells. miR-370-3p functions as a negative regulator of SF-1 and cell proliferation in endometriotic cells. MiR-370-3p may affect steroidogenesis in multiple organs, altering steroid production in several tissues and affecting the local estrogen effect throughout the body. See Sampson 1918 & 1927b for venous dissemination and Munrós 2017 and Munrós 2019 for circulating microparticle levels.
360. Yin & Taylor 2019 – Yin et al. discusses CD34+KLF4+ stromal stem cells contribution to endometrial regeneration and repair. CD34 is a marker for bone marrow derived, hematopoietic progenitor, vascular endothelial progenitors, mesenchymal (MSCs) and epithelial progenitor stem cells. Also see Fernandez 1995 for endometriosis, Starzinski-Powitz 2001 & 2003 for differentiation, Meng 2007 & Chen 2019 for menstrual blood-derived stem cells, Hufnagel 2015 and Wang 2020 for BMD stem cells in endometriosis, Miyazaki 2018 for pluripotent stem cell, and Yin 2019 for CD34 (bone marrow derived stem cell marker) in endometrium. Search file for “stem cell” for others. NOTE: Bone marrow-derived stem cells may engraft and “*differentiate into multiple cell types including endothelial, muscle, stromal, and epithelial cells.*” They are not specific for endometriosis. (Mamillapalli 2021)
361. Koninckx 2019a – The genetic/epigenetic theory is a theory of the transition from endometrial or other stem cells to endometriosis. It is not dependent on the cell of origin or method of dissemination. A set of genetic and epigenetic incidents transmitted at birth, some of which occurred during inter-uterine development, include hereditary aspects that

predispose to the endometriosis-associated changes in the endometrium, immunology, and placentation. However, to develop typical, cystic ovarian or deep endometriosis lesions, a variable series of additional transmissible genetic and epigenetic incidents are required to occur in a precursor cell. Subtle lesions are viewed as endometrium with a histologic diagnosis of “endometriosis.” After additional genetic and epigenetic incidents, those can transition into “endometriotic disease.” Typical cystic ovarian or deep endometriosis lesions are heterogeneous and represent three different diseases. See Deans 2015 for clarification of definitions of “*epigenetics*.”

362. Koninckx 2019b – Women with endometriosis have a significantly increased risk of lower genital tract infection, chronic endometritis, severe PID and surgical site infections after hysterectomy. They have more colony forming units of Gardnerella, Streptococcus, Enterococci and Escherichia coli in the endometrium. In the cervix Atopobium is absent, but Gardnerella, Streptococcus, Escherichia, Shigella, and Ureaplasma are increased. They have higher concentrations of Escherichia Coli and higher concentrations of bacterial endotoxins in menstrual blood. A Shigella/Escherichia dominant stool microbiome is more frequent. The peritoneal fluid of women with endometriosis contains higher concentrations of bacterial endotoxins and an increased incidence of mollicutes and of HPV viruses. Endometriosis lesions have a specific bacterial colonization with more frequently mollicutes (54%) and both high and medium-risk HPV infections (11%). They contain DNA with 96% homology with Shigella. In mice transplanted endometrium changes the gut microbiome while the gut microbiome influences the growth of these endometriosis lesions
363. Sokalska 2019 – Lipid-soluble statins (simvastatin, lovastatin, atorvastatin) were effective in inhibition of growth and invasiveness of human endometrial stromal cells.
364. Lac 2019 – Incisional endometriosis can develop cancer-associated driver mutations like deep infiltrating endometriosis. See Anglesio 2017 and Guo 2018b.
365. Ryu 2019 – Chrysin derived from honey, propolis (bee glue), or passion flowers has anti-inflammatory and anti-angiogenesis effects. Chrysin suppresses the proliferation of endometriosis and induces programmed cell death by activating the endoplasmic reticulum stress response, inactivating the PI3K signaling pathways, increasing the cytosolic calcium level, and generating of reactive oxygen species.
366. Donnez 2019 – External adenomyosis (a form of deep pelvic endometriosis) may be an extension of uterocervical adenomyosis. Uterocervical adenomyosis could therefore be the cause of deep endometriotic nodules, as is also the case for deep anterior endometriosis, called bladder adenomyotic nodules. External adenomyosis is contrasted with internal adenomyosis, and intramural adenomyosis.
367. Chen 2019 – Menstrual blood-derived stem cells (MenSCs) may contribute to endometriosis and be an alternative source for research and application in regenerative medicine. See Meng 2007 for initial recognition of MenSCs.
368. Sun 2019 – Interferon-inducible transmembrane protein 1 (IFITM1) is a sensitive marker for endometriotic stromal cells in ovarian and extragenital endometriosis. See Parra-Herran 2014 for high sensitivity and specificity of IFITM1 comparing normal and sarcomatous endometrial samples with leiomyoma, usual type, and cellular leiomyoma.
369. Bouquet de Joliniere 2019 – Expands the use of multiple inflammatory markers to classify endometriosis and discusses the possibility that these may promote individualized care.

370. Forster 2019 – Macrophages are central to the pathophysiology of endometriosis: they dictate the growth and vascularization of endometriosis lesions and promote lesion innervation. Disease-modified macrophages exhibit increased expression of IGF-1 in an in vitro model of endometriosis-associated macrophages. Macrophage-derived IGF-1 promotes sprouting neurogenesis and nerve sensitization in vitro. IGF-1 elevations in peritoneal fluid from women with endometriosis positively correlate with their pain scores. Macrophage depletion in a mouse model of endometriosis can reverse abnormal changes in pain behavior. The IGF-1 receptor inhibitor linsitinib reverses the pain behavior observed in mice with endometriosis. Therapies that modify macrophage phenotype may be attractive therapeutic options for the treatment of women with endometriosis-associated pain. See McNamara 2021 and Rumph 2020 for review of peripheral sensitization, central sensitization, cross organ sensitization, and comorbidities.
371. Knox 2019 – Adolescents with dysmenorrhea were followed for an average of 10.2 years during which time 18.6% were diagnosed with endometriosis. All cases of endometriosis were mild. This is contrasted with Brosens' 2013 conclusion from a tertiary center that endometriosis in adolescents is a hidden, progressive and severe disease. See Brosens 2013, Shafrir 2018, Knox 2019, Wüest 2023.
372. Yan 2019 – There is evidence that sensory nerves play an important role in promoting the development and fibrogenesis of endometriosis. This role explains as why the fibromuscular content of deep endometriosis is frequently higher than in ovarian endometriomas, highlights the importance of lesional microenvironment in shaping the lesional fate, gives more credence to the idea that ectopic endometrium is fundamentally wounds that go through repeated tissue injury and repair, and shed much needed light into the pathophysiology of endometriosis.
373. Zhou 2019a – Anti-inflammatory cytokines have indispensable roles in the progression of endometriosis, including the promotion of survival, growth, invasion, differentiation, angiogenesis, and immune escape of the endometriotic lesions. See Holder 2014, Simon 2015, and Brenhouse 2016 2016 for neuroimmune maturation.
374. Zhou 2019b – Women with high pre-operative anti-Müllerian hormone (AMH) had a significantly higher cumulative pregnancy rate than those with low AMH. Preoperative AMH level might be a useful marker to predict the occurrence of natural pregnancy and as part of the consideration of women considering endometriosis surgery for fertility.
375. Akter 2019 – Machine learning using transcriptomics and methylomics data can be used to distinguish endometriosis from non-endometriotic samples.
PMC: <https://www.ncbi.nlm.nih.gov/pmc/articles/PMC6737999/>
376. Mori 2019 – PGC-1 α , a transcriptional coactivator-modulating steroid hormone, regulates aromatase expression and activity. Estrogen activities mediated by different types of estrogen receptors abnormally elevated in local tissues could also be involved in the development of endometriosis. The authors demonstrated that the isoflavone aglycone, a partial agonist of the estrogen receptor, suppressed the formation of endometriotic lesions. See Noble 1996 & 1997 1997, Bulun 1999, Attar 2006a, Attar 2006b, Maia 2008, Northnick 2016

377. Samimi 2019 – Molecular signaling pathways can be used to study the roles of inflammation, oxidative stress, angiogenesis, and apoptosis dysregulation. See Mier-Cabrera 2009 and Nishihara 2018.
378. Alio 2019 – The 41 members of the Endometriosis Treatment Italian Club published ten low-value medical interventions, characterized by an unfavorable balance between potential benefits, potential harms, and costs, which should be discouraged in women with endometriosis. PMC: <https://www.ncbi.nlm.nih.gov/pmc/articles/PMC6560357/>
379. Liang 2019 – A pro-endometriotic niche can be established by an existing lesion as a supportive micro-environment for the progression of endometriosis. Reduction of estradiol can decrease chemokine CXCL12 and reduce BMSC accumulation and constrict angiogenesis. Targeting the components involved in pro-endometriotic niche formation and consequently preventing the progression of endometriosis may be a promising strategy for the treatment of endometriosis. See Liang 2016, Smarr 2016, Liang 2018, Peinado 2020.
380. Guo 2019 – The combined perioperative use of β -blockers and COX-2 inhibitors can suppress the activation of the hypothalamic-pituitary-adrenal (HPA) axis and sympathetic nervous system (SNS) and boost the cell-mediated immunity suppressed by surgery, resulting in the partial or even complete removal of minimal residual lesions (MRLs) unrecognized during surgery, and reduced risk of recurrence. Also see Rock 1981, Donnez 1984, Munrós 2017, Long 2018, Hu & Taylor 2019, and Munrós 2019. Roman 2021
381. Ding 2019 – Women with endometriomas demonstrate a hypercoagulable status due to the inflammatory nature of endometriosis. The combined determination for CA 125 and fibrinogen demonstrates a higher area under the curve than the single detection of CA 125 in those with endometriomas compared to these with benign ovarian cysts. Endometriosis is also associated with increased platelets. See Sasamoto 2020 for lack of discrimination.
382. Vallvé-Juanico 2019 – Circulating endometrial or endometriotic stromal cells were identified, only in women with endometriosis but not in controls using stromal marker CD10, while endometrial epithelial cells were not identified in the circulation of either group using epithelial marker cytokeratin (CK). Endometrial stromal cells may migrate through circulation and promote the pathophysiology of endometriosis. See Sampson 1918, Sampson 1927b, Bobek 2014, Chen 2017, Samani 2017, Li 2018, Pospisilova 2019, and Kiss 2020.
383. Ścieżyńska 2019 – Endometriosis may be a subject of immunotherapy by blocking NK cell negative control checkpoints including inhibitory NK cell receptors. Immunotherapies with genetically modified NK cells cannot be excluded.
384. Marquardt 2019 – This review focuses on the molecular mechanisms governing progesterone and estrogen signaling supporting endometrial function and how they become dysregulated in endometriosis. Progesterone and estrogen act primarily through their cognate receptors to set off cascades of signaling pathways and enact large-scale gene expression programs. In endometriosis, progesterone and estrogen signaling are disrupted, commonly resulting in progesterone resistance and estrogen dominance. This hormone imbalance leads to heightened inflammation and may also increase the pelvic pain of the disease and decrease endometrial receptivity to embryo implantation. See Grandi 2016, Flores 2018, Likes 2019, Marquardt 2019, and Donnez 2021.

385. Hu 2019 – As a master regulator of steroidogenic enzymes, SF-1 plays a key role in sustained survival of endometrial tissue at the ectopic sites by promoting a hyperestrogenic state in endometriosis. The aberrant presence of SF-1 in endometriosis and its absence in endometrium is the key event for the differential expression of StAR and CYP19A1. SF-1 mRNA levels are upregulated in endometriotic lesions compared to respective controls while miR-370-3p levels are decreased in the serum of patients with endometriosis. miR-370-3p functions as a negative regulator of SF-1 and cell proliferation in endometriotic cells. Decreased miR-370-3p is associated with increased endometriosis and was found in the circulation of women with endometriosis, indicating the potential for remote effects far removed from the areas affected by endometriosis. Overexpression of miR-370-3p inhibits cell proliferation and induces apoptosis in endometriotic cells. Steroidogenic factor 1 (SF-1), an essential transcriptional regulator of multiple genes involved in estrogen biosynthesis, is aberrantly increased and plays an important role in the pathogenesis of endometriosis. See Ohlsson Teague 2009, Burney 2009, and Agrawal 2018.
386. Pospisilova 2019 – Discusses increased sensitivity of tests for circulating endometrial cells (CECs) and potential use as a biomarker. See Sampson 1918 and Sampson 1927b for venous dissemination (metastasis) of intrauterine contents and Bobek 2014 for use as a marker. See Sampson 1918, Sampson 1927b, Bobek 2014, Chen 2017, Samani 2017, Li 2018, Vallvé-Juanico 2019, and Kiss 2020.
387. Wu 2019 – Recent molecular genetic findings suggest that circulating epithelial progenitor/stem cells which are intended to regenerate uterine endometrium after menstruation may become over-reacted (increase in number and adhesiveness) and can be trapped outside the uterus where the epithelium clonally expands and recruit polyclonal stromal cells to establish endometriosis. The epithelial progenitor cells may likely come from endometrium and circulate in the blood with highest amount during the proliferative phase. Analyzing the evolutionary history of multiple tubal lesions in the same four patients with concurrent ovarian carcinoma indicated distinct evolution trajectories. See Wang 2020.
388. Yilmaz 2019 – Nuclear receptors (NRs) are related to mechanisms responsible for (i) excessive estrogen biosynthesis, (ii) estrogen-dependent inflammation, (iii) defective differentiation due to progesterone resistance and (iv) enhanced survival due to deficient retinoid production and action in endometriosis. There are our distinct abnormalities in the intracavitary endometrium and extra-uterine endometriotic tissue that will underlie endometriosis progression: dysregulated differentiation of endometrial mesenchymal cells, abnormal epigenetic marks, inflammation activated by excess estrogen and the development of progesterone resistance. Steroid- and other NR-related abnormalities exert genome-wide biologic effects via interaction with defective epigenetic programming and enhance inflammation in endometriotic stromal cells. See Grandi 2016, Flores 2018, Likes 2019, Marquardt 2019, and Donnez 2021
389. Bulun 2019 – The underlying pathologic mechanisms in the intracavitary endometrium and extrauterine endometriotic tissue involve defectively programmed endometrial mesenchymal progenitor/stem cells. Populations of endometrial and endometriotic epithelial cells also harbor multiple cancer driver mutations, such as KRAS, which may be associated with the establishment of pelvic endometriosis or ovarian cancer. See Anglesio 2017. See Suda 2020 for genetic somatic copy number variations.

390. Vercellini 2019 – Serial ultrasonographic scans demonstrated transition from an ultrasonographically diagnosed hemorrhagic corpus luteum to a histologically confirmed endometriotic cyst in 11 (85%) of 13 women. None of those had histologic confirmation of a preexistent corpus luteum cyst. Bleeding from a corpus luteum appears to be a critical event in the development of endometriomas. Compare with Martin 1990b.
391. Chapron 2019 – A diagnosis of endometriosis should not lead to immediate surgery. Gynaecologists should consider the patient’s ‘endometriosis life’. Modern endometriosis management should be individualized with a patient-centered, multi- modal and interdisciplinary integrated approach.
392. As-Sanie 2019 – *“Delays in diagnosis can degrade the patient-provider relationship, cause physical and emotional damage, impair quality of life, and add to the significant personal and societal costs associated with the disease.” “Due in part to the societal normalization of women’s pain and stigma around menstrual issues, there is also a lack of disease awareness among patients, health care providers, and the public.”* About 95% of women with endometriosis have at least one or more comorbid disorders.
393. Steiner 2019 – In patients with recurrent implantation failure (RIF), treatment with a GnRH agonist plus letrozole, an aromatase inhibitor (AI), may improve live birth rates in subsequent cycles. We hypothesize that this improvement is due to alterations in the endometrium receptivity or treatment of undiagnosed endometriosis.
394. Likes 2019 – In patients who tested positive for endometrial BCL6 expression and treated with GnRH α for two months or surgery (ablation or excision), there were 50% and 52% live birth rates respectively compared with 7.4% of controls. All 21 patients who had laparoscopy had endometriosis. See Lessey 1995, Grandi 2016, Likes 2019, Lessey 2017, and Vargas 2022.
395. Berlanda 2019 – Women with deep endometriosis nodules had a non-significant decrease in nodule size from 19 \pm 6 mm before IVF and 18 \pm 7 mm after failed IVF. One woman had an enlarged ovary with multiple corpora lutea associated with transient renal ectasia.
396. Bas-Estevé 2019 – The association of ovarian epithelial tumors and endometriosis is a factor for good prognosis for ovarian cancer and that this association might correspond in many cases to an intermediate stage in the development of endometriosis to endometrioid, clear cell, or other invasive carcinomas. In addition, endometriosis can evolve to borderline endometrioid carcinoma or clear cell carcinoma.
397. Boretto 2019 – Endometrial disease organoids reproduced the original lesion when transplanted in vivo. Organoids from endometriosis show disease-associated traits and cancer-linked mutations. See Turco 2017 & Esfandiari 2021a.
398. Redwine 2019 – Metaplasia-capable mesodermal tracts with undifferentiated stem cells are what lead to local (superficial) recurrence after visible endometriosis has been excised.
399. Que 2019 – Concepts of metaplasia and transdifferentiation continue to evolve. Recently the concepts of paligenesis and transcommitment have been added to differentiation and transdifferentiation. This may apply not only to stem and precursor cells, but also to differentiated cells. Transdifferentiation is a process of reprogramming that can include fully differentiated squamous cells changing “into fully differentiated columnar cells—either directly (without undergoing a cell division) or indirectly (via cell division).” Paligenesis is “a process that starts with dedifferentiation of mature cells into progenitor-like cells before

they re-differentiate abnormally.” Transcommitment involves the reprogrammed of immature progenitor cells so that they "alter their normal pattern of differentiation" and "proliferate and differentiate into different cell types."

400. Armour 2019 – Self-care or lifestyle choices, were common (76%) amongst women with endometriosis. Heat (70%), rest (68%), meditation or breathing exercises (47%) were most common. Cannabis, heat, hemp/CBD oil, and dietary changes were the most highly rated in terms of self-reported effectiveness in pain reduction. Physical interventions such as yoga/Pilates, stretching, and exercise were rated as being less effective. Adverse events were common, especially with using alcohol (53.8%) and exercise (34.2%). Women with endometriosis have unique needs compared to women with primary dysmenorrhea, and therefore any self-management strategies, especially those that are physical in nature, need to be considered in light of the potential for 'flare ups'. See Van Niekerk 2021 on self-compassion. See Mistry 2022 for cannabis review.
401. Evans 2019 – Psychological and mind-body interventions appear promising to treat endometriosis-related pain, anxiety and depressive symptoms, stress and fatigue.
402. Kotlyar 2019 – The administration of disease-modifying anti-rheumatic drugs (DMARDs) for at least 6 weeks before surgery is associated with decreased opioid usage among women with endometriosis. Immunomodulators that may be useful in decreasing the elevated level of inflammation in endometriosis include DMARDs, cytokines, mTOR inhibitors, nucleotide analogs, and various other small molecules. See Kotlyar 2017.
403. Laganà 2020 – The direct effect of cabergoline on endometriosis implants is through its effect on angiogenesis in a murine model. Indeed, the exposure to cabergoline was associated with decreased number of active lesions, lower cellularity, and significantly less developed vascularization. Neoangiogenesis is essential for the onset and progression of endometriosis through pathways including increased levels of M2 macrophages as compared to M1 type, the overall dysregulation of inflammatory response, favoring Th2 anti-inflammatory response, and the direct ability of endometrial stem progenitor cells to induce angiogenesis by the production of the vascular endothelial growth factor (VEGF).
404. Peinado 2020 – Endometriosis risk is associated with bisphenol A (BPA) and Σ bisphenols but not with BPS or BPF. thiobarbituric acid reactive substances (TBARS) concentrations showed a close-to-significant increased endometriosis risk. Exposure to bisphenols may increase the risk of endometriosis, and oxidative stress may play a crucial role in this association. Bisphenol A (BPA), an endocrine disrupting chemical, is used in the manufacture of polycarbonates and epoxy resins for water bottles, plastic containers, and cans for food or beverages. See Rier 1993, 1995, 2001 & Smarr 2006. See Rier 1993, Rier 1995, Rier 2001, Caserta 2008, Smarr 2016, Bruner-Tran 2016, Peinado 2020, and Rumph 2020 for endocrine disrupting chemicals.
405. Rumph 2020 – Accumulating evidence over the last decade strongly suggests a link between environmental endocrine disruptor chemicals (EDC) exposure and the subsequent development of endometriosis and multiple comorbidities (subfertility, preterm birth, adenomyosis). Experimental evidence demonstrates that developmental exposure to EDCs can lead to transgenerational adverse health consequences, many of which have been linked to endometriosis. Although such a concept is difficult to prove in humans, evidence from accidentally exposed populations suggests the occurrence of transgenerational effects is likely. The concept of “fetal origins of adult disease” (now more commonly termed

- “developmental origins of health and disease (DOHaD)” was initially described following the development of metabolic syndrome in adults who experienced maternal malnutrition in utero. However, this concept has expanded exponentially and now considers that maternal stress, toxicant exposures, and other factors (both positive and negative) also contribute to fetal programming. See Rier 1993, Rier 1995, Rier 2001, Caserta 2008, Smarr 2016, Bruner-Tran 2016, Peinado 2020, and Rumph 2020 for endocrine disrupting chemicals.
406. Pluchino 2020 – Targeting CXCR4 or CXCR7 receptors reduced bone marrow-derived stem cell recruitment into endometriosis implants. Endometriosis lesion size was not affected when the local effects of CXCL12 were abrogated suggesting an effect primarily on bone marrow cell migration rather than a direct endometrial effect. Antagonist treatment also decreased hallmarks of endometriosis physiopathology such as pro-inflammatory cytokine production and vascularization.
407. Ghiasi 2020 – Heterogeneity of inclusion and diagnostic criteria and selection bias overwhelmingly account for variability in endometriosis prevalence estimated across the literature. Thus, it is difficult to conclude if the lack of observed change in frequency and distribution of endometriosis over the past 30 years is valid.
408. Lu 2020 – T-cadherin (T-cad), an important cell surface glycoprotein adhesion molecule, is coded by the CDH13 gene. T-cadherin can inhibit cell invasion, migration, and proliferation in various cancer cells. T-cadherin overexpression inhibited the invasion and migration of endometrial stromal cells. The expression of T-cadherin was decreased in ectopic endometriotic lesions, but not the normal control endometrium or the endometriotic eutopic endometrium.
409. Jerman 2020 – In bowel endometriosis and pelvic cancer populations with or without endometriosis, endometrium-like cells (CD10) and immune cell populations (T cells (CD3, CD4, CD8, and FoxP3), dendritic cells (DC; DC-Lamp and DC-Sign), B cells (CD20, CD79 and plasma), macrophages (CD68), and natural killer cells (NK; CD57)) were present in all studied nodes. No difference in cancer associated node CD10 with or without endometriosis. None of the studied lymph nodes contained endometriotic lesions. See Sampson 1922, Halban 1924, Jerman 2015, Simon 2015, Rossini 2016, and Lenz 2020.
410. Alali 2020 – Expression of RPLP1 mRNA and protein were significantly higher in ectopic lesion tissue compared to paired eutopic endometrium and immunohistochemical localization revealed predominant localization to epithelial cells. The ribosomal protein large P1 (RPLP1) is associated with cell proliferation and/or survival and may play a role in the pathophysiology of endometriosis.
411. Angioni 2020 – Genetics are population dependent and require evaluating genetic variants in different populations. In different ethnic groups, it is possible that specific risk alleles could act differently in the pathogenesis of the disease.
412. Hogg 2020 – Hogg explores the paradigm that under disease-modified conditions, macrophages that normally maintain homeostasis become modified such that they promote disease. In health, tissue-resident macrophages seeded during early embryonic life are vital for development and homeostasis of tissues. In the adult, under inflammatory challenge, monocytes are recruited from the blood and differentiate into macrophages in tissues where they fulfill functions, such as fighting infection and repairing wounds. In endometriosis,

Macrophages are critical for the growth, development, vascularization, and innervation of lesions as well as generation of pain symptoms.

413. Guo 2020a – Cancer-associated mutations (CAMs) are found in deep infiltrating endometriosis, endometriomas, and normal appearing tissue. Endometriotic epithelial cells have much higher mutation frequencies than their stromal counterpart. Genes involved in CAMs are likely to be active players in lesional fibrogenesis, and hyperestrogenism and oxidative stress are likely drivers of both CAMs and fibrogenesis. Furthermore, endometriotic lesions harboring CAMs would conceivably be more refractory to medical treatment, due, in no small part, to their high fibrotic content and reduced vascularity and cellularity.
414. Guo 2020b – Although there are similarities between eutopic endometriosis and ectopic endometrium, they are quite different. There are almost 1000 differentially expressed genes between interview eutopic endometrium and ectopic endometriosis and adenomyosis. Epigenetic demethylation can increase P450 aromatase, estrogen, and other markers. See Wu 2006, Iszawa 2008, Iszawa 2011.
415. Wei 2020 – Wei et al. reviews inflammation, autonomic nervous system, and inflammation interaction in endometriosis-associated pain including cellular components (macrophages, mast cells, neutrophils), inflammatory mediators (interleukins, transforming growth factor β 1, tumor necrosis factor- α , prostaglandin, noninflammatory factors), influence of estrogen, neurotropic and neuroprotective activity of cytokines, sympathetic and sensory nerve distribution, neurotrophins, the transition from acute to chronic inflammation, and potential implications in the management of endometriosis. Some chronic inflammatory autoimmune diseases (AIDs) such as inflammatory bowel disease (IBD) and rheumatoid arthritis (RA) share similar characteristics: the changes in dysregulation of inflammatory factors as well as the function and innervation of the autonomic nervous system (ANS).
416. García-Gómez 2020 – Hormonal alterations in endometriosis are related to the inflammatory unbalance in this disease. Steroid hormones (mainly estradiol) promote the expression and release of pro-inflammatory factors. Excessive inflammation in endometriosis contributes to changes of hormonal regulation by modulating sex steroid receptors expression and increasing aromatase activity. Dysregulation of the inflammasome pathway, mediated by an alteration of cellular responses to steroid hormones, participates in disease progression through preventing cell death, promoting adhesion, invasion, and cell proliferation. Inflammation is involved in endometriosis-associated infertility, which alters endometrium receptivity.
417. Kiss 2020 – Women with spontaneous pneumothorax (SP) have gene expression profiling revealed two distinct phenotypes of circulating endometrial cells (CECs) in SP and catamenial pneumothorax CP: one of them refers to the diaphragm openings syndrome and the other to endometrial tissue pleural implantations. Comparisons of the gene expression profiles of CECs in pneumothorax (CECs-SP group) with CECs in pelvic endometriosis (CECs-non-SP group) have revealed significantly higher expression of HER2 in the CECs-SP group compared with the CECs-non-SP group. Identification of CECs in SP could alert endometriosis involvement. See Sampson 1918, Sampson 1927b, Bobek 2014, Chen 2017, Samani 2017, Li 2018, Pospisilova 2019, and Vallvé-Juanico 2019.
418. Leonardi 2020a – A systemic review found that laboratory and clinical studies demonstrate that there are differences in the microbiome composition of hosts with and without

endometriosis. Endometriosis appears to be associated with an increased presence of Proteobacteria, Enterobacteriaceae, Streptococcus spp. and Escherichia coli across various microbiome sites. The phylum Firmicutes and the genus Gardnerella also appear to have an association; however, this remains unclear. Also see Khan 2010 for bacterial endotoxins; Khan 2016 for crosstalk between inflammation and ovarian steroids or the stress reaction; Koninckx 2019 for a review of microbiome, infection, and bacterial endotoxin, and “[Subtle Inflammatory Lesions.](#)”

419. Leonardi 2020b – Superficial endometriosis can be seen on sonoPODography (saline-infusion ultrasound of the Pouch of Douglas).
420. Friedman 2020 – Several studies on measured peripheral miRNAs in women with and without endometriosis report disparate findings regarding which plasma miRNAs are altered. Interstudy inconsistencies may be attributed to disparities between study populations, variable specimens, specimen handling, different stages of the menstrual cycle, and variation in plasma miRNA detection platforms. Despite the inconsistent reports, an optimist might discern an emerging consensus regarding altered plasma expression of several miRNAs (miR-17-5p?, miR-20a-5p?, miR-125b?) in patients with endometriosis. However, there remains no consensus on which plasma miRNAs, if any, will predict the presence of in the clinical setting. But there is evidence that miRNAs play a direct role in the pathogenesis of endometriosis by regulating essential processes such as inflammation and angiogenesis. Whether plasma miRNAs contribute to pathogenesis or are simply markers of existing disease and whether peripheral miRNAs correlate with severity of disease or the degree of pelvic pain remains unknown.
421. Ottolina 2020 – This meta-analysis aims to offer a general picture of the available data regarding the effects of early-life factors and risk to develop endometriosis in adult life. Six studies that included a total of 2,360 women affected by endometriosis were analyzed. The pooled results showed that the risk to develop endometriosis in adult life was significantly increased by being born prematurely, having a low birth weight, being formula-fed, and having been exposed to diethylstilbestrol (DES, a synthetic estrogen) in utero. Among intrauterine and early neonatal exposures, prematurity, birth weight, formula feeding, and DES were risk factors for the development of endometriosis in adult life. See Karnaky 1948, Karnaky 1969 for mid-1900s use of DES to treat endometriosis and [medical reversal](#).
422. Long 2020 – Long et al. (2020) studies the adverse effects of neonatal maternal separation as a form of early-life adversity with subsequent adult development of abnormalities including activation of adrenergic receptor signaling pathways, increased angiogenesis, altered neuronal wiring, hyperactivity of the hypothalamic pituitary adrenal axis, anxiety and depressive symptoms. Open Access <https://doi.org/10.1186/s12958-020-00600-4> See Upson 2015 and Ottolina 2020 for increase in endometriosis within utero DES exposure.
423. Matsuzaki 2020 – Anti-inflammatory treatment may prevent growth of endometriotic tissues in excessive inflammatory stages, whereas it may have deleterious effects on fibrotic endometriotic tissues in a low-grade inflammation setting. Patients with inflammatory-stage fibrotic disease are most likely to respond, while patients with noninflammatory fibrosis might experience deleterious effects. Administration of COX-2 inhibitors in the early phase of inflammation yields an anti-inflammatory effect. However, inhibition of COX-2 by nonsteroidal anti-inflammatory drugs (NSAIDs), if used for more than 48 h, causes inhibition of anti-inflammatory mediators, and thus prolongs chronic inflammation and

- activates fibrosis of the kidneys, lungs, intestines, and muscles, as COX-2 is an important anti-fibrotic enzyme. PMC: <https://www.ncbi.nlm.nih.gov/pmc/articles/PMC7289797/>
424. Song 2020 – Forty-four (51.8% of 85) adolescents had genital tract malformations. 6 (7.1%) were rASRM stage I, 6 (7.1%) were Stage II, 41 (48.2%) were Stage III and 32 (37.6%) were Stage IV. These represent 85 (0.8%) of 11,236 surgically treated endometriosis patients 2008-2018. See Fallas 1956, Marsh & Laufer 2005, and Brosens 2013.
425. Sasamoto 2020 – CA125 did not discriminate endometriosis cases with pain from controls. CA125 values were low in adolescents and young women in both endometriosis cases and controls, suggesting cautious interpretation may be needed when measuring CA125 in this population.
426. Buggio 2020 – Alterations in the anogenital distance (AGD) (i.e., the distance measured from the anus to the genital tubercle) are associated with reproductive health in adult males and females. Studies suggest that a shorter AGD seems to be related to the presence of endometriosis, whereas a longer AGD seems to be associated with an increased risk of PCOS. Scientific evidence is limited, and further well-designed studies are needed to corroborate the findings.
427. Chen 2020 – Relaxin/relaxin family peptide receptor 1 (RXFP1) signaling is important for both normal physiology and disease. Strong preclinical evidence supports relaxin as a potent antifibrotic molecule. However, relaxin-based therapy failed in clinical trials in patients with systemic sclerosis. Aberrant expression of RXFP1 may contribute to the abnormal relaxin/RXFP1 signaling in different diseases. Reduced RXFP1 expression and alternative splicing transcripts with potential functional consequences have been observed in fibrotic tissues. A relative decrease in RXFP1 expression in fibrotic tissues—specifically lung and skin—may explain a potential insensitivity to relaxin. In addition, receptor dimerization also plays important roles in relaxin/RXFP1 signaling.
428. Hirata 2020 – All catamenial hemoptysis (CH) patients experienced symptomatic improvement with hormone therapy, no recurrence during hormone therapy, and consequently no surgical therapy, unlike catamenial pneumothorax or endometriosis-related pneumothorax (CP/ERP), patients. The authors proposed that hormonal or conservative treatment was an adequate first-line treatment for most patients with CH. This contrasts with CP/ERP, which has a high recurrence rate both after surgery and hormonal therapy. Accordingly, CP/ERP and CH are suggested to be distinct entities, although both are types of thoracic endometriosis.
429. Sachedina 2020 – Most adolescents will experience discomfort during menstruation. Due to normalization of dysmenorrhea, there is delay in diagnosis and treatment. Health care providers should avoid normalization of dysmenorrhea, as young women are missing out on educational, social and vocational opportunities. Non-steroidal anti-inflammatories (NSAIDs) are a first line treatment. Menstrual suppression with combined estrogen and progestin hormones such as oral contraceptives or progestin-only options are also first line. Transabdominal ultrasound is indicated when first line treatments do not improve symptoms. When first line treatments do not improve symptoms, gonadotropin releasing hormone agonists with add-back treatment or laparoscopy can be considered. If laparoscopy is performed and endometriosis visualized, it should be treated with either excision or ablation. Women with endometriosis should be counselled on menstrual suppression until fertility is desired. Management of chronic pain requires the involvement of a multi-

disciplinary team. Also see Markovic 2008 for normalization of menstrual pain by young women, their families and health professionals resulting in delay to diagnosis and long-term exposure to biomedical treatments. See Markovic 2008, Brosens 2013, Shafrir 2018, Knox 2019, Simpson 2021, and Wüest 2023.

430. Matsuzaki 2020 – Primordial follicle activation initiates follicle growth and development and this irreversible process is the primary mode of primordial follicle depletion. Primordial follicle density is lower in the ovarian cortex surrounding endometriomas than in contralateral, unaffected ovaries and in the tissue surrounding non-endometriotic benign cysts. Uncontrolled inflammation, such as that of endometriomas and surgery, may adversely affect ovarian reserve. Inflammation can cause hyperactivation of dormant primordial follicles through the local microenvironment of ovarian endometrioma (mechanical and/or chemical cues). Both conservative management and surgical injury of ovarian endometrioma might decrease ovarian reserve over time.
431. Börschel 2020 – Downregulated microRNA-142-3p signaling contributes to the pathogenesis of endometriosis through a strong mechano-regulatory effect on endometrial stroma cells. Its external administration reduces the invasive endometrial phenotype.
432. Yoshino 2020 – Relaxin (RLX)-2, produced by the corpus luteum and placenta, is known to be potentially effective in fibrotic diseases of the heart, lungs, kidneys, and bladder. In the endometriosis mouse model, administration of RLX-2 significantly decreased the area of the endometriotic-like lesion with decreasing fibrotic component compared to non-treated control.
433. Zhang 2021 – The PPAR γ agonist rosiglitazone (RSG) (Avandia) is an antidiabetic drug in the thiazolidinedione class that decreases the development and progression of endometriosis in rats likely by inhibiting angiogenesis and inducing apoptosis.
434. Wang 2020 – Molecular genetic findings on endometriosis and normal endometrium suggest a modified model in which circulating epithelial progenitor or stem cells intended to regenerate uterine endometrium after menstruation become overreactive and trapped outside the uterus. These trapped epithelium-committed progenitor cells glands and recruit polyclonal stromal cells, leading to the establishment of endometriosis. The ectopic tissue is subject to immune surveillance, resulting in chronic inflammation in which nuclear factor- κ B signaling is exacerbated by aberrations in the estrogen receptor- β and progesterone receptor pathways. This results in a dysregulated inflammation-hormonal loop.
435. Plavnik 2020 – Sixteen female patients with biopsy-confirmed endometriosis had ultrasound-guided pelvic-floor trigger-point injections and peripheral nerve hydrodissection performed once a week for 6 weeks. Pretreatment, the mean VAS score was 6, and posttreatment was 2.9. The mean total FPPS score before treatment was 14.4 and posttreatment it was 9.1. The improvement was statistically significant for intercourse, sleeping, and working. For intercourse, sleeping, and working, the mean changes in scores after treatment were 1.3, 1.2, and 0.9, respectively.
436. Surrey 2020 – Endometriosis-related medical, surgical, or both treatments were used 61%, 35%, and 73% of patients, respectively, in the 16 months before the use of the GnRH antagonist elagolix. Opioids were used by 57.3% of the patients. Pelvic pain, dysmenorrhea, and dyspareunia were coded for 71.5%, 30.4%, and 19.3% of the patients, respectively.

437. Lenz 2020 – The immunophenotype in cases with and without node involvement was similar in the proliferative phase with strong nuclear ER and PR expression in more than 90% of endometrial glandular and stromal cells. In the late secretory phase, a significant decrease of ER expression occurred only in those without nodal involvement. Perineural spread of endometriosis with significant neural hypertrophy, hyperplasia and involvement of the ganglia of the autonomic nervous system was detected in 5 cases. From a histological and immunohistochemical point of view, deep infiltrating endometriosis and lymph node endometriosis appear to represent the same entity. The marked endometriosis-associated neural changes (endometriotic neuropathy) could be one of the causes of impaired function of the affected organs after debulking surgery with macroscopic negative resection margins as well as pain symptomatology in macroscopic inapparent endometriotic lesions. See Taussig 1906, Sampson 1926, Javert 1949, Noël 2008, Rossini 2016.
438. McGuinness 2020 – Tubal endometriosis was recognized in 34% of patients: 11% clinically and another 23% histologically. This adds to the concerns regarding unrecognized endometriosis noted since Russell found unseen intraovarian endometriosis in 1899. Areas where endometrium is visually missed include the retroperitoneum (cervix, rectum, ureter, lymphatics including nodes, nerves) (Taussig 1906, Sampson 1926, Rossini 2016, Javert 1949, Moore 1988, Nezhat 1991, Koninckx 1993, Koninckx 1996, Possover 2007, Possover 2015, Law 2020), adhesions and scar (Russell 1899, Sampson 1921, Longo 1979, Griffiths 2007), large and small bowel (Martin 1990c, Kavallaris 2003, Badescu 2016, Badescu 2018, Roman 2021), appendix (Martin 1990a, 1990c), epiploic fat (Martin 1989b), mesentery (Martin 1995), cryptic pockets (Martin 1992, Stuparich 2019), ovaries (Russell 1899, Longo 1979, Candiani 1990), tubes (Yamamoto 1997, McGuinness 2020), and omentum (Zinsser 1982).
439. Le 2020 – Endometriosis patients on hormonal suppression had improvement with less systemic and local inflammation as measured by higher iTregs (tolerant), lower Th17 (inflammatory), and an increased in Treg/Th17 ratio. The imbalance within immune populations of inflammation in patients with endometriosis was improved on monophasic hormonal suppression with oral contraceptive pills. There were decreased inducible Treg cells and inflammatory Th17 cells in the blood, eutopic endometrium, and endometriosis, suggesting decreased systemic and local inflammation.
440. Persoons 2020 - A model for endometriosis-associated pain was induced in rats and resulted in neuro-angiogenesis and endometriotic lesions like humans. Significant differences were noted between control and endometriosis animals concerning bodyweight and posture changes, indicating the presence of ongoing pain in animals with endometriosis.
441. Tuominen 2020 – Women with rectovaginal endometriosis have similar pregnancy and live-birth rates. Cesarean delivery and complications were also similar.
442. Lin 2020 – Patients with endometriosis have an increased risk of systemic lupus erythematosus (SLE) compared to controls (HR 1.86). Hormonal but not surgical treatment reduces the risk of SLE.
443. Suda 2020 – Clonal relationships of somatic copy number variations (SNVs) were demonstrated among uterine endometrium, ovarian endometriosis and ovarian clear cell carcinoma. A reconstructed clonal evolution tree showed that the epithelium samples were derived from a single ancestral clone. Frequently mutated genes with clonal lineage include ARID1A, ATM, CDH4, NRAS and PIK3CA. Although a splice site mutation of ARID1A

was shared among the four epithelium samples, a frameshift insertion in ARID1A was shared by adjacent endometriosis and carcinoma samples, suggesting that the biallelic mutations triggered malignant transformation. Somatic copy number alterations, including loss of heterozygosity events at PIK3CA and ATM, were identified only in adjacent endometriosis and carcinoma, suggesting that mutant allele-specific imbalance is another key factor driving malignant transformation. See Yachida 2021 for loss of ARID1A seen in ovarian cancer. See Anglesio 2017

444. Borghini 2020 – Nickel allergic contact mucositis has a high prevalence in endometriosis and a low-Ni diet may reduce gastrointestinal, extra-intestinal and gynecological symptoms.
445. Sarria-Santamera 2020 – Sarria-Santamera et al. summarized 27 papers with 28,660,652 women. The pooled prevalence varied from 1% for population-based integrated information systems to 5% for self-reported data. The incidence varied from 0.13% to 0.35%. A wider range of 0.1% to 0.7% is seen in Christ et al. (2021) and Morassutto et al. (2016).
446. Roman 2021 – Seven (14%) of 51 patients having bowel resection for endometriosis had laparoscopically nonvisualized palpable satellite lesions at or past the planned stapler site. A total of 13 (25.5%) had palpable satellite lesions as small as 2 mm. Although reported success rates for bowel endometriosis are 1-16%, recurrence after unrecognized endometriosis at the margins is 7-38.5%. See Moore 1988 for retroperitoneal endometriosis and Griffiths 2007 for rectovaginal endometriosis missed at first laparoscopy in 14 (88%) of 16 cases but identified using a rectal probe. Goncalves 2021 for low sensitivity of laparoscopic visualization. See Martin 2023 for missed rectovaginal endometriosis.’
447. Chen 2021 – Endometrial cell proliferation is induced by stem cell–derived trophic factors leading to the growth of endometriotic lesions. See Wu 2019 and Wang 2020.
448. Lee 2021 – Fetal death associated with bleeding from 2 cm cecal endometriosis and melanic stool. Her hemoglobin of 6.1 g/dL at 37 weeks was a drop from 11 g/dL at 28 weeks.
449. Yin 2021 – ITPR1-knockdown ectopic human endometrial stromal cells from ovarian endometriosis (OE) were analyzed to identify ovarian endometriosis-relevant gene modules involving the PI3K/Akt and aging-relevant pathways. Camptothecin and irinotecan are promising drugs that suppressed HESC proliferation and induced apoptosis. Camptothecin also suppressed ITPR1 expression. These drugs may be useful in the treatment of ovarian endometriosis.
450. Koppolu 2021 – Mechanisms involved in extracellular matrix remodeling can resemble cancer-like progression and invasion. These can lead to matrix balance abnormalities, adhesions, ovulatory dysfunction, and infertility. Cell adhesion molecules appear to be central to invasion and metastasis. See Starzinski-Powitz 1999 and Bałkowiec 2018.
451. Goncalves 2021 – Visual recognition at laparoscopy for bowel endometriosis is limited. Prospective observers who were blinded to physical exam and ultrasound results, only identified 5.6% of bowel endometriosis that had been treated at previous laparoscopy. This contrasts with 96% identified by sonography. See Roman 2021 for palpable lesions.
452. Perrotta 2020 – Machine-learning models could accurately distinguish between rASRM stages 1-2 and rASRM stages 3-4 endometriosis using an operational taxonomic unit (OYU) from the genus Anaerococcus.

453. Li 2021 – Hypoxia aids in control of endometriosis phenotypes including adhesion formation and in the dysregulation of estrogen biosynthesis, aberrant production of proinflammatory cytokines, increasing angiogenic ability, and suppression of immune functions.
454. Waiyaput 2021 – Oral contraceptives may decrease the growth of endometriosis by decreasing inflammation. There was significant decrease in the number of macrophages (CD68) and an increase in natural killer (CD56) and regulatory T cells (forkhead–winged helix transcription factor (FoxP3)) in the endometriomas of women treated with oral contraceptive tablets (EE 0.03 mg / desogestrel 0.15 mg) for 28 to 35 days before surgery.
455. Martin 2021 – Juvenile cystic adenomyomas may be a form of acquired adenomyosis variant or a congenital Mullerian defects. See Batt and Yeh 2013 and Arya and Burks 2021.
456. Freger 2021 – Small membrane-bound extracellular vesicles called exosomes (30–100nm) modulate migration, invasion, inflammation, angiogenesis, neurogenesis, immune modulation, endometrial stromal cell invasion, and central processes in endometriosis.
457. Fonseca 2021 – Transcriptomes of cells from endometriosis and normal tissue were used to create a cellular atlas of endometrium-type epithelial cells, endometrium-type stromal cells and microenvironmental cell populations across tissue sites. Signatures of endometrium-type epithelium and stroma differed markedly across eutopic endometrium, endometrioma, superficial extra-ovarian disease and deep infiltrating endometriosis, suggesting that extensive transcriptional reprogramming is a core component of the disease process.
458. McQueen 2021 – McQueen et al. found that the combination of plasma cells and endometrial stromal changes were limited to the recurrent pregnancy loss cohort and proposed “that chronic endometritis be defined as the presence of one or more plasma cells per 10 HPFs in the setting of endometrial stromal changes.”
459. De Pascali 2021 – Vitamin D receptor (VDR) and aryl hydrocarbon receptor (AHR) are nuclear receptors that translocate to the nucleus and activate the expression of genes. Both have been identified in the pathogenesis of endometriosis. In the nuclei of glandular cells in endometriosis, the expression of VDR and AHR are inversely related—when the expression of one receptor is high, the other one is low—suggesting a possible target in the treatment of endometriosis. Also, the expression of glandular cytoplasmic AHR between the proliferative and late secretory endometrium changes significantly.
460. Donnez 2021 – Progestogens are not effective in 33% of women suffering from endometriosis because of progesterone resistance. See Grandi 2016, Flores 2018, Likes 2019, Marquardt 2019, Yilmaz 2019, Donnez 2021, Bulun 2021, Zhang 2023 for progesterone resistance.
461. Masuda 2021 – Clonogenic endometrial cells, SUSD2+ mesenchymal stem cells (eMSC), and N-cadherin+ epithelial progenitor cells (eEPC) were found in most uterine menstrual blood (UMB) samples at similar concentrations in women with and without endometriosis. More clonogenic cells persisted beyond the menstrual phase in the peritoneal fluid of women with endometriosis. In contrast, 62.5% of women with endometriosis and 75.0% without had clonogenic cells in peritoneal fluid samples during menses. The eMSC were present in the peritoneal fluid of 76.9% of women with endometriosis and 44.4% without, and eEPC were found in the peritoneal fluid of 60.0% of women with and 25.0% without

endometriosis during menses. No clonogenic endometrial cells were found in peripheral blood.

462. Mamillapalli 2021 – Bone marrow–derived stem cells may engraft and “differentiate into multiple cell types including endothelial, muscle, stromal, and epithelial cells.” They are not specific for endometriosis.
463. Moses 2021 – Nanoparticles are promising vehicles for the delivery of drugs and imaging agents to disease sites as demonstrated in rodent models. Nanomaterials are studied in photothermal therapy, magnetic hyperthermia, and photoacoustic imaging. “They can solubilize otherwise insoluble compounds and, protect cargos such as nucleic acids and unstable drugs from hydrolysis, oxidation, or other degradative processes in the systemic circulation. Moreover, they can extend the circulation time of drugs in the blood, allowing them to reach their therapeutic targets, and to deliver greater amounts of drugs to their target sites more precisely while reducing systemic toxicity via passive targeting or through the use of active targeting moieties.” See Chaudhury 2013.
464. Yachida 2021 – KRAS, PIK3CA, and ARID1A were the most frequently mutated genes with high mutant allele frequencies (MAFs) in ovarian endometriosis. A genomic linkage from normal endometrium to ovarian endometriosis and endometriosis-associated ovarian cancer was seen when ARID1A protein expression was absent in clear cell carcinoma samples that harbored multiple ARID1A loss-of-function mutations or ARID1A allelic imbalances. An ARID1A first hit was associated with endometriosis and a second hit with loss of ARID1A was seen in ovarian cancer. See Suda 2020 for frequently mutated genes with clonal lineage.
465. Esfandiari 2021a – The methylation pattern of human homeobox (HOX) clusters (A–D) and HOX cofactors in normal, eutopic, and ectopic endometrial tissues with ectopic and eutopic endometriosis organoids were determined in epithelial organoids. A conserved pattern of methylation alterations in endometriosis tissues and organoids was observed for 56 of 84 investigated genes. It can be concluded that endometriosis organoids maintain epigenetic changes. They are limited as they have no stroma, blood vessels, innervation, or immune cells. Also see Wu 2006, Iszawa 2008, Iszawa 2011, Kubota 2012, Koukoura 2016, Turco 2017, Boretto 2019, Guo 2020b, Farahani 2021, and Esfandiari 2021b.
466. Esfandiari 2021b – HOX genes are remarkable because of their critical role in endometrial development and receptivity during implantation, which is attributed to their ability to mediate some of the sex steroid functions during the reproductive period. There is an altered expression pattern for the HOX clusters (A-D) and their cofactors in both eutopic and ectopic tissue in endometriosis patients compared to control tissue biopsies. Most of the intensive changes occurred in eutopic samples from endometriosis patients compared to control tissue biopsies. Pathway analysis revealed the involvement of differentially expressed genes in cancer that correlate with an association between endometriosis and cancer. Also see Wu 2006, Iszawa 2008, Iszawa 2011, Kubota 2012, Koukoura 2016, Turco 2017, Boretto 2019, Guo 2020b, Farahani 2021 and Esfandiari 2021a.
467. Simpson 2021 – Adolescents wait three times longer than their adult counterparts to seek medical treatment for pain symptoms. Delay is associated with physician and/or patient knowledge gap, normalization by physician and patient, lack of research, and physician resistance. Strategies to lessen diagnostic delay of endometriosis in adolescents must include integrated actions by educators and healthcare providers to improve health literacy and

- awareness of common causes of pelvic pain in this age group. See Markovic 2008, Brosens 2013, Shafrir 2018, Knox 2019, Sachedina 2020, and Wüest 2023.
468. Olkowska-Truchanowicz 2021 – Peritoneal fluid has immunosuppressive characteristics including downregulation of IL-2, IFN- γ , IL-17A and TNF production, inhibitory effect on the generation of Th17 cells in cultures of CD4+ T cells, and inhibition of the NK cell cytotoxic activity of the peripheral blood lymphocytes. These were associated with upregulation of IL-6, IL-10, CCL2, CXCL8 and CXCL9 when compared to controls.
 469. Berlanda 2021 – There is an increased obstetric risk of preterm delivery, neonatal admission to intensive care unit, placenta previa and cesarean delivery. See Chen 2018 and Nirgianakis 2018 hypertension and intra uterine growth retardation.
 470. Farahani 2021 – Royal jelly has antioxidant, anti-tumoral, anti-inflammatory, analgesic, and neuronal protective effects. It can decrease the mean lesion size and the mean pain score in the late phase in rats. See Kubota 2012 for epigenetic activity in bees.
 471. Van Niekerk 2021 – Psychological symptoms accounted for the greatest variance in levels of self-compassion. Depression and anxiety were found to be significant negative predictors of self-compassion. Notable symptoms that were significant in the final model were the presence of dysmenorrhea, lower back pain, dyspareunia, pain after sexual intercourse, fatigue and nausea. Clinical interventions need to be aimed at enhancing self-compassion and to include individual case conceptualization and treatment planning based on endometriosis-related symptomatic profiles. See Armour 2019 for self-care and lifestyle choices.
 472. Bartiromo 2021 – Phytoestrogens have anti-proliferative, anti-angiogenic, anti-inflammatory, pro-apoptotic, and antioxidant properties in endometriosis. They have low estrogenic activity in low-estrogen environments like menopause and antiestrogenic activity in high-estrogen environments such as endometriosis and endometrial cancer.
 473. Marinaro 2021 – Menstrual blood-derived mesenchymal stromal cells can be grown on a polypropylene mesh. See Te Linde 1950 for excised endometrium and Keettel 1951 for viability of cast-off menstrual endometrium.
 474. McNamara 2021 – Endometriosis-associated pain is related to the local effects of the disease, peripheral sensitization, central sensitization, cross organ sensitization, and comorbidities. Comorbid conditions such as bladder pain, irritable bowel, abdomino-pelvic myalgia and vulvodynia compound the problems.
 475. AlAshqar 2021 – Endometriosis is an inflammatory disease with early recruitment of macrophages and neutrophils that secrete cytokine growth factors with proinflammatory, chemotactic, and angiogenic properties, including TNF- α , IL-1, IL-6, IL-8, and vascular endothelial growth factor (VEGF). In addition, excessive amount of retrograde menstruation and subsequent iron overload appear to overwhelm macrophage physiology, triggering aberrant inflammatory signaling and impaired phagocytic potential. This local inflammatory environment favors lesion establishment, progression, and angiogenesis. TNF- α levels and IL-8 are found to correlate with size and number of active lesions, reflecting increased activation of peritoneal macrophages. Furthermore, evidence shows that endometriosis establishes a state of systemic inflammation as evidenced by high serum levels of TNF- α , IL-1 β , and IL-6 in women with the disease. MicroRNAs (miRNA) are hypothesized to alter cytokine expression of serum macrophages distant from the peritoneal lesions. Thus,

endometriosis is no longer perceived as an exclusively local disease of the peritoneum but one of extensive systemic effects.

476. Possover 2021 – Isolated sciatic endometriosis with no connection to the peritoneum was found in 267 (59%) of 452 patients with sciatic endometriosis. Moreover, 36 (54%) of 67 in group 1 had no other evidence of endometriosis. See Possover 2007 for first three patients with no other evidence of endometriosis.
477. Bulun 2021 – Both adenomyosis and endometriosis are oligoclonal tissues that arise from endometrial cell populations carrying a specific driver mutation that most commonly affects the KRAS gene. KRAS mutations may be responsible, in part, for previously observed phenomena such as prolonged cell survival and progesterone resistance in adenomyosis. See Grandi 2016, Flores 2018, Likes 2019, Marquardt 2019, Yilmaz 2019, Donnez 2021, Bulun 2021, Zhang 2023 for progesterone resistance.
478. Maksym 2021 – Immunotherapy, as a tool in the treatment of endometriosis, remains a controversial issue. At present, there are no methods of selective immunotherapy that can be used in routine clinical practice. However, it is believed that immunotherapy may become useful in the treatment of this condition in the future.
479. Metzemaekers 2021 – Pain, fertility, and a strong fear of complications are important deciding factors in the treatment process. Conceiving a child is important, however, doctors emphasize this too much. Complication counseling is frequently about surgical complications, whereas side effects of hormonal treatments are neglected. Deep endometriosis surgery is associated with significant complication rates of up to 14%, which include enterotomy, anastomosis leakage, damage of the urinary tract, fistula formation, and even temporary or permanent colostomy (bowel bag).
480. Kapoor 2021 – ‘Cross talk’ between the biological mechanisms responsible for inducing endometriosis favors cell proliferation and infiltration. Those include inflammation, macrophages, secretion of cytokines, proinflammatory cytokines (interleukin 1, 8, 33, nuclear factor kappa B (NF- κ B) and tumor necrosis factor alpha (TNF α). Apoptotic, autophagic, and tumor-promoting genes/proteins are crucial in the survival of endometriotic cells. E-cadherin, N-cadherin, and B-catenin are regulators of the epithelial–mesenchymal transition. Vascular endothelial growth factor (VEGF) for angiogenesis is at high levels in endometriotic lesions and peritoneal fluid.
481. Gutke 2021 – Pain in the pelvis is often considered normal and inherently linked to being a woman, which in turn leads to insufficiently offered treatment for treatable aspects related to their pain experience. Good pain management strategies and possibly by advocating a healthy lifestyle is appropriate for the acute process and may decrease the risk of chronic pelvic pain and progressive endometriosis. Dietary interventions may potentially have an influence on symptoms in women with endometriosis, but no clinical recommendations can be provided yet.
482. Bougie 2021 – At five years there was significantly less repeat surgery after hysterectomy than after diagnostic or therapeutic laparoscopy. However, the 7.3% difference, 58.6% versus 68.3%, in patients who were seen in the office for pain at five years is not biologically impressive. Moreover, 75.8% had no further surgery after diagnostic laparoscopy with no surgical treatment. A diagnosis may be all some patients and providers need for ongoing management. Just knowing they have endometriosis might be enough to

keep most patients out of future surgery

In the first five years after surgery,

- 58.6% to 68.3% of all groups were seen in the office for pain.
- 10.9% to 23.2% were seen in the ER for pain.
- 0.7% to 3.3% were readmitted for pain.
- 0.4% to 24.2% had additional surgery.
- 0.7% to 8.7% who avoided a hysterectomy at the first surgery had a hysterectomy.
- Hyst and BSO were associated with slightly to moderately better results.

See Lee 2024 for greater improvement after hysterectomy. Note: The data is for populations, not individuals. Some individuals have excellent relief while others worsen. Relief may be better when there is coexistent adenomyosis.

483. Jørgensen 2022 – A molecular signature in endometrial tissue was able to distinguish endometriotic from nonendometriotic patients, implicating uterine natural killer cells in endometriosis. Multivariate modeling incorporating covariation showed separation between subsets of endometriotic and nonendometriotic patients, based predominantly on IP-10, monocyte chemoattractant protein-1, IL-16, and IL-18; this result was independent of cycle and fertility status. Analysis restricted to endometrial tissues from the secretory phase separated endometriotic and nonendometriotic patients by a combination of IL-15, IP-10, monocyte chemoattractant protein-1, IL-16, and IL-18. This combination suggests a uterine natural killer cell defect. See Bedaiwy 2022.
484. Bedaiwy 2022, Abramiuk 2022 – Immunologic dysfunction allows for survival and inhibits the elimination of ectopic endometrial implants contributing to the pathogenesis of endometriosis. Subsequently, the endometriotic implants promote oxidative stress and inflammation associated with the release of various cytokines, chemokines, and growth factors, contributing to the maintenance of the disease and partially explaining its associated symptoms. In addition, endometriotic implants produce immunosuppressive factors that impair the ability of the circulating systemic natural killer cells to eliminate endometrial cells from the peritoneal cavity. This immune dysfunction associated with endometriosis seems not to be limited to the ectopic endometriosis implants, but it extends to the eutopic endometrium as well. Uterine NK (uNK) cells are a special category of NK cells localized in the uterus. uNK cells significantly differ from the peripheral NK cells because their gene expression profile is associated with increased production of cytokines and a relatively low cytotoxic activity. They are more abundant in the secretory phase compared to the follicular phase. In the nonpregnant uterus, uNK cells play key roles in uterine homeostasis, apoptosis, and clearance of senescent cells. During pregnancy, they are involved in implantation, placentation, and pregnancy maintenance. Some of these unique functions are mediated via their role in regulating the remodeling of spiral arteries and fetal-maternal tolerance. As such, uNK modulation by disease states, such as endometriosis, could contribute to the pathophysiology of the disease and could explain some of the associated reproductive morbidities. The activity of NK depends on a fine balance between the activating and inhibiting receptors. Consequently, it is essential to balance the therapeutic benefit of such intervention against any possible unintended side effects.
485. Chang 2022 – Ribosome biogenesis is a cellular process critical for protein homeostasis during cell growth and multiplication and is a potential therapeutic target for treating endometriosis. Drugs that can block ribosome biogenesis include inhibitors against mTOR/PI3K (GSK2126458) and RNA polymerase I (CX5461 and BMH21).

486. Gardella 2022 – Chemokines such as ENA-78, a neutrophil chemotactic factor which activates neutrophils, promotes cytosolic- free calcium changes, and induces neoangiogenesis can cause the development, progression and growth of endometriosis.
487. Huang 2022 – Tetramethylpyrazine, a compound derived from a Chinese herb suppresses platelet-induced EMT, FMT, cellular contractility, and collagen production in a concentration-dependent manner in-vitro. It reduced lesion weight and the extent of lesional fibrosis and improved hyperalgesia in a rat model.
488. Strauß 2022 – Musashi genes have an impact on Notch signaling and the pathogenesis of endometriosis through the downregulation of proliferation, stemness characteristics and the upregulation of apoptosis, necrosis and of the cell cycle regulator p21. These findings suggest the therapeutic potential of targeting the Musashi–Notch axis.
489. Bao 2022 – Shared target genes identified opportunities for repurposing existing immunomodulators, particularly disease-modifying anti-rheumatic drugs (such as TNF, IL6 and IL6R blockades, and JAK inhibitors). Genes highly prioritized only in endometriosis revealed disease-specific therapeutic potentials of targeting neutrophil degranulation – exocytosis that can facilitate metastasis-like spread to distant organs causing inflammatory-like microenvironments. Improved target prioritization, along with an atlas of in silico predicted targets and repurposed drugs (available at <https://23verse.github.io/end>), provides genomic insights into endometriosis, reveals disease-specific therapeutic potentials, and expands the existing theories on the origin of disease.
490. Vargas 2022 – Endometrial receptivity and the endometrial gene expression profile are altered in women with endometriosis, although the changes are small. There was no differential expression of any single molecule in the endometrium of women with endometriosis versus controls. See Lessey 1995, Grandi 2016, Likes 2019, Lessey 2017, and Vargas 2022.
491. Mortlock 2022 – The strong genetic relationship between endometriosis and epithelial ovarian cancers (EOCs) increase our understanding of cross-disorder pathogenesis and yield pleiotropic targets to facilitate potential preventive pharmacological intervention and targeted EOC screening.
492. Leuenberger 2022 – Chronic pain is associated with almost all aspects of daily life, including standing, walking, sitting, defecation, sleep, sports activities, family and domestic responsibilities, sexuality, social functioning, professional life, mood, and joy of life. Altogether, 33.7% of women with chronic pain reported moderate and 27.5% severe limitations. Comorbid pain disorders resulted in significantly more limitations especially for family/domestic responsibilities. See Surrey 2018 and Rumph 2020 for comorbidities review and Vandivier 1998 for team management. See Markovic 2008 and Sachedina 2020 for delay due to normalization of pain. See McNamara 2021 for review of peripheral sensitization, central sensitization, cross organ sensitization, and comorbidities.
493. Bendifallah 2022 – An initial study of 86 microRNAs (miRNAs) found that 10 have the greatest potential value in patients 18 and 43 years. The most accurate blood-based microRNA diagnostic signature for endometriosis provides a sensitivity, specificity, and area under the curve of 96.8%, 100%, and 98.4%, respectively, and is sufficiently robust and reproducible to replace the gold standard of diagnostic surgery.

494. Praetorius 2022, Bulun 2022 – Superficial peritoneal endometriosis, deep infiltrating endometriosis and ovarian endometriomas, removed from the same patient, share the same genetic makeup, suggesting that these various lesion types originate from similar or identical oligoclonal clones of intrauterine endometrial tissue representing an oligoclonal or clonal divergence disease with dissemination likely to consist of multiple epithelial clones traveling together. Activating mutations of KRAS and PIK3CA comprised the majority of the genetic alterations found in nearly half of the tested cases. Identical alterations were found across the lesions in 10 of 27 individuals. Functionally redundant mutations were observed in PIK3CA (activating), CTNNB1 (stabilizing), KRAS (activating) and other Ras pathway-activating mutations were observed in NRAS, ERBB2, and EGFR. More PIK3CA mutations were found than any other. Deep infiltrating endometriosis had a wider spectrum of mutations, with EGFR and ERBB2 mutations observed only in deep infiltrating lesions. Ovarian endometriomas had the highest potential for oligoclonality, whereas deep infiltrating endometriosis lesions were associated with a wider range of mutations. This is consistent with the concept that distinct microenvironments are important for the forming and spreading of lesions. All the complex cases were stage IV. These mutations should be considered important targets for drug development in endometriosis. Future work should consider patient-wide endometriosis mutation profiles, not single lesions.
495. Wüest 2023 – This supports Shafrir et al.'s (2018) conclusion that only those with the most severe symptoms undergo surgery. In spite of the adolescents having significantly higher pain scores for dysmenorrhea (VAS 7.3 vs 6.6; $P = .015$), surgery was recommended for $15.3\% \leq 24$ vs $25.1\% \geq 25$ years. See Markovic 2008, Brosens 2013, Shafrir 2018, Knox 2019, Sachedina 2020, and Simpson 2021.
496. Mistry 2022 – There is a paucity of well-designed trials looking at cannabis. Moreover, cannabis use has a potential for harm including "cannabis use disorder," psychosis, and mood disturbances. At present, national guidance cannot recommend cannabis-based products due to a lack of clear evidence of benefit. See Armour 2019 for patient use.
497. Mikuš 2022 – It was not determined if the CTLA4-based autoimmunity involved in the maintenance of chronic inflammation was a primary determinant of the pathogenesis of endometriosis. There are complex interactions in the immune checkpoint molecules.
498. Chapron 2022 – Chapron et al. used a multiple regression model to analyze clinical symptoms and epidemiological data from a prospective pre-operative patient questionnaire to develop two models to predict the presence of endometriosis. Sensitivities were 78% to 92% and specificities were 62% to 91%. A score based only on a patient questionnaire could allow identification of a population at high risk of endometriosis and might help referral to specialized radiologists for a non-surgical endometriosis scan.
499. Stephens 2022 – “The presence of endometriosis may be a contributing factor to the subsequent development of adenomyosis as a consequence of an altered, systemic inflammatory response.” Epidemiology and experimental studies suggest a role for environmental endocrine disrupting chemicals in the development of endometriosis; a few studies suggest a role of toxicant exposures and adenomyosis.
500. Szukiewicz 2022 – Epigenetic factors and T-cell functions are involved in the origins of endometriosis. Unlike autoimmune diseases, where the immune system attacks the body's own tissues, endometriosis seems to involve a suppression of the immune response, hindering the detection and removal of abnormal endometrial tissue outside the uterus.

Epigenetics can influence gene expression, in both hormonal and immunological anomalies associated with endometriosis. The reversible regulation of regulatory T-cells (Tregs) through epigenetics might enhance the ability to detect and eliminate ectopic endometrial cells, offering a promising approach to treatment. As much of the research on the immunological aspects of endometriosis relies on animal models, their reliability is questioned. T-cell reprogramming could offer a novel therapeutic avenue, potentially minimizing the reliance on animal models in testing.

501. Szukiewicz 2023 – “Phytoestrogens (PEs) are estrogen-like nonsteroidal compounds derived from plants (e.g., nuts, seeds, fruits, and vegetables) and fungi that are structurally similar to 17 β -estradiol. PEs bind to all types of estrogen receptors, including ER α and ER β receptors, nuclear receptors, and a membrane-bound estrogen receptor known as the G protein-coupled estrogen receptor (GPER). As endocrine-disrupting chemicals (EDCs) with pro- or antiestrogenic properties, PEs can potentially disrupt the hormonal regulation of homeostasis, resulting in developmental and reproductive abnormalities. However, a lack of PEs in the diet does not result in the development of deficiency symptoms. To properly assess the benefits and risks associated with the use of a PE-rich diet, it is necessary to distinguish between endocrine disruption (endocrine-mediated adverse effects) and nonspecific effects on the endocrine system.”
502. Papageorgiou 2023 – The availability of single nucleotide polymorphisms (SNPs) associated with endometriosis, provides the opportunity for the study of endometriosis through SNP genomic profiles or disease genomic ‘grammar’ (DGG). The DGG of endometriosis has 296 and six common genetic targets of SNPs with low allele and high allele frequencies, respectively. The variation of the DGG of endometriosis can be contrasted for European, African, American, East Asian, and South Asian populations. These may explain the differences in prevalence and phenotypic subtypes.
503. de Ziegler 2023 – Editorial review concludes that adenomyosis and endometriosis both result from endometrial inflammation and represent variants of one disorder.
504. Lamceva 2023 – Several pathogenetic pathways are considered, including retrograde menstruation, benign metastasis, immune dysregulation, coelomic metaplasia, hormonal disbalance, involvement of stem cells, and alterations in epigenetic regulation. Also discusses environmental and lifestyle factors.
505. Kobayashi 2023a – Women with endometriosis are at increased risk of comorbid PID and vice versa. There is a bidirectional relationship between endometriosis and PID that shares a similar pathophysiology, which includes the distorted anatomy favorable to bacteria proliferation, hemorrhage from endometriotic lesions, alterations to the reproductive tract microbiome, and impaired immune response modulated by aberrant epigenetic processes. See the “[Subtle Inflammatory Lesions](#)” section.
506. Kobayashi 2023b – Kobayashi (2014, 2023a, 2023b) concluded that gut microbiome dysbiosis caused by the imbalance between the commensal and pathogenic microbiomes or reduced microbial diversity dysregulates the bidirectional crosstalk between the gut and uterus, which results in not only immune dysfunction but also altered estrogen signaling. It is not known if infection precedes or follows sterile inflammation.

507. Wang 2023 – Metaplasia, epigenetic changes and genetic changes of tubal epithelium may contribute to ovarian endometriosis like low-grade serous carcinoma via fallopian tube epithelia rather than ovarian surface mesothelia. See Yuan 2014.
508. Zhu 2023 – Glucose oxidase-loaded bovine serum albumin nanoparticles (BSA-GOx-NPs) can be delivered to endometriosis in a neutrophil-dependent manner. This depleted glucose and caused death in endometriotic lesions in a mouse model.
509. Harden 2023 – Peritoneal autoimmunity was found in 12 (46%) of 25 women with endometriosis. The most frequent peritoneal fluid autoantibody target was p53 in 46% of 25 women. It was not postulated whether this was a cause or due to endometriosis.
510. Buggio 2023 – The Second-to-Four Digit Ratio (2D:4D) ratio was significantly higher in women with endometriosis. The 2D:4D ratio has been proposed as a marker of prenatal hormonal exposure with prenatal exposure to androgens resulting in a shorter 2D:4D ratio, whereas a prenatal estrogenic environment results in a longer one. This supports a potential influence of intrauterine hormonal and endocrine disruptors exposure on endometriosis.
511. Falcone 2022 – Large endometriomas may interfere with follicle aspiration, and surgery is sometimes necessary. Surgical removal and sclerotherapy decrease AMH levels. The mechanism is attributed to damage to or removal of normal ovarian tissue. The recurrence rate of endometrioma after sclerotherapy is highest when ethanol was not left in the cyst (“washing” only). Like surgery, a systematic analysis found no benefit of sclerotherapy of an endometrioma before ART compared with no treatment at all.
512. Najdawi 2023 – Najdawi M, et al. used cryoablation to treat abdominal wall endometriosis. The median pain-free survival rate was 93.8% at 6 months and 82.7% after 12 months. One (2.4%) of 42 patients had a second-degree skin burn and peritonitis due to a probable small bowel injury. During follow-up, this patient had no more pain.
513. Zhang 2023 – Abnormal progesterone receptors (PGR) signaling, deficiency of progesterone receptors, chronic inflammation, aberrant gene expression, epigenetic alterations, and environmental toxins are potential molecular causes of progesterone resistance in endometriosis. The same gene encodes PGRs PR-A and PR-B that mediate natural and synthetic progestins. Progesterone resistance in endometriosis depends on lower PR-B levels. PGR can be suppressed by estrogens, DNA hypermethylation, inflammatory response, environmental toxins, progesterone gene polymorphism, micro RNAs, and epithelial-mesenchymal transition. Proinflammatory cytokines interfere with steroid receptor chaperone proteins or receptor coactivators. Epigenetic alterations such as DNA and histone methylation and acetylation and modification of coregulators may also be causes. As hypermethylation contributes to progesterone resistance, one choice could be demethylation agents. Another promising agent is "metformin," which can reverse progestin resistance by regulating the expression of dysregulated genes and mRNAs. See Grandi 2016, Flores 2018, Likes 2019, Marquardt 2019, Yilmaz 2019, Donnez 2021, Bulun 2021, Zhang 2023 for progesterone resistance.
514. van Haaps 2023 – An endometriosis diet positively affected the quality of life (QoL) in all six QoL domains in women diagnosed with endometriosis. Women with strict adherence compared to less strict adherence reported significantly higher scores in all six QoL domains. See Mathias et al. (1998) who found that bacterial overgrowth was associated with endometriosis. This responded to eight weeks of treatment with clonazepam (0.25 mg 3

- times per day) to slow bowel motility, dietary changes, reduction of glycemic carbohydrates, balancing with omega 9 oils, elimination of foods with caffeine and tyramine, and addition of omega 3 fatty acids. There was a significant reduction in the total endometriosis-associated bowel motility score after treatment. Antibiotics were not needed.
515. Muraoka 2023 – Myofibroblasts expressing TAGLN promote endometrial cell survival at ectopic sites. These cells are induced by TGF- β signaling, which can be activated by Fusobacterium infection. Although further studies are needed, our data suggest that targeting Fusobacterium in the endometrium by antibiotic treatment may be a therapeutic option for patients with endometriosis.
516. Schuurman 2023 – Embracing complexity: Sepsis involves the dynamic interplay between a pathogen, the host response, the failure of organ systems, medical interventions, and a myriad of other factors. This together results in a complex, dynamic, and dysregulated state that has remained ungovernable thus far. While it is generally accepted that sepsis is very complex indeed, the concepts, approaches and methods that are necessary to understand this complexity remain underappreciated. See Law 2004 for our vague, elusive, diffuse, slippery, emotional, and indistinct kaleidoscope world.
517. Hall 2023 – Concentrations of urinary cadmium, a long-term biomarker (10–30 years) of cadmium exposure are associated with an increased prevalence of endometriosis. Cadmium can bind to estrogen receptors and increases endometrial proliferation in in vitro and in vivo studies. Environmental exposure is through the inhalation of cigarette smoke and consumption of industrial process contaminated foods such as leafy vegetables, root vegetables, grains, and soybeans. See Rier 1993, Rier 1995, Rier 2001 (TCDD), Caserta 2008, Smarr 2016, Bruner-Tran 2016, Peinado 2020 (bisphenols), and Rumph 2020 for endocrine disrupting chemicals. See Umezawa 2011 for diesel fuel toxicology; Huang 2016 for comparison of dioxin-like and non-dioxin-like polychlorinated biphenyls (PCBs); Liang 2016, 2018, & 2019 for estrogen interactions; Holder 2014, Simon 2015, and Brenhouse 2016 for neuroimmune maturation; and Hall 2023 for cadmium.
518. Klipstein 2023 – Hope is a strong motivator, and a necessary element when pursuing a treatment with an uncertain outcome. If patients lack hope, they may forego treatments which would lead to their desired reproductive goals. On the other hand, outsized optimism can lead to significant disappointment and poor decision-making regarding treatment choices. Physicians can help patients conceptualize the space between these 2 extremes by presenting a picture of the range of potential outcomes and their likelihood of occurring.
519. Coxon 2023 – Endometriosis-associated pain has been considered as a nociceptive ‘end-organ’ disease related to nodules, cysts, or other lesions. More recently, it has been recognized that a multidisciplinary approach to management is optimal for chronic pain, including medication, surgery and other interventional procedures combined with holistic care, complementary medicine, and physical and psychological therapies.
520. Goriel 2023 – Endometriosis has complications if treatment is delayed. Goriel et al. reported the progression of endometriosis causing obstruction of the colon that resulted in rupture and septic shock. She had the partial removal of her bowel, a colostomy bag, and two subsequent surgeries in five days. She was able to eat 11 days after the first operation.
521. Wei 2023 – Similarities between endometriosis (EMs) and irritable bowel syndrome or inflammatory bowel disease (IBS) include recurrent abdominal pain, cramping, anxiety, and

a local inflammatory microenvironment in lesions. Patients with EMs in a large-scale study had a 50% increased risk of inflammatory bowel disease (IBD), including ulcerative colitis and Crohn's disease, compared with the general population. Growing evidence has linked dysbiosis and immune activation with IBD and IBS. Difference in α and β diversity was found between patients with EMs and controls. β -Glucuronidase promoted EMs development directly or indirectly by causing macrophage dysfunction.

522. Li 2023 – Endometriosis is associated with higher odds of metabolic syndrome (OR = 1.55). After adjusting for hysterectomy or oophorectomy, the general association was not statistical significant, but triglyceride (TG) (β = 0.38, 95%CI: 0.06–0.70).
523. Salmeri 2023 - A growing number of diseases, including irritable bowel syndrome and endometriosis, have been characterized by distinctive changes in the composition and functionality of the gut microbiota. Whether microbiota changes are a cause, consequence, or incidental factor in these diseases remains largely uncertain. Does an imbalance in the microbiome precipitate complex diseases such as endometriosis and IBS, or is it a byproduct of the disease state or merely an incidental factor?
524. De La Riva-Morales 2023 - Iatrogenic endometriosis of the breast mimicking fat necrosis was found after fat from an area near previous abdominal wall endometriosis was used as part of a breast reconstruction.
525. Knez 2023 – Knez et al. retrospectively analyzed 135 (19%) of 725 premenopausal women median age 40 years (range 26–53) with moderate or severe endometriosis on two or more pelvic ultrasounds over a median of 1.8 years (Range = 0.52 -8.2 years). Follow-up was based on clinical symptoms and desire to avoid surgery. 37% developed additional nodules or experienced an increase in nodule size. 13% had regression in the number or size of the nodules and 50% remained static.
526. Hardman 2023a – Robotic-integrated ultrasound can provide additional information including size and depth of bowel endometriosis lesions, which can play a role in surgical decision making. A double discoid excision of multifocal rectosigmoid endometriosis with the use of robotic-integrated ultrasound is a technique that can avoid the need for segmental bowel resection.
527. Hardman 2023b – Intraoperative robotic integrated ultrasound facilitated robotic excision of isolated deep infiltrating endometriosis on the sigmoid colon in the absence of posterior cul de sac obliteration.
528. Hunsche 2023 – Hunsche et al. in a survey of symptomatic women present the unique impacts of endometriosis symptoms: *“physical, activities of daily living, social, sleep, emotional, appearance, financial, sex-related, work/school-related, fertility, and cognitive. Over 70% of the respondents to their poll encountered detrimental effects on their physical well-being. More than 90% of the women reported they had difficulties in their daily leisure activities and had trouble socializing. Almost all women stated they had sleep issues.”* They also reported other adverse effects on *“their emotional well-being, body image, financial situation, romantic relationships, ability to attend work or school, productivity, and, lastly, their fertility.”* Edmunds reported a different perspective in “asymptomatic” women. (Edmonds 2023)
529. Edmonds 2023 – Conflicting observations are that endometriosis can be pain free, but “asymptomatic” patients can have normalized pain, swelling, and infertility. In addition,

pain is not always menstrual; it can be ovulatory or sporadic. Of 37 women who self-identified as being “asymptomatic,” “15 reported zero menstrual pain whatsoever, including eight with infertility and seven with cysts. As for the remaining 22 patients, it appears pain was present in some form, ranging from mild to severe pain. This means more than half actually had varying degrees of pain.” Five of those with cysts had acute unilateral pain and tenderness with the cyst. The other two had only distension and swelling with the cyst. Other studies have found endometriosis incidentally on yearly exams and at tubal ligation.

530. Cirillo 2023 – Cirillo et al. found that a Mediterranean Diet decreased endometriosis-associated pain perception in terms of pain with sex, non-menstrual pelvic pain, painful urination, and painful bowel movements. Oxidative stress was also decreased.
531. Pedrassani 2023 – Pedrassani et al. (2023) published the sonographic appearance of various forms of superficial endometriosis and reviewed the literature including Leonardi et al.’s sonoPODography. In highly specialized centers, sensitivity and specificity of the sonoPODography technique were 65% and 100%. They had no look-a-like lesions or cancers, but the psammoma bodies, hemangiomas, epithelial inclusions, peritoneal ectopic pregnancy implantation, and metastatic breast cancer in Martin (LAECA 1990) had the same configuration as some of their images. See Leonardi 2020a and 2020b
532. Utkarsh 2023 – Extracellular vesicles (EVs) help cell-to-cell communication by transporting protein, lipids, and nucleic acids. EVs appear to be essential for the development of endometriosis. They may be important in developing surgical and pharmacological treatment, non-invasive diagnostics, and drug delivery systems.
533. Muraoka 2023 – In a cohort of women with ovarian endometriomas, 64% of patients with endometriosis but <10% of controls were found to have *Fusobacterium* infiltration in the endometrium. Activated transforming growth factor- β (TGF- β) signaling resulting from *Fusobacterium* infection of endometrial cells led to the transition from quiescent fibroblasts to TAGLN (TAGLN)-positive myofibroblasts, which gained the ability to proliferate, adhere, and migrate in vitro. In a subsequent mouse study, *Fusobacterium* inoculation resulted in a marked increase in TAGLN-positive myofibroblasts and increased number and weight of endometriotic lesions. Furthermore, antibiotic treatment largely prevented establishment of endometriosis and reduced the number and weight of established endometriotic lesions in the mouse model. Clinical studies are needed to determine if antibiotic treatment against *Fusobacterium* will be effective in humans.
DCM note: Since this involves the transition from quiescent fibroblasts to myofibroblasts, antibiotics may not be effective in established fibrotic lesions; that means many/most ovarian, most peritoneal, and all deep infiltrating endometriosis. That may also be before it can be seen at laparoscopy. In those women, surgery may be worthless. Until we have a non-invasive test for early endometriosis, culturing the endometrium or empirical antibiotics might be considered for persistent dysmenorrhea without a firm diagnosis. A study is needed to see if urinary PCR or a similar test can diagnose *Fusobacterium*. If so, urinary testing would be a first-line test and is more reasonable and acceptable than an endometrial culture or empirical antibiotics.
534. Marla 2023 – The gene expression profiles could distinguish lesion subtypes with endometrioma significantly differentiating from both superficial peritoneal lesions and deeply infiltrating lesions. The target receptor estrogen receptor 2 (ESR2) was differentially

expressed in endometriomas and varied significantly between medicated and non-medicated samples.

535. Guo 2023 – The theory “*that endometriosis is likely a result of maladaptation of the evolutionary baggage to dramatically changed societies and cultures*” “*does not explain the gaping divide between the near-ubiquity of retrograde menstruation and the moderate prevalence of endometriosis. Granted, rapid societal and cultural changes have resulted in far more menstrual periods, but these changes are presumably sweeping and across the board. If all women in modern societies experience these changes, why do only approximately 10% of them have endometriosis?*” This questions “*the validity of the genetic approach aiming to find endometriosis-predisposing genes. After years of painstaking work, the putative loci identified (>40) can only explain approximately 2% of disease variance.*” This means “*that the vast majority of causes (>98%) are*” “*not accounted for by hereditary factors.*”
536. Mackenzie 2023 – Mackenzie et al. point out that there is limited evidence supporting excision or ablation for superficial peritoneal endometriosis. Their trial uses three arms to study excision, ablation, and diagnosis only in the management of endometriosis. See Bougie et al. (2021).
537. Petraglia 2024 – Modern management:
- The diagnostic workup should include the family history (including genetic and epigenetic factors), the clinical presentation, an accurate gynecological examination, and an imaging evaluation (transvaginal ultrasound and/or magnetic resonance) performed by expert practitioners.
 - A diagnosis of endometriosis should be suspected among adolescents and young women with severe dysmenorrhea, interfering with daily activities and not responding to analgesic drugs.
 - For patients without immediate desire of pregnancy, hormonal drugs are first line choices for treating endometriosis-related pain, aiming to reduce menstruation frequency and even abolishing any bleeding.
 - Progestins or continuous combined oral contraceptives are used for long term treatments and should be prescribed as first-line treatment.
 - In case of failure or intolerance, GnRH analogs or more recently oral GnRH antagonists may be proposed (with or without an add-back therapy).
 - Laparoscopic should include plans for treatment and should not be performed with the sole purpose of diagnosing endometriosis.
 - Surgery remains an important treatment option, but it should be performed at the right time, as a single operation, preferentially in referral centers by dedicated multidisciplinary teams in order to avoid recurrences and/or repetitive surgery.
 - Assisted reproductive technology (ART) is an option for treating endometriosis-related infertility either as first line approach, or after surgical approach.
 - Fertility preservation can be discussed at the time of diagnosis or before performing surgery when indicated.
538. Bourdon 2024 – A meta-analysis of 19 studies revealed no significant differences in live birth rates, ongoing pregnancy rates, or early pregnancy loss when comparing patients who

- underwent endometriosis surgery before IVF/ICSI. After excluding studies with high risks of bias, the live birth rates per cycle were significantly reduced in cases with surgical treatment before IVF/ICSI. Clinicians must weigh the pros and cons of surgery before IVF.
539. Liang 2024 – Liang et al. add to reports of misdiagnosing rectal endometriosis as rectal malignancy. This was based on a barium enema and three colonoscopies with biopsies. They also review cervical, vulvar, Bartholin, nasolacrimal, anal, umbilical, abdominal wall, renal, hepatic, muscular, pulmonary, diaphragmatic, para-aortic, pericardial, and knee locations. They update information on increasingly sensitive CT and MRI imaging that can help prepare surgeons for the expected findings at surgery. Furthermore, new advances in intestinal endoscopic techniques add to diagnostic possibilities and preoperative planning. See Martin 1999 for endometriosis diagnosed as rectosigmoid cancer on a barium enema. In addition, I (DCM) have assisted on a diverting colostomy for a 4 cm appendiceal endometriotic nodule that looked like cancer.
540. Alson 2024 – The presence of DIE and/or endometrioma diagnosed by TVUS lowers the chance for a live birth in women undergoing their first IVF/ICSI treatment by 37%. There was no data on treatment.
541. Lee 2024 – Lee et al. found that hysterectomy had significantly greater improvement in quality of life than conservative surgery. This was independent of age and stage. See Bougie 2021 for post op pain that was better but similar for hysterectomy compared to therapeutic or diagnostic laparoscopy. Note: The data is for populations, not individuals. Some individuals have excellent relief while others worsen. Relief may be better when there is coexistent adenomyosis.
542. Zippel 2024 – Endometriosis is more than pain, pelvic symptoms, and infertility. It includes anxiety, depression, sexual dysfunction, and eating disorders. Pain, especially chronic pelvic pain, likely serves as a mediating factor. A shared genetic predisposition may exist for endometriosis and mental health disorders. A proactive holistic approach should emphasize prompt diagnosis, targeted medical interventions, psychological support, supportive relationships, and improving the patient's quality of life. DCM note: "Prompt diagnosis" can be clinical or treating all dysmenorrhea and pelvic pain as possible endometriosis.
543. Khashchenko 2024 – Khashchenko et al. found differential expression of markers of proliferation (ER β), glycolysis (MCT2, PDK1, Glut1, Hex2, TGF β and Hif-1 α), mitochondrial biogenesis (OPA1, DRP1) and autophagy (P38, Beclin1 and Bnip3) and apoptosis markers (Bcl2/Bax) indicate microenvironment modification, mitochondrial biogenesis, estrogen receptor activation and glycolytic switch along with apoptosis suppression in peritoneal endometrioid foci already in adolescents.
544. Sen 2024 – g A surrogate analysis of epidemiological and mechanistic studies concluded that “multiple environmental toxicants may play a role in the etiology of obesity and insulin resistance. These effects may arise from disruptions in the microbial biosynthesis of secondary bile acids.”

References (alphabetical)

- Abbott JA, Kho R. An abundance of studies but dearth of evidence regarding endometriosis and adenomyosis. *J Minim Invasive Gynecol*. 2020 Feb;27(2):241-243. doi: 10.1016/j.jmig.2019.12.003. Epub 2019 Dec 5. PMID: 31812611.
- Abbott RD, Sadowski A, Alt AG. Efficacy of the autoimmune protocol diet as part of a multi-disciplinary, supported lifestyle intervention for Hashimoto's thyroiditis. *Cureus*. 2019 Apr 27;11(4):e4556. doi: 10.7759/cureus.4556. PMID: 31275780; PMCID: PMC6592837. Open Access: <https://www.cureus.com/articles/18455>
- Alberico D, Somigliana E, Bracco B, Dhouha D, Roberto A, Mosconi P, Facchin F, Vercellini P. Potential benefits of pregnancy on endometriosis symptoms. *Eur J Obstet Gynecol Reprod Biol*. 2018 Nov;230:182-187. doi: 10.1016/j.ejogrb.2018.08.576. Epub 2018 Aug 22. PMID: 30308401.
- Abo C, Moatassim S, Marty N, Saint Ghislain M, Huet E, Bridoux V, Tuech JJ, Roman H. Postoperative complications after bowel endometriosis surgery by shaving, disc excision, or segmental resection: a three-arm comparative analysis of 364 consecutive cases. *Fertil Steril*. 2018 Jan;109(1):172-178.e1. doi: 10.1016/j.fertnstert.2017.10.001. PMID: 29307394. Open Access: [https://www.fertstert.org/article/S0015-0282\(17\)31969-6/fulltext](https://www.fertstert.org/article/S0015-0282(17)31969-6/fulltext)
- Abramiuk M, Grywalska E, Małkowska P, Sierawska O, Hryniewicz R, Niedźwiedzka-Rystwej P. The role of the immune system in the development of endometriosis. *Cells*. 2022 Jun 25;11(13):2028. doi: 10.3390/cells11132028. PMID: 35805112; PMCID: PMC9265783. Open Access: <https://www.mdpi.com/2073-4409/11/13/2028>
- Abrão MS, Petraglia F, Falcone T, Keckstein J, Osuga Y, Chapron C. Deep endometriosis infiltrating the recto-sigmoid: critical factors to consider before management. *Hum Reprod Update*. 2015, 21(3):329-39. doi: 10.1093/humupd/dmv003. PMID: 25618908. Open Access: <https://academic.oup.com/humupd/article/21/3/329/676306?login=false>
- Abu-Hijleh MF, Habbal OA, Moqattash ST. The role of the diaphragm in lymphatic absorption from the peritoneal cavity. *J Anat*. 1995, 186:453-67. PMID: 7559120
PMC: <http://www.ncbi.nlm.nih.gov/pmc/articles/pmc1167005/>
- Acién P, Bataller A, Fernandez F, Acién MI, Rodriguez JM, Mayol MJ. New cases of accessory and cavitated uterine masses (ACUM): a significant cause of severe dysmenorrhea and recurrent pelvic pain in young women. *Hum Reprod* 2012, 27:683-694. PMID: 22252088. Open Access DOI: <https://doi.org/10.1093/humrep/der471>
- Adamson GD, Pasta DJ. Surgical treatment of endometriosis-associated infertility: meta-analysis compared with survival analysis. *Am J Obstet Gynecol*. 1994, 171(6):1488-504; discussion 1504-5. PMID:7802058. DOI: [https://doi.org/10.1016/0002-9378\(94\)90392-1](https://doi.org/10.1016/0002-9378(94)90392-1)
- Adamson GD, Pasta DJ. Endometriosis fertility index: the new, validated endometriosis staging system. *Fertil Steril*. 2010, 94(5):1609-1615. PMID: 19931076
Open Access DOI: <https://doi.org/10.1016/j.fertnstert.2009.09.035>
- Adamyán L. Additional international perspectives. In: Nichols DH, ed. *Gynecologic and Obstetric Surgery*. St. Louis: Mosby Year Book Medical Publishers, 1993, pp 1167-82.

Agarwal A (Amit), Gupta S, Sharma R. Role of oxidative stress in female reproduction. *Reprod Biol Endocrin* 2005, 3:28. <http://www.rbej.com/content/3/1/28>
Open Access: <https://rbej.biomedcentral.com/articles/10.1186/1477-7827-3-28>

Agrawal A (Ashok), Shetty BJP, Makannavar JH, et al. Intramedullary endometriosis of the conus medullaris: Case report. *Neurosurg* 2006, 59(428):1-3.
<https://doi.org/10.1227/01.NEU.0000223375.23617.DC>

Agarwal S (Swati), Tapmeier T, Rahmioglu N, Kirtley S, Zondervan K, Becker C. The miRNA Mirage: How close are we to finding a non-invasive diagnostic biomarker in endometriosis? A systematic review. *Int J Mol Sci*. 2018, 19, 599. doi:10.3390/ijms19020599 PMID: 29463003
PMC Open Access: <https://www.ncbi.nlm.nih.gov/pmc/articles/PMC5855821/>

Akoum A, Metz CN, Al-Akoum M, Kats R. Macrophage migration inhibitory factor expression in the intrauterine endometrium of women with endometriosis varies with disease stage, infertility status, and pelvic pain. *Fertil Steril*. 2006, 85(5):1379-85.

Alson S, Henic E, Jokubkiene L, Sladkevicius P. Endometriosis diagnosed by ultrasound is associated with lower live birth rates in women undergoing their first IVF/ICSI treatment. *Fertil Steril*. 2024 Jan 19:S0015-0282(24)00026-8. doi: 10.1016/j.fertnstert.2024.01.023. Epub ahead of print. PMID: 38246403. Open Access: <https://doi.org/10.1016/j.fertnstert.2024.01.023>

Akter S, Xu D, Nagel SC, Bromfield JJ, Pelch K, Wilshire GB, Joshi T. Machine learning classifiers for endometriosis using transcriptomics and methylomics data. *Front Genet*. 2019 Sep 4;10:766. doi: 10.3389/fgene.2019.00766. eCollection 2019. PMID: 31552087, PMC Open Access: <https://www.ncbi.nlm.nih.gov/pmc/articles/PMC6737999/>

Alali Z, Graham A, Swan K, Flyckt R, Falcone T, Cui W, Yang X, Christianson J, Nothnick WB. 60S acidic ribosomal protein P1 (RPLP1) is elevated in human endometriotic tissue and in a murine model of endometriosis and is essential for endometriotic epithelial cell survival in vitro. *Molecular Human Reproduction*, 2020, 26(1): 53-64. PMID: 31899515
DOI: <https://doi.org/10.1093/molehr/gaz065>

AlAshqar A, Reschke L, Kirschen GW, Borahay MA. Role of inflammation in benign gynecologic disorders: from pathogenesis to novel therapies†. *Biol Reprod*. 2021 Jul 2;105(1):7-31. doi: 10.1093/biolre/iaab054. PMID: 33739368; PMCID: PMC8256101.
PMC open access: <https://www.ncbi.nlm.nih.gov/pmc/articles/PMC8256101/>

Albee RB, Sinervo K, Fisher DT. Laparoscopic excision of lesions suggestive of endometriosis or otherwise atypical in appearance: relationship between visual findings and final histologic diagnosis. *J Minimal Invasive Gynecol* 2008, 15:32-37

Alenezi S, Zaheer M, Khudair S. Intrinsic unilateral ureteral endometriosis: A rare case report. *International Journal of Surgery Case Reports*. 2023, 104, 107966, DOI: <https://doi.org/10.1016/j.ijscr.2023.107966>.
Open Access: <https://www.sciencedirect.com/science/article/pii/S2210261223000949>

Alifano M, Trisolini R, Cancellieri A and Regnard JF. Thoracic Endometriosis: Current Knowledge. *Ann Thorac Surg*. 2006; 81:761-769.
<https://doi.org/10.1016/j.athoracsur.2005.07.044>

Alio L, Angioni S, Arena S, et al. When more is not better: 10 'don'ts' in endometriosis management. An ETIC* position statement. *Hum Reprod Open*. 2019 Jun 12;2019(3):hoz009.

doi: 10.1093/hropen/hoz009. eCollection 2019. <https://www.ncbi.nlm.nih.gov/pubmed/31206037>
Open access <https://www.ncbi.nlm.nih.gov/pmc/articles/PMC6560357/>

Alkhateeb HM, Yaseen EM. Twin pregnancy in an accessory cavitated non-communicating uterus. *Int J Surg Case Rep.* 2015, 10: 45–48. doi: 10.1016/j.ijscr.2015.03.023. PMID: 25813124. PMC Open Access: <https://www.ncbi.nlm.nih.gov/pmc/articles/PMC4429854/>

American College of Obstetricians and Gynecologists. ACOG Committee Opinion. Number 310, April 2005. Endometriosis in adolescents. *Obstet Gynecol.* 2005 Apr;105(4):921-7. doi: 10.1097/00006250-200504000-00058. PMID: 15802438.

American College of Obstetricians and Gynecologists. Practice bulletin no. 114: Management of endometriosis. *Obstet Gynecol.* 2010 Jul;116(1):223-236. doi: 10.1097/AOG.0b013e3181e8b073. PMID: 20567196.

American Gynecological Society Transactions, The American Gynecological Society, Fiftieth Annual Meeting, Washington, DC, May 4,5, and 6. 1925. *Am J Obstet Gynecol* 1925, 10(5):730-738. DOI: [https://doi.org/10.1016/S0002-9378\(25\)90643-6](https://doi.org/10.1016/S0002-9378(25)90643-6)

American Fertility Society classifications 1979 and 1985: See “The American Fertility Society.”

American Society for Reproductive Medicine (ASRM). Revised American Society of endometriosis: 1996 for Reproductive Medicine classification. *Fertil Steril* 1997, 67(5):817-21

Angioni S, Peiretti M, Zirone M, Palomba M, Mais V, Gomel V, Melis GB. Laparoscopic excision of posterior vaginal fornix in the treatment of patients with deep endometriosis without rectum involvement: surgical treatment and long-term follow-up. *Hum Reprod* 2006, 21(6):1629-1634. PMID: 16495305 <https://doi.org/10.1093/humrep/del006>,
<https://academic.oup.com/humrep/article/21/6/1629/724238>,
<https://www.researchgate.net/publication/7282641>

Angioni S, D'Alterio MN, Coiana A, Anni F, Gessa S, Deiana D. Genetic characterization of endometriosis patients: Review of the literature and a prospective cohort study on a Mediterranean population. *Int J Mol Sci* 2020, 21, 1765. <https://doi.org/10.3390/ijms21051765>

Anglesio MS, Papadopoulos N, Ayhan A, Nazeran TM, Noë M, Horlings HM, Lum A, Jones S, Senz J, Seckin T, Ho J, Wu RC, Lac V, Ogawa H, Tessier-Cloutier B, Alhassan R, Wang A, Wang Y, Cohen JD, Wong F, Hasanovic A, Orr N, Zhang M, Popoli M, McMahon W, Wood LD, Mattox A, Allaire C, Segars J, Williams C, Tomasetti C, Boyd N, Kinzler KW, Gilks CB, Diaz L, Wang TL, Vogelstein B, Yong PJ, Huntsman DG, Shih IM. Cancer-Associated Mutations in Endometriosis without Cancer. *N Engl J Med.* 2017 May 11;376(19):1835-1848. doi: 10.1056/NEJMoa1614814. PMID: 28489996; PMCID: PMC5555376.
<https://www.ncbi.nlm.nih.gov/pmc/articles/PMC5555376/>

Aoyagi Y, Nasu K, Kai K, Hirakawa T, Okamoto M, Kawano Y, Abe W, Tsukamoto Y, Moriyama M, Narahara H. Decidualization Differentially Regulates microRNA Expression in Eutopic and Ectopic Endometrial Stromal Cells. *Reprod Sci.* 2017 Mar;24(3):445-455.

Arévalo N, Méndez R. "Mushroom cap" sign in deep rectosigmoid endometriosis. *Abdom Radiol (NY).* 2018 Nov;43(11):3201-3203. doi: 10.1007/s00261-018-1596-y. PMID: 29619523.

Armour M, Sinclair J, Chalmers KJ, Smith CA. Self-management strategies amongst Australian women with endometriosis: a national online survey. *BMC Complement Altern Med.* 2019,

15;19(1):17. doi: 10.1186/s12906-019-2431-x. PMID: 30646891; PMCID: PMC6332532. Open Access: <https://www.ncbi.nlm.nih.gov/pmc/articles/PMC6332532/>

Arosh JA, Banu SK. Dual inhibition of ERK1/2 and AKT pathways is required to suppress the growth and survival of endometriotic cells and lesions. *Mol Cell Endocrinol*. 2018 Dec 19. pii: S0303-7207(18)30364-2.

Arrington J. My Movie. 20 June 2020. Nodules at 0.59 and 1.25 at YouTube at <https://www.youtube.com/watch?v=G0TCB7FZltU&t=3s>

Arya S, Burks HR. Juvenile cystic adenomyoma, a rare diagnostic challenge: Case Reports and literature review, *F&S Reports*. 2021, <https://doi.org/10.1016/j.xfre.2021.02.002>. Open Access: <https://www.sciencedirect.com/science/article/pii/S2666334121000064>

As-Sanie S, Kim J, Schmidt-Wilcke T, Sundgren PC, Clauw DJ, Napadow V, Harris RE. Functional connectivity is associated with altered brain chemistry in women with endometriosis-associated chronic pelvic pain. *J Pain*. 2016 Jan;17(1):1-13. doi: 10.1016/j.jpain.2015.09.008. Epub 2015 Oct 9. PMID: 26456676; PMCID: PMC4698023. Open access: <https://www.ncbi.nlm.nih.gov/pmc/articles/PMC4698023/>

As-Sanie S, Black R, Giudice LC, Gray Valbrun T, Gupta J, Jones B, Laufer MR, Milspaw AT, Missmer SA, Norman A, Taylor RN, Wallace K, Williams Z, Yong PJ, Nebel RA. Assessing research gaps and unmet needs in endometriosis. *Am J Obstet Gynecol*. 2019 Aug;221(2):86-94. doi: 10.1016/j.ajog.2019.02.033. Epub 2019 Feb 18. PMID: 30790565.

ASRM, see *American Society for Reproductive Medicine (ASRM)*.

Attar E, Bulun SE. Aromatase and other steroidogenic genes in endometriosis: translational aspects. *Hum Reprod Update*. 2006a Jan-Feb;12(1):49-56. doi: 10.1093/humupd/dmi034. Epub 2005 Aug 25. PMID: 16123052.

Open Access: <https://academic.oup.com/humupd/article/12/1/49/607182>

Attar E, Bulun SE. Aromatase inhibitors: the next generation of therapeutics for endometriosis? *Fertil Steril*. 2006 May;85(5):1307-18. doi: 10.1016/j.fertnstert.2005.09.064. PMID: 16647373. Open Access: [https://www.fertstert.org/article/S0015-0282\(06\)00228-7/fulltext](https://www.fertstert.org/article/S0015-0282(06)00228-7/fulltext)

Badawy SZ, Cuenca V, Marshall L, Munchback R, Rinas AC, Coble DA. Cellular components in peritoneal fluid in infertile patients with and without endometriosis. *Fertil Steril*. 1984, 42(5):704-708. PMID: 6208058

Badescu A, Roman H, Aziz M, Puscasiu L, Molnar C, Huet E, Sabourin JC, Stolnicu S. Mapping of bowel occult microscopic endometriosis implants surrounding deep endometriosis nodules infiltrating the bowel. *Fertil Steril*. 2016 Feb;105(2):430-4.e26. doi: 10.1016/j.fertnstert.2015.11.006. Epub 2015 Nov 21. PMID: 26613653.

Badescu A, Roman H, Barsan I, Soldea V, Nastasia S, Aziz M, Lucan M, Puscasiu L, Stolnicu S. Patterns of bowel invisible microscopic endometriosis reveal the goal of surgery: Removal of visual lesions only. *J Minim Invasive Gynecol* 2018, 25(3):522-527.e9. doi: 10.1016/j.jmig.2017.10.026. PMID: 29097234

Bafort C, Beebeejaun Y, Tomassetti C, Bosteels J, Duffy JM. Laparoscopic surgery for endometriosis. *Cochrane Database Syst Rev*. 2020 Oct 23;10(10):CD011031. doi: 10.1002/14651858.CD011031.pub3. PMID: 33095458; PMCID: PMC8428328.

Balas EA. From appropriate care to evidence-based medicine. *Pediatr Ann.* 1998 Sep;27(9):581-4. doi: 10.3928/0090-4481-19980901-11. PMID: 9778710.

Balas EA, Boren SA. Managing clinical knowledge for health care improvement. in Bemmell J, McCray AT (eds). *Yearbook of Medical Informatics 2000: Patient-Centered Systems*, Schattauer, Stuttgart, Germany. 2000, pp. 65-70.

Balasz J, Creus M, Fabregues F, et al. Visible and non-visible endometriosis at laparoscopy in fertile and infertile women and in patients with chronic pelvic pain: a prospective study. *Hum Reprod* 1996;11:387-91.

Bałkowiec M, Maksym RB, Włodarski PK. The bimodal role of matrix metalloproteinases and their inhibitors in etiology and pathogenesis of endometriosis (Review). *Mol Med Rep.* 2018 Sep;18(3):3123-3136. doi: 10.3892/mmr.2018.9303. Epub 2018 Jul 23. PMID: 30066912; PMCID: PMC6102659.

Open Access: <https://www.spandidos-publications.com/10.3892/mmr.2018.9303>

Ballweg ML. Big picture of endometriosis helps provide guidance on approach to teens: comparative historical data show endo starting younger, is more severe. *J Pediatr Adolesc Gynecol.* 2003 Jun;16(3 Suppl):S21-6. doi: 10.1016/s1083-3188(03)00063-9. PMID: 12742183.

Bao C, Wang H, Fang H. Genomic Evidence Supports the Recognition of Endometriosis as an Inflammatory Systemic Disease and Reveals Disease-Specific Therapeutic Potentials of Targeting Neutrophil Degranulation. *Front Immunol.* 2022 Mar 23;13:758440. doi: 10.3389/fimmu.2022.758440. PMID: 35401535; PMCID: PMC8983833.

Open Access: <https://www.frontiersin.org/articles/10.3389/fimmu.2022.758440/full>

Baranov V, Malysheva O, Yarmolinskaya M. Pathogenomics of Endometriosis Development. *Int. J. Mol. Sci.* 2018, 19, 1852, DOI:10.3390/ijms1907185

Barton-Smith P. An Investigation of the Surgical Treatment of Endometriosis. MD Thesis. 2010. University of Surrey, UK. Page 130 Table 35.

http://epubs.surrey.ac.uk/804337/1/_homes.surrey.ac.uk_home_System_Desktop_Barton-Smith2010.pdf

Bartiromo L, Schimberni M, Villanacci R, Ottolina J, Dolci C, Salmeri N, Viganò P, Candiani M. Endometriosis and phytoestrogens: Friends or Foes? A Systematic Review. *Nutrients.* 2021, 24;13(8):2532. doi: 10.3390/nu13082532. PMID: 34444692; PMCID: PMC8398277.

Open Access: <https://www.ncbi.nlm.nih.gov/labs/pmc/articles/PMC8398277/>

Bas-Esteve E, Pérez-Arguedas M, Guarda-Muratori GA, Acién M, Acién P. Endometriosis and ovarian cancer: Their association and relationship. *Eur J Obstet Gynecol Reprod Biol X.* 2019 May 22;3:100053. doi: 10.1016/j.eurox.2019.100053. PMID: 31404281; PMCID: PMC6687431.

Bazot M, Daraï E. Sonography and MR imaging for the assessment of deep pelvic endometriosis. *J Minim Invasive Gynecol.* 2005 Mar-Apr;12(2):178-85; quiz 177, 186. doi: 10.1016/j.jmig.2005.01.014. PMID: 15904628.

Batt RE. Minimal endometriosis treatment and relationship to infertility. Presented at the Congress on Obstetrics and Gynecology, Beijing, June 19, 1985. This was summarized by Batt at the 2015 EFA meeting. <https://www.endofound.org/video/ronald-batt-md-mullerianosis-embryonic-endometriosis-adenomyosis-endosalpingiosis-and-endocervicosis/1254>

Batt RE, Smith RA, Buck GM, Naples JD, Severino MF. A case series - peritoneal pockets and endometriosis: rudimentary duplications of the Mullerian system. *Adolesc Pediatr Gynecol* 1989, 2:47-56.

Batt RE. A compass for understanding endometriosis (To the Editor). *Fertil Steril* 2000, 73(1):179. PMID: 10632440. DOI: [https://doi.org/10.1016/s0015-0282\(99\)00477-x](https://doi.org/10.1016/s0015-0282(99)00477-x)

Batt RE, Mitwally MF. Endometriosis from thelarche to midteens: pathogenesis and prognosis, prevention and pedagogy. *J Pediatr Adolesc Gynecol*. 16: 333-347, 2003

Batt RE, Yeh J, Smith RA, Martin D, Chapron C. Intramedullary Endometriosis of the Conus Medullaris: Case Report. *Neurosurg* 2007 60(3): e582. 10.1227/01.NEU.0000255369.03981.0A

Batt RE. Emergence of endometriosis in North America a study in the history of ideas. In: Department of History. Ph.D. (History) Thesis. Buffalo: Graduate School of The University at Buffalo, State University of New York, 2008. <https://search.proquest.com/docview/250811457>

Batt RE, ed. *A History of Endometriosis*. London: Springer-Verlag London Ltd. 2011a. <https://www.springer.com/us/book/9780857295842>
https://www.google.com/books/edition/A_History_of_Endometriosis/JyoywyVfIhkc?hl=en&gbpv=1

Batt RE, ed. *Intellectual Development of Carl Von Rokitansky*. in *A History of Endometriosis*. London: Springer-Verlag London Ltd. 2011b. Chapter 2. pages 11-38 is open access at <https://www.springer.com/us/book/9780857295842>
http://www.springer.com/cda/content/document/cda_downloaddocument/9780857295842-c1.pdf?SGWID=0-0-45-1153739-p174109272

Batt RE, ed. *Appendix II: English Translation of Carl Rokitansky's Ueber Uterusdrusen-Neubildung in Uterus-und Ovarial Sarcomen*. in *A History of Endometriosis*. London: Springer-Verlag London Ltd. 2011c. Appendix II. PP 209-212
<https://www.springer.com/us/book/9780857295842>, Preview at Google Books at: https://www.google.com/books/edition/A_History_of_Endometriosis/JyoywyVfIhkc?hl=en&gbpv=1

Batt RE, Yeh J. Müllerianosis: four developmental (embryonic) Müllerian diseases. *Reprod Sci*. 2013, 20(9):1030-7.

Batt RE, Martin DC, Odunsi K. Endometriosis of the retrocervical septum is proposed to replace the anatomically incorrect term endometriosis of the rectovaginal septum. *Hum Reprod*. 2014 Dec;29(12):2603-5. doi: 10.1093/humrep/deu279. Epub 2014 Oct 21. PMID: 25336705. Open Access: <https://academic.oup.com/humrep/article/29/12/2603/630870?login=false>

Batt RE. "The Theory of Müllerianosis: An Odyssey of Discovery and Verification." Endometriosis Foundation of America Annual Harry Reich Award presentation. Endometriosis Foundation of America Sixth Annual Medical Conference. April 12, 2015, <https://www.endofound.org/video/ronald-batt-md-mullerianosis-embryonic-endometriosis-adenomyosis-endosalpingiosis-and-endocervicosis/1254>

Becker CM, Laufer MR, Stratton P, Hummelshoj L, Missmer SA, Zondervan KT, Adamson GD, WERF EPHEct Working Group. World Endometriosis Research Foundation Endometriosis Phenome and Biobanking Harmonisation Project: I. Surgical phenotype data collection in

endometriosis research. *Fertil Steril*. 2014, 102(5):1213-22.

<https://www.ncbi.nlm.nih.gov/pmc/articles/PMC4230690/>

Becker CM, Bokor A, Heikinheimo O, Horne A, Jansen F, Kiesel L, King K, Kvaskoff M, Nap A, Petersen K, Saridogan E, Tomassetti C, van Hanegem N, Vulliamoz N, Vermeulen N; ESHRE Endometriosis Guideline Group. ESHRE guideline: endometriosis. *Hum Reprod Open*. 2022 Feb 26;2022(2):hoac009. doi: 10.1093/hropen/hoac009. PMID: 35350465; PMCID: PMC8951218.

Open Access: <https://academic.oup.com/hropen/article/2022/2/hoac009/6537540?login=false>

Bedaiwy MA. Endometrial cytokines, endometriosis and infertility: a deeper dive into the endometrial immune microenvironment. *Fertil Steril*. 2022 Mar;117(3):641-642. doi: 10.1016/j.fertnstert.2022.01.023. PMID: 35219474.

Open Access: [https://www.fertstert.org/article/S0015-0282\(22\)00058-9/fulltext](https://www.fertstert.org/article/S0015-0282(22)00058-9/fulltext)

Bendifallah S, Roman H, Mathieu d'Argent E, Touleimat S, Cohen J, Darai E, Ballester M. Colorectal endometriosis-associated infertility: should surgery precede ART? *Fertil Steril*. 2017 Sep;108(3):525-531.e4. doi: 10.1016/j.fertnstert.2017.07.002. Epub 2017 Aug 12. PMID: 28807397. Open Access: [https://www.fertstert.org/article/S0015-0282\(17\)30497-1/fulltext](https://www.fertstert.org/article/S0015-0282(17)30497-1/fulltext)

Bendifallah S, Dabi Y, Suisse S, Jornea L, Bouteiller D, Touboul C, Puchar A, Darai E. MicroRNome analysis generates a blood-based signature for endometriosis. *Sci Rep*. 2022 Mar 8;12(1):4051. doi: 10.1038/s41598-022-07771-7. PMID: 35260677; PMCID: PMC8902281

Open Access: <https://www.nature.com/articles/s41598-022-07771-7>

Bendifallah S, Dabi Y, Suisse S, Delbos L, Spiers A, Poilblanc M, Golfier F, Jornea L, Bouteiller D, Fernandez H, Madar A, Petit E, Perotte F, Fauvet R, Benjoar M, Akladios C, Lavoue V, Darnaud T, Merlot B, Roman H, Touboul C, Descamps P. Validation of a Salivary miRNA Signature of Endometriosis — Interim Data. *NEJM Evidence*. 2023; 0(0):EVIDoa2200282. doi: 10.1056/EVIDoa2200282.

Open Access: <https://evidence.nejm.org/doi/full/10.1056/EVIDoa2200282>

Berlanda N, Benaglia L, Bottelli L, Torri C, Busnelli A, Somigliana E, Vercellini P. The impact of IVF on deep invasive endometriosis. *Eur J Obstet Gynecol Reprod Biol X*. 2019 Jun 13;4:100073. doi: 10.1016/j.eurox.2019.100073. PMID: 31517304; PMCID: PMC6728720.

Berlanda, N., Alio, W., Angioni, S. et al. Impact of endometriosis on obstetric outcome after natural conception: a multicenter Italian study. *Arch Gynecol Obstet* (2021).

<https://doi.org/10.1007/s00404-021-06243-z>.

Open access: <https://link.springer.com/article/10.1007%2Fs00404-021-06243-z>

Blumenkrantz MJ, Gallagher N, Bashore RA, Tenckhoff H. Retrograde menstruation in women undergoing chronic peritoneal dialysis. *Obstet Gynecol*. 1981, 57(5):667-670. PMID: 7219918, https://journals.lww.com/greenjournal/Abstract/1981/05000/retrograde_menstruation_in_women_undergoing.22.aspx

Bobek V, Kolostova K, Kucera E. Circulating endometrial cells in peripheral blood. *Eur J Obstet Gynecol Reprod Biol*. 2014, 181, 267–274. PMID:25195200

DOI: <https://doi.org/10.1016/j.ejogrb.2014.07.037>

Boretto M, Maenhoudt N, Luo X, Hennes A, Boeckx B, Bui B, Heremans R, Perneel L, Kobayashi H, Van Zundert I, Brems H, Cox B, Ferrante M, Uji-I H, Koh KP, D'Hooghe T,

Vanhie A, Vergote I, Meuleman C, Tomassetti C, Lambrechts D, Vriens J, Timmerman D, Vankelecom H. Patient-derived organoids from endometrial disease capture clinical heterogeneity and are amenable to drug screening. *Nat Cell Biol.* 2019 Aug;21(8):1041-1051. doi: 10.1038/s41556-019-0360-z. Epub 2019 Aug 1. PMID: 31371824.

Borghini R, Porpora MG, Casale R, Marino M, Palmieri E, Greco N, Donato G, Picarelli A. Irritable Bowel Syndrome-Like Disorders in Endometriosis: Prevalence of Nickel Sensitivity and Effects of a Low-Nickel Diet. An Open-Label Pilot Study. *Nutrients.* 2020 Jan 28;12(2):341. doi: 10.3390/nu12020341. PMID: 32012984; PMCID: PMC7071203.
Open Access: <https://www.mdpi.com/2072-6643/12/2/341>

Börschel CS, Stejskalova A, Schäfer SD, Kiesel L, Götte M. miR-142-3p Reduces the Size, Migration, and Contractility of Endometrial and Endometriotic Stromal Cells by Targeting Integrin- and Rho GTPase-Related Pathways That Regulate Cytoskeletal Function. *Biomedicines.* 2020 Aug 18;8(8):291. doi: 10.3390/biomedicines8080291. PMID: 32824678; PMCID: PMC7460043.

Bossuyt PM, Reitsma JB, Bruns DE, Gatsonis CA, Glasziou PP, Irwig LM, Lijmer JG, Moher D, Rennie D, de Vet HC; STARD group. Towards complete and accurate reporting of studies of diagnostic accuracy: the STARD initiative. *Clin Chem Lab Med.* 2003 Jan;41(1):68-73. doi: 10.1515/CCLM.2003.012. PMID: 12636052.

Bougie O, McClintock C, Pudwell J, Brogly SB, Velez MP. Long-term follow-up of endometriosis surgery in Ontario: a population-based cohort study. *Am J Obstet Gynecol.* 2021 Sep;225(3):270.e1-270.e19. doi: 10.1016/j.ajog.2021.04.237. PMID: 33894154.

Bouquet De Joliniere J, Ayoubi JM, Gianaroli L, Dubuisson JB, Gogusev J, Feki A. Endometriosis: a new cellular and molecular genetic approach for understanding the pathogenesis and evolutivity. *Front Surg* 2014, 1: 16.

Bourdon M, Peigné M, Maignien C, de Villardi de Montlaur D, Solignac C, Darné B, Languille S, Bendifallah S, Santulli P. Impact of endometriosis surgery on in vitro fertilization/ intracytoplasmic sperm injection outcomes: a systematic review and meta-analysis. *Reprod Sci.* 2024 Jan 2. doi: 10.1007/s43032-023-01421-7. Epub ahead of print. PMID: 38168857.
Open Access: <https://doi.org/10.1007/s43032-023-01421-7>

Bouquet de Jolinière J, Major A, Ayoubi JM, Cabry R, Khomsi F, Lesec G, Frydman R, Feki A. Is it necessary to purpose an add-on to the American classification of endometriosis? This disease can be compared to a malignant proliferation while remaining benign in most cases. EndoGram® is a new profile witness of its evolutionary potential. *Front Surg.* 2019 6:27.
PMC Open Access: <https://www.ncbi.nlm.nih.gov/pmc/articles/PMC6566301/>

Bourlev V, Moberg C, Ilyasova N, Davey E, Kunovac Kallak T, Olovsson M. Vasoactive intestinal peptide is upregulated in women with endometriosis and chronic pelvic pain. *Am J Reprod Immunol,* 2018 80(3):e12857.

Branquinho MM, Marques AL, Leite HB, Silva IS. Juvenile cystic adenomyoma. *BMJ Case Rep.* 2012; 2012: bcr2012007006. <https://www.ncbi.nlm.nih.gov/pmc/articles/PMC4544307/>

Brenhouse HC, Schwarz JM. Immunoadolescence: Neuroimmune development and adolescent behavior. *Neurosci Biobehav Rev.* 2016 Nov;70:288-299. doi: 10.1016/j.neubiorev.2016.05.035. Epub 2016 May 31. PMID: 27260127; PMCID: PMC5412135.

Breus C, Uber Wahre Epithel Führende Cystenbildung in Uterusmyomen (Leipzig und Wien: Franz Deuticke, 1894], 1–36.

Breus C. Pamphlets—Liepzig und Wien—Pamphlet Vol. 4054—Army Med. Library, Washington, D. C. [This appears to be a version of the 1894 publication per Batt 2100a]

Brews A: Endometriosis of the diaphragm and Meig's syndrome. Proc R Soc Med. 1954 Jun; 47(6): 461. PMID: PMC1918875.

<https://www.ncbi.nlm.nih.gov/pmc/articles/PMC1918875/?report=classic&page=1>

Brosens IA. Endometriosis--a disease because it is characterized by bleeding. Am J Obstet Gynecol. 1997, 176(2):263-267. doi: 10.1016/s0002-9378(97)70482-4. PMID: 9065165

Brosens I, Steeno O. A compass for understanding endometriosis (To the Editor). Fertil Steril 2000, 73(1):179-180. PMID: 10632441. DOI: [https://doi.org/10.1016/s0015-0282\(99\)00478-1](https://doi.org/10.1016/s0015-0282(99)00478-1)

Brosens I, Benagiano G. Endometriosis, a modern syndrome. Indian J Med Res. 2011, 133:581-93. <https://www.ncbi.nlm.nih.gov/pmc/articles/PMC3135985/>

Brosens I, Gordts S, Benagiano G. Endometriosis in adolescents is a hidden, progressive and severe disease that deserves attention, not just compassion. Hum Reprod 2013, 28:2026-31. DOI: 10.1093/humrep/det243

Open Access: <https://www.ncbi.nlm.nih.gov/pmc/articles/PMC3712662/>

Brosens I, Brosens J, Benagiano G. Neonatal uterine bleeding as antecedent of pelvic endometriosis. Hum Reprod, 2013. 28(11):2893–2897, 2013

Brosens I, Benagiano G. Perinatal origin of endometriosis revisited. Gynecol Endocrinol 2015, 31:419-21.

Brosens I, Puttemans P, Benagiano G. Which cell defines endometriosis? Hum Reprod. 2018 Feb 6. DOI: 10.1093/humrep/dey016

Brownson, R. C., et al. (2006). "Translating scientific discoveries into public health action: how can schools of public health move us forward?" Public Health Rep 121(1): 97-103.

Bruner-Tran KL, Gnecco J, Ding T, Glore DR, Pensabene V, Osteen KG. Exposure to the environmental endocrine disruptor TCDD and human reproductive dysfunction: Translating lessons from murine models. Reprod Toxicol. 2016;68:59–71.

Buggio L, Barbara G, Dridi D, Ottolini F, Sergenti G, Facchin F, Vercellini P. Anogenital distance and gynaecological diseases: a narrative review. J Gynecol Obstet (Italian). 2020, 32(3):200-207. doi: 10.36129/jog.32.03.06.

Open Access: <http://dx.doi.org/10.36129/jog.32.03.06>

Buggio L, Reschini M, Viganò P, Dridi D, Galati G, Chinè A, Giola F, Somigliana E, Benaglia L. Is There a Correlation between the Second-to-Four Digit Ratio (2D:4D) and Endometriosis? Results of a Case-Control Study. J Clin Med. 2023 Mar 4;12(5):2040. doi: 10.3390/jcm12052040. PMID: 36902827; PMCID: PMC10004093.

Open Access: <https://www.mdpi.com/2077-0383/12/5/2040>

Bulun SE, Zeitoun K, Takayama K, Noble L, Michael D, Simpson E, Johns A, Putman M, Sasano H. Estrogen production in endometriosis and use of aromatase inhibitors to treat

endometriosis. *Endocr Relat Cancer* 1999, 6:293–301. PMID: 10731122

Open Access: <https://erc.bioscientifica.com/view/journals/erc/6/2/10731122.xml>

Bulun SE, Fang Z, Imir G, Gurates B, Tamura M, Yilmaz B, Langoi D, Amin S, Yang S, Deb S. Aromatase and endometriosis. *Semin Reprod Med*. 2004 Feb;22(1):45-50. doi: 10.1055/s-2004-823026. PMID: 15083380.

Bulun SE, Yilmaz BD, Sison C, Miyazaki K, Bernardi L, Liu S, Kohlmeier A, Yin P, Milad M, Wei J. Endometriosis. *Endocr Rev*. 2019 Aug 1;40(4):1048-1079. doi: 10.1210/er.2018-00242. PMID: 30994890; PMCID: PMC6693056.

PMC: <https://www.ncbi.nlm.nih.gov/pmc/articles/PMC6693056/>

Bulun SE, Yildiz S, Adli M, Wei JJ. Adenomyosis pathogenesis: insights from next-generation sequencing. *Hum Reprod Update*. 2021 Oct 18;27(6):1086-1097. doi: 10.1093/humupd/dmab017. PMID: 34131719; PMCID: PMC8543024.

Open Access: <https://academic.oup.com/humupd/article/27/6/1086/6299969?login=false>

Bulun SE. Endometriosis caused by retrograde menstruation: now demonstrated by DNA evidence. *Fertil Steril*. 2022, 118(3):535-536. DOI: 10.1016/j.fertnstert.2022.07.012.

Open access: [https://www.fertstert.org/article/S0015-0282\(22\)00461-7/fulltext](https://www.fertstert.org/article/S0015-0282(22)00461-7/fulltext)

Burks C, Lee M, DeSarno M, Findley J, Flyckt R. Excision versus ablation for management of minimal to mild endometriosis: A systematic review and meta-analysis. *J Minim Invasive Gynecol*. 2021 Mar;28(3):587-597. doi: 10.1016/j.jmig.2020.11.028. Epub 2020 Dec 10. PMID: 33310168.

Burlev VA, Ilyasova NA. Neuroangiogenesis in endometrium of women with endometriosis and chronic pelvic pain: high expression of vasoactive intestinal peptide. *Problems Reproduction*, 2017, 4:87-97 (Russian) <https://doi.org/10.17116/repro201723487-97>

Burlev VA, et al. Vasoactive intestinal peptide is upregulated in women with endometriosis and chronic pelvic pain. *Reprod Immunol*, 2018 80(3):e12857

<https://www.ncbi.nlm.nih.gov/pubmed/29675846>

Burney RO, Hamilton AE, Aghajanova L, Vo KC, Nezhat CN, Lessey BA, Giudice LC. MicroRNA expression profiling of eutopic secretory endometrium in women with versus without endometriosis, *Mol Hum Reprod*. 2009, 15:625–631. PMID: 19692421

DOI: <http://dx.doi.org/10.1093/molehr/gap068>

PMC: <https://www.ncbi.nlm.nih.gov/pmc/articles/PMC2744474/>

Cabana MD, Foster-Barber AE, Hong T, Martin DC, Shenkin B. Teen troubled by a trembling leg. *Contemporary Pediatrics*. 2010, 27(6):22-27.

<http://www.contemporarypediatrics.com/modern-medicine-now/teen-troubled-trembling-leg>

Candiani GB, Vercellini P, Fedele L. Laparoscopic ovarian puncture for correct staging of endometriosis. *Fertil Steril*. 1990 Jun;53(6):994-7. doi: 10.1016/s0015-0282(16)53573-0. PMID: 2140995. Open Access:

<https://www.sciencedirect.com/science/article/pii/S0015028216535730?via%3Dihub>

Canis M, Bourdel N, Houlle C, Gremeau AS, Botchorishvili R, Matsuzaki S. Endometriosis may not be a chronic disease: an alternative theory offering more optimistic prospects for our patients. *Fertil Steril*. 2016 Jan;105(1):32-4. doi: 10.1016/j.fertnstert.2015.09.009. Epub 2015 Oct 9. PMID: 26453981.

Canis M, Bourdel N, Houille C, Gremeau AS, Botchorishvili R, Matsuzaki S. Trauma and endometriosis. A review. May we explain surgical phenotypes and natural history of the disease? *J Gynecol Obstet Hum Reprod*. 2017, 46(3):219-227. doi: 10.1016/j.jogoh.2016.12.008

Canis M, Bourdel N, Chauvet P. Years of unjustified hypoestrogenism, fear, and stress will not improve the management of chronic pelvic pain! *Am J Obstet Gynecol*. 2019 Aug;221(2):170-171. doi: 10.1016/j.ajog.2019.05.001. Epub 2019 May 10. PMID: 31082384.

Caserta D, Maranghi L, Mantovani A, Marci R, Maranghi F, Moscarini M. Impact of endocrine disruptor chemicals in gynaecology. *Hum Reprod Update*. 2008 Jan-Feb;14(1):59-72. doi: 10.1093/humupd/dmm025. Epub 2007 Dec 10. PMID: 18070835.

Open Access: <https://academic.oup.com/humupd/article/14/1/59/821308?login=false>

Casler DB, A unique diffuse uterine tumor, really an adenoma, with stroma, but no glands. Menstruation after complete hysterectomy due to uterine mucosa in remaining ovary. *Transactions of the American Gynecological Society for the year 1919*. 44:69-84

Chan AC. Partners in defense, vitamin E and vitamin C. *Can J Physiol Pharmacol*. 1993 Sep;71(9):725-31. doi: 10.1139/y93-109. PMID: 8313238.

Chan RW, Schwab KE, Gargett CE. Clonogenicity of human endometrial epithelial and stromal cells. *Biol Reprod* 2004, 70(6):1738-50.

Chandrasekaran A, Groven S, Lewis JD, Levy SS, Diamant C, Singh E, Konijeti GG. An autoimmune protocol diet improves patient-reported quality of life in inflammatory bowel disease. *Crohns Colitis* 360. 2019a Oct;1(3):otz019. doi: 10.1093/crocol/otz019. Epub 2019 Aug 7. PMID: 31832627; PMCID: PMC6892563.

Open Access: <https://academic.oup.com/crohnscolitis360/article/1/3/otz019/5544574>

Chandrasekaran A, Molparia B, Akhtar E, Wang X, Lewis JD, Chang JT, Oliveira G, Torkamani A, Konijeti GG. The autoimmune protocol diet modifies intestinal RNA expression in inflammatory bowel disease. *Crohns Colitis* 360. 2019 Oct;1(3):otz016. doi: 10.1093/crocol/otz016. Epub 2019 Jul 12. PMID: 32309803; PMCID: PMC7147823.

Open Access: <https://academic.oup.com/crohnscolitis360/article/1/3/otz016/5531501?login=false>

Chang CY, Chiang AJ, Yan MJ, Lai MT, Su YY, Huang HY, Chang CY, Li YH, Li PF, Chen CM, Hwang T, Hogg C, Greaves E, Sheu JJ. Ribosome Biogenesis Serves as a Therapeutic Target for Treating Endometriosis and the Associated Complications. *Biomedicines*. 2022 Jan 17;10(1):185. doi: 10.3390/biomedicines10010185. PMID: 35052864; PMCID: PMC8774031. Open access: <https://www.ncbi.nlm.nih.gov/pmc/articles/PMC8774031/>

Chapron C, Bourret A, Chopin N, Dousset B, Leconte M, Amsellem-Ouazana D, de Ziegler D, Borghese B. Surgery for bladder endometriosis: long-term results and concomitant management of associated posterior deep lesions. *Hum Reprod*. 2010 Apr;25(4):884-9. doi: 10.1093/humrep/deq017. Epub 2010 Feb 3. PMID: 20129993.

Open Access: <https://academic.oup.com/humrep/article/25/4/884/701431?login=false>

Chapron C, Marcellin L, Borghese B, Santulli P. Rethinking mechanisms, diagnosis and management of endometriosis. *Nat Rev Endocrinol*. 2019 Nov;15(11):666-682. doi: 10.1038/s41574-019-0245-z. Epub 2019 Sep 5. PMID: 31488888.

Chapron C, Lafay-Pillet MC, Santulli P, Bourdon M, Maignien C, Gaudet-Chardonnet A, Maitrot-Mantelet L, Borghese B, Marcellin L. A new validated screening method for endometriosis diagnosis based on patient questionnaires. *EClinicalMedicine*. 2022 Jan 10;44:101263. doi: 10.1016/j.eclinm.2021.101263. PMID: 35059616; PMCID: PMC8760436. Open Access: [https://www.thelancet.com/journals/eclinm/article/PIIS2589-5370\(21\)00544-7/fulltext](https://www.thelancet.com/journals/eclinm/article/PIIS2589-5370(21)00544-7/fulltext)

Chaudhury K, Babu K N, Singh AK, Das S, Kumar A, Seal S. Mitigation of endometriosis using regenerative cerium oxide nanoparticles. *Nanomedicine*. 2013 9(3):439-48. doi: 10.1016/j.nano.2012.08.001. PMID: 22960424.

Chen DG, Fang D, Wilson JR. Meta-analysis of two studies with random effects? *J Minim Invasive Gynecol*. 2017 Jul-Aug;24(5):689-690. doi: 10.1016/j.jmig.2017.05.008. Epub 2017 May 26. PMID: 28552623.

Chen Y, Zhu HL, Tang ZW, Neoh KH, Ouyang DF, Cui H, Cheng HY, Ma RQ, Ye X, Han RP, Chang XH. Evaluation of circulating endometrial cells as a biomarker for endometriosis. *Chin Med J (Engl)*. 2017 Oct 5;130(19):2339-2345. doi: 10.4103/0366-6999.215325. PMID: 28937041; PMCID: PMC5634086.

Open access: <http://www.ncbi.nlm.nih.gov/pmc/articles/pmc5634086/>

Chen I, Lalani S, Xie RH, Shen M, Singh SS, Wen SW. Association between surgically diagnosed endometriosis and adverse pregnancy outcomes. *Fertil Steril*. 2018, 109(1):142-147.

Chen L, Qu J, Xiang C. The multi-functional roles of menstrual blood-derived stem cells in regenerative medicine. *Stem Cell Research & Therapy*. 2019, 10:1-10
<https://www.ncbi.nlm.nih.gov/pmc/articles/PMC6318883/>
<https://doi.org/10.1186/s13287-018-1105-9>

Chen TY, Li X, Hung CH, Bahudhanapati H, Tan J, Kass DJ, Zhang Y. The relaxin family peptide receptor 1 (RXFP1): An emerging player in human health and disease. *Mol Genet Genomic Med*. 2020 Apr;8(4):e1194. doi: 10.1002/mgg3.1194. PMID: 32100955; PMCID: PMC7196478. Open access: <https://www.ncbi.nlm.nih.gov/pmc/articles/PMC7196478/>

Chen P, Mamillapalli R, Habata S, Taylor HS. Endometriosis cell proliferation induced by bone marrow mesenchymal stem cells. *Reprod Sci*. 2021 Feb;28(2):426-434. doi: 10.1007/s43032-020-00294-4. PMID: 32812213.

Christ JP, Yu O, Schulze-Rath R, Grafton J, Hansen K, Reed SD. Incidence, prevalence, and trends in endometriosis diagnosis: a United States population-based study from 2006 to 2015. *Am J Obstet Gynecol*. 2021 Nov;225(5):500.e1-500.e9. doi: 10.1016/j.ajog.2021.06.067. Epub 2021 Jun 17. PMID: 34147493.

Christofolini DM, Mafra FA, Catto MC, Bianco B, Barbosa CP. New candidate genes associated to endometriosis. *Gynecol Endocrinol*. 2018, 25:1-4.

Cicinelli E, Trojano G, Mastromauro M, Vimercati A, Marinaccio M, Mitola PC, Resta L, de Ziegler D. Higher prevalence of chronic endometritis in women with endometriosis: a possible etiopathogenetic link. *Fertil Steril*. 2017, 108:289-95. doi: 10.1016/j.fertnstert.2017.05.016
Open Access: [https://www.fertstert.org/article/S0015-0282\(17\)30397-7/fulltext](https://www.fertstert.org/article/S0015-0282(17)30397-7/fulltext)

Clark W, Philadelphia, 1908-1910, credited in Kelly HA. Electrosurgery in Gynaecology. *Ann Surg* 1931;93:323-5. Worked out the principles of electrosurgery

Clark AH. endometriosis in a young girl. JAMA. 1948;136(10):690.
doi:10.1001/jama.1948.72890270008008a

Clement PB. The pathology of endometriosis: a survey of the many faces of a common disease emphasizing diagnostic pitfalls and unusual and newly appreciated aspects. *Adv Anat Pathol*. 2007 14(4):241-60. doi: 10.1097/PAP.0b013e3180ca7d7b. PMID: 17592255

Clower L, Fleshman T, Geldenhuys WJ, Santanam N. Targeting Oxidative Stress Involved in Endometriosis and Its Pain. *Biomolecules*. 2022 Jul 29;12(8):1055. doi: 10.3390/biom12081055. PMID: 36008949; PMCID: PMC9405905. Open Access: <https://www.mdpi.com/2218-273X/12/8/1055>

Coccia ME, Rizzello F, Mariani G, Bulletti C, Palagiano A, Scarselli G. Ovarian surgery for bilateral endometriomas influences age at menopause. *Hum Reprod*. 2011 Nov;26(11):3000-7. doi: 10.1093/humrep/der286. Epub 2011 Aug 24. PMID: 21868401.

Cohen MR. Surgical Laparoscopy in Infertility. *J Reprod Med* 1975. 15 (2): 51-53

Cornillie FJ, Oosterlynck D, Lauweryns JM, Koninckx PR. Deeply infiltrating pelvic endometriosis: histology and clinical significance. *Fertil Steril*. 1990 Jun;53(6):978-83. doi: 10.1016/s0015-0282(16)53570-5. PMID: 2140994. Open Access: <https://www.sciencedirect.com/science/article/pii/S0015028216535705?via%3Dihub>

Cornillie FJ, Lauweryns JM, Seppälä M, Riittinen L, Koninckx PR. Expression of endometrial protein PP14 in pelvic and ovarian endometriotic implants. *Hum Reprod*. 1991 Nov;6(10):1411-5. doi: 10.1093/oxfordjournals.humrep.a137280. PMID: 1770137.

Cottreau CM, Ness RB, Modugno F, Allen GO, Goodman MT. Endometriosis and its treatment with danazol or Lupron in relation to ovarian cancer. *Clin Cancer Res* 2003, 9:5142-4. PMID: 14613992, Open Access: <https://clincancerres.aacrjournals.org/content/9/14/5142.long>

Coxon L, Evans E, Vincent K. Endometriosis - a painful disease. *Curr Opin Anaesthesiol*. 2023 Aug 15. doi: 10.1097/ACO.0000000000001305. Epub ahead of print. PMID: 37615499. Open Access: https://journals.lww.com/co-anesthesiology/fulltext/9900/endometriosis_a_painful_disease.129.aspx

Cirillo M, Argento FR, Becatti M, Fiorillo C, Coccia ME, Fatini C. Mediterranean Diet and Oxidative Stress: A Relationship with Pain Perception in Endometriosis. *International Journal of Molecular Sciences*. 2023; 24(19):14601. <https://doi.org/10.3390/ijms241914601>
Open Access: <https://www.mdpi.com/1422-0067/24/19/14601>

Cruveilhier, F. Anatomie Pathologique du Corps Humain. Livraison XIII, Planche IV, Paris, 1835. Quoted in Breus 1894, Ripley 1986, and Batt 2011a.

Cullen TS. Adenomyoma of the round ligament. *Johns Hopkins Hosp Bull*. 1896, 7(Nos. 62-63)(May-June):112-114. <https://babel.hathitrust.org/cgi/pt?id=coo.31924069247371&view=1up&seq=158>

Cullen TS. Adeno-myoma uteri diffusum benignum. *Johns Hopkins Hosp Rep*, 1897, 6:133-157, Plates I-III.

Article: <https://babel.hathitrust.org/cgi/pt?id=mdp.39015035887556&view=1up&seq=195>
Cover: <https://babel.hathitrust.org/cgi/pt?id=mdp.39015035887556&view=1up&seq=17>

Cullen TS. Adenomyoma of the rectovaginal septum. *J Am Med Assoc* 1914, LXII(11):835-839, DOI: <https://doi.org/10.1001/jama.1914.02560360015006>
JAMA: <https://jamanetwork.com/journals/jama/fullarticle/454221>

Dadhwal V, Sharma A, Khoiwal K. Juvenile cystic adenomyoma mimicking a uterine anomaly: A report of two cases. *Eurasian. J Med.* 2017 Feb; 49(1): 59-61.
<https://www.ncbi.nlm.nih.gov/pmc/articles/PMC5389496/>

Daniell J, Pittaway D: Use of the CO₂ laser in laparoscopic surgery: Initial experience with the second puncture technique. *Infertility* 5:15, 1982

Daniell J. The role of lasers in infertility surgery. *Fertil Steril* 1984, 42(6):815-823

Daniell JF. The role of lasers in infertility surgery. *Fertil Steril.* 1984 Dec;42(6):815-23. doi: 10.1016/s0015-0282(16)48249-x. PMID: 6238850. Open Access: <https://www.sciencedirect.com/science/article/pii/S001502821648249X?via%3Dihub>

da Silva CM, Vilaça Belo A, Passos Andrade S, Peixoto Campos P, Cristina França Ferreira M, Lopes da Silva-Filho A, Mendonça Carneiro M. Identification of local angiogenic and inflammatory markers in the menstrual blood of women with endometriosis. *Biomed Pharmacother.* 2014 Sep;68(7):899-904. doi: 10.1016/j.biopha.2014.08.005. Epub 2014 Aug 14. PMID: 25218120.

Davis GD, Thillet E, Lindemann J. Clinical characteristics of adolescent endometriosis. *J Adolesc Health.* 1993 Jul;14(5):362-8. doi: 10.1016/s1054-139x(08)80008-0. PMID: 8399247.

Deans C, Maggert KA. What do you mean, "epigenetic"? *Genetics.* 2015 Apr;199(4):887-96. doi: 10.1534/genetics.114.173492. PMID: 25855649; PMCID: PMC4391566.
Open Access: <https://academic.oup.com/genetics/article/199/4/887/5935873?login=false>

Dekel R. Screening, the everlasting quest for the needle in the haystack. *Isr Med Assoc J.* 2005 Oct;7(10):650-2. PMID: 16259346.

De La Riva-Morales I, Umeres-Francia GE, Novo JE. Iatrogenic Endometriosis of the Breast Mimicking Fat Necrosis: A Case Report. *International Journal of Surgical Pathology.* 2023;0(0). doi:10.1177/10668969231201416.

Demco L. Mapping the source and character of pain due to endometriosis by patient-assisted laparoscopy. *J Am Assoc Gynecol Laparosc.* 1998 Aug;5(3):241-5. doi: 10.1016/s1074-3804(98)80026-1. PMID: 9668144.

De Pascali F, Casarini L, Kuhn C, et al. Nuclear expression of VDR and AHR is mutually exclusive in glandular cells in endometriosis. *Histochem Cell Biol*, 2021, [online 21 June 2021] doi: 10.1007/s00418-021-02005-9
Open Access: <https://link.springer.com/article/10.1007/s00418-021-02005-9>

de Ziegler D, Ayoubi JM. Endometriosis and adenomyosis in the crosshair: variants of one disorder or fortuitous coincidence. *Fertil Steril.* 2023, [Published online: February 17, 2023] DOI: <https://doi.org/10.1016/j.fertnstert.2023.02.021>

Ding S, Lin Q, Zhu T, Li T, Zhu L, Wang J, Zhang X. Is there a correlation between inflammatory markers and coagulation parameters in women with advanced ovarian endometriosis? *BMC Womens Health.* 2019, 19(1):169. doi: 10.1186/s12905-019-0860-9,

PMID: 31888633. PMCID: PMC6937785

PMC open access: <https://www.ncbi.nlm.nih.gov/pmc/articles/PMC6937785/>

Dinh T, Leonardi M, Espada M, Vanza K, Condous G. The use of ultrasound in detecting endometriosis: endometriotic nodule detected on ultrasound but not visualized on laparoscopy. *J Obstet Gynaecol Can.* 2020 Aug;42(8):1016. doi: 10.1016/j.jogc.2019.12.013. Epub 2020 Mar 12. PMID: 32171505

Donnez J, Casanas-Roux F, Ferin J, Thomas K. Tubal polyps, epithelial inclusions, and endometriosis after tubal sterilization. *Fertil Steril* 1984, 41(4):564-568

Donnez J, Nisolle M, Gillerot S, Smets M, Bassil S, Casanas-Roux F, Rectovaginal septum adenomyotic nodules: a series of 500 cases, *Br J Obstet Gynaecol* 104:1014, 1997.

PMID: 9307527, DOI: 10.1111/j.1471-0528.1997.tb12059.x

<https://obgyn.onlinelibrary.wiley.com/doi/epdf/10.1111/j.1471-0528.1997.tb12059.x>

Donnez J, Nisolle M. Attachment of “menstrual” endometrium to peritoneum? (Letter to Editors re Witz 2001). *Fertil Steril*, 76(3):642-643.

Donnez J, Donnez O, Squifflet J, Nisolle M: The concept of ‘adenomyotic disease of the retroperitoneal space’ is born. *Gynaecol Endosc* 2001, 10:91-94.

Donnez J, Dolmans MM, Fellah L. What if deep endometriotic nodules and uterine adenomyosis were actually two forms of the same disease? *Fertil Steril.* 2019 Mar;111(3):454-456. doi: 10.1016/j.fertnstert.2018.12.018. Epub 2019 Feb 2. PMID: 30722943.

Donnez J, Dolmans MM. Endometriosis and medical therapy: From progestogens to progesterone resistance to GnRH antagonists: A Review. *J Clin Med.* 2021 Mar 5;10(5):1085. doi: 10.3390/jcm10051085. PMID: 33807739; PMCID: PMC7961981.

Open access: <https://www.mdpi.com/2077-0383/10/5/1085/htm>

Dorien FO, Roskams T, Van den Eynde K, et al. The presence of endometrial cells in peritoneal fluid of women with and without endometriosis. *Reprod Sci.* 2017;24(2):242–251.

PMID: 31975280, DOI: <https://doi.org/10.1177/1933719116653677>

Drossman DA, Whitehead WE, Camilleri M. Irritable bowel syndrome: a technical review for practice guideline development. *Gastroenterology.* 1997 Jun;112(6):2120-37. doi: 10.1053/gast.1997.v112.agast972120. PMID: 9178709.

Open Access: <https://doi.org/10.1053/gast.1997.v112.agast972120>

Dmowski WP, Cohen MR. Treatment of endometriosis with an antigonadotropin, danazol. A laparoscopic and histologic evaluation. *Obstet Gynecol*,1975, 46 (2), 147-54,

PMID: 125397, <https://pubmed.ncbi.nlm.nih.gov/125397/>

Dmowski WP, Steele RW, Baker GF. Deficient cellular immunity in endometriosis. *Am J Obstet Gynecol.* 1981, 141(4):377-83.

Dmowski WP, Gebel H, Braun DP. Decreased apoptosis and sensitivity to macrophage mediated cytolysis of endometrial cells in endometriosis. *Hum Reprod Update.* 1998 Sep-Oct;4(5):696-701. doi: 10.1093/humupd/4.5.696. PMID: 10027622.

Open Access: <https://academic.oup.com/humupd/article/4/5/696/592243>

Dückelmann AM, Taube E, Abesadze E, Chiantera V, Sehouli J, Mechsner S. When and how should peritoneal endometriosis be operated on in order to improve fertility rates and symptoms?

The experience and outcomes of nearly 100 cases. Arch Gynecol Obstet. 2021 Jul;304(1):143-155. doi: 10.1007/s00404-021-05971-6. Epub 2021 Feb 3. PMID: 33537880; PMCID: PMC8164581.

Ebert AD, Fuhr N, David M, Schnepffel L, Papadopoulos T. Histological confirmation of endometriosis in a 9-year-old girl suffering from unexplained cyclic pelvic pain since her eighth year of life. *Gynecol Obstet Invest.* 2009;67(3):158-61. doi: 10.1159/000181185. Epub 2008 Dec 11. PMID: 19077389.

Edmonds K. *The 4-Week Endometriosis Diet Plan: 75 Healing Recipes to Relieve Symptoms and Regain Control of Your Life.* 2019. Katie Edmonds, Kauai. <https://www.amazon.com/4-Week-Endometriosis-Diet-Plan-Symptoms/dp/1641527366/>

Edmonds K. *Heal Endo: An Anti-Inflammatory Approach to Healing from Endometriosis.* 2022. Katie Edmonds, Kauai. <https://www.amazon.com/Heal-Endo-Anti-Inflammatory-Approach-Endometriosis/dp/1792389485/>

Edmonds K. Can endometriosis really be symptom free? 2023, <https://www.instagram.com/p/CwqRHWws9Mt/>

Esfandiari F, Favaedi R, Heidari-Khoei H, Chitsazian F, Yari S, Piryaei A, Ghafari F, Baharvand H, Shahhoseini M. Insight into epigenetics of human endometriosis organoids: DNA methylation analysis of HOX genes and their cofactors. *Fertil Steril.* 2021a Jan;115(1):125-137. doi: 10.1016/j.fertnstert.2020.08.1398. Epub 2020 Oct 14. PMID: 33066976.
Open Access: [https://www.fertstert.org/article/S0015-0282\(20\)32152-X/fulltext](https://www.fertstert.org/article/S0015-0282(20)32152-X/fulltext)

Esfandiari F, Chitsazian F, Jahromi MG, Favaedi R, Bazrgar M, Aflatoonian R, Afsharian P, Aflatoonian A, Shahhoseini M. HOX cluster and their cofactors showed an altered expression pattern in eutopic and ectopic endometriosis tissues. *Reprod Biol Endocrinol.* 2021b Sep 1;19(1):132. doi: 10.1186/s12958-021-00816-y. PMID: 34470627; PMCID: PMC8409001.

Evans S, Fernandez S, Olive L, Payne LA, Mikocka-Walus A. Psychological and mind-body interventions for endometriosis: A systematic review. *J Psychosom Res.* 2019 Sep;124:109756. doi: 10.1016/j.jpsychores.2019.109756. Epub 2019 Jun 27. PMID: 31443810.

Evers JL. Endometriosis does not exist; all women have endometriosis. *Hum Reprod.* 1994, 9(12):2206-9. doi: 10.1093/oxfordjournals.humrep.a138421. PMID: 7714129.

Evers JLH, Dunselman GAJ. Endometriosis is not a disease but an epiphenomenon. In: Lemay A, Maheus R, eds. *Understanding and Managing Endometriosis.* New York: The Parthenon Publishing Group, 1999, pages 31-34. ISBN-13: 978-1850700708, ISBN-10: 1850700702

Evers, JLH, Dunselman GAJ, & Groothuis P. Now you see them, now you don't. *Fertil Steril.* 2005, 84:31-32. doi: 10.1016/j.fertnstert.2005.01.122. PMID: 16009150

Evers JLH. Is adolescent endometriosis a progressive disease that needs to be diagnosed and treated? *Hum Reprod.* 2013 Aug;28(8):2023. doi: 10.1093/humrep/det298, PMID: 23861497.
Open Access: <https://academic.oup.com/humrep/article/28/8/2023/661930?login=false>

Falcone T, Wilson JR. Surgical treatment of endometriosis: excision versus ablation of peritoneal disease. *J Minim Invasive Gynecol.* 2019 Jan;26(1):1-2. doi: 10.1016/j.jmig.2018.10.008. Epub 2018 Oct 12. PMID: 30321670.

- Fallas, RE. Endometriosis; demonstration for the Sampson theory by a human anomaly. *Am J Obstet Gynecol.* 1956 Sep;72(3):557-61. doi: 10.1016/0002-9378(56)90380-5. PMID: 13354667.
- Fallon J. Endometriosis in youth. *J Am Med Assoc.* 1946 Aug 24;131:1405. doi: 10.1001/jama.1946.02870340011003. PMID: 20994364.
- Fallon J, Brosnan JT, Manning JJ, Moran WG, Meyers J, Fletcher ME. Endometriosis; a report of 400 cases. *R I Med J.* 1950 Jan;33(1):15-20, incl pl. PMID: 15402565.
- Farahani ZK, Taherianfard M, Naderi MM, Ferrero H. Possible therapeutic effect of royal jelly on endometriotic lesion size, pain sensitivity, and neurotrophic factors in a rat model of endometriosis. *Physiol Rep.* 2021, 9(22):e15117. doi: 10.14814/phy2.15117. PMID: 34806344. Open Access: <https://physoc.onlinelibrary.wiley.com/doi/10.14814/phy2.15117>
- Fagervold B, Jenssen M, Hummelshoj L, Moen MH. Life after a diagnosis with endometriosis - a 15 years follow-up study. *Acta Obstet Gynecol Scand.* 2009;88(8):914-9. doi: 10.1080/00016340903108308. PMID: 19568961. Open Access: <https://obgyn.onlinelibrary.wiley.com/doi/epdf/10.1080/00016340903108308>
- Falcone T. Ethanol Sclerotherapy for endometrioma: At the time of laparoscopy. *J Minim Invasive Gynecol.* 2023 Jan;30(1):1-2. doi: 10.1016/j.jmig.2022.11.001. Epub 2022 Nov 10. PMID: 36372313.
- Fedele L, Bianchi S, Zanconato G, Bettoni G, Gotsch F. Long-term follow-up after conservative surgery for rectovaginal endometriosis. *Am J Obstet Gynecol.* 2004a, Apr;190(4):1020-4. doi: 10.1016/j.ajog.2003.10.698. PMID: 15118634.
- Fedele L, Bianchi S, Zanconato G, Raffaelli R, Berlanda N. Is rectovaginal endometriosis a progressive disease? 2004b, *AJOG* 191: 1539-1542. . doi: 10.1016/j.ajog.2004.06.104. PMID: 15547522
- Ferguson 1929 incisional endometriosis in drain site. Discussant page 271 of Wharton 1927, Conservative surgical treatment of pelvic endometriosis. *South Med J* 22(3, Mar):267-271, 1929.
- Fernandez-Shaw S, Clarke MT, Hicks B, Naish CE, Barlow DH, Starkey PM. Bone marrow-derived cell populations in uterine and ectopic endometrium. *Hum Reprod* 1995, 10:2285-9.
- Ferrero S, Arena E, Morando A, Remorgida V. Prevalence of newly diagnosed endometriosis in women attending the general practitioner. *Int J Gynaecol Obstet.* 2010; 110:203–7.
- Flores VA, Vanhie A, Dang T, Taylor HS. Progesterone receptor status predicts response to progestin therapy in endometriosis. *J Clin Endocrinol Metab.* 2018 Dec 1;103(12):4561-4568.
- Fonseca AS, et al. A cellular and molecular portrait of endometriosis subtypes. *bioRxiv* 2021 [posted May 21, 2021] doi: 10.1101/2021.05.20.445037. Open access: <https://doi.org/10.1101/2021.05.20.445037>
- Forster R, Sarginson A, Velichkova A, Hogg C, Dorning A, Horne AW, Saunders PTK, Greaves E. Macrophage-derived insulin-like growth factor-1 is a key neurotrophic and nerve-sensitizing factor in pain associated with endometriosis. *FASEB J.* 2019, 33(10):11210-11222. doi: 10.1096/fj.201900797R. Epub 2019 Jul 10. PMID: 31291762; PMCID: PMC6766660. Open Access: <https://www.fasebj.org/doi/pdf/10.1096/fj.201900797R>

Forte A, Cipollaro M, Galderisi U. Genetic, epigenetic and stem cell alterations in endometriosis: new insights and potential therapeutic perspectives. *Clin Sci* 2014, 126(2): 123-38.

Foster WG. Hypoxia-induced autophagy, epithelial to mesenchymal transition, and invasion in the pathophysiology of endometriosis: a perspective. *Biology of Reproduction*, 2018, 0(0), 1-2
DOI:10.1093/biolre/ioy137

Freger SM, Leonardi M, Foster WG. Exosomes and their cargo are important regulators of cell function in endometriosis. *Reprod Biomed Online*. 2021 [online June 02, 2021] doi: /10.1016/j.rbmo.2021.05.022. Open Access <https://doi.org/10.1016/j.rbmo.2021.05.022>

Friedman NB, Ash JE. Tumors of the urinary bladder. In: *Atlas of Tumor Pathology*. Washington, D. C.: Armed Forces Institute of Pathology, sect. 8, fasc. 31b, 1959. (Reported in Olikier 1971)

Friedman JR, Kallen CB. Diagnosing endometriosis by measuring plasma micro ribonucleic acids: it may take a miRacle. *Fertil Steril*. 2020 113(6):1158-1159.
doi: 10.1016/j.fertnstert.2020.02.109. Epub 2020 May 8. PMID: 32389348.

Fuentes A, Escalona J, Céspedes P, Espinoza A, Johnson MC, [Prevalence of endometriosis in 287 women undergoing surgical sterilization in Santiago Chile]. [Article in Spanish] *Rev Med Chil*. 2014 Jan;142(1):16-9. doi: 10.4067/S0034-98872014000100003. PMID: 24861109. Open Access: https://www.scielo.cl/scielo.php?script=sci_arttext&pid=S0034-98872014000100003

Füth (Zentr für Gynäk vol i. S.628) 1903. Quoted in Lockyer, Cuthbert (ed) *Fibroids and Allied Tumors (Myoma and Adenomyoma)*, Macmillan and Co. Limited, London Co, 1918a
https://www.google.com/books/edition/Fibroids_and_Allied_Tumours_myoma_and_Ad/ljyg419t70UC?hl=en&gbpv=0

García-Gómez E, Vázquez-Martínez ER, Reyes-Mayoral C, Cruz-Orozco OP, Camacho-Arroyo I, Cerbón M. Regulation of inflammation pathways and inflammasome by sex steroid hormones in endometriosis. *Front Endocrinol (Lausanne)*. 2020;10:935. Published 2020 Jan 29.
doi:10.3389/fendo.2019.00935. PMID: 32063886
PMCID: <http://www.ncbi.nlm.nih.gov/pmc/articles/pmc7000463/>
DOI: <https://doi.org/10.3389/fendo.2019.00935>

García-Solares J, Dolmans MM, Squifflet JL, Donnez J, Donnez O. Invasion of human deep nodular endometriotic lesions is associated with collective cell migration and nerve development. *Fertil Steril*. 2018 110(7):1318-1327.

Gardella B, Dominoni M, Gritti A, et al. Endometriosis pain and epithelial neutrophil activating peptide-78 levels. *Sci Rep*. 2022, 12, 3227. doi: 10.1038/s41598-022-07349-3
Open Access: <https://doi.org/10.1038/s41598-022-07349-3>

Gargett C E, Masuda H. Adult stem cells in the endometrium. *Mol Hum Reprod*. 2010. 16(11):818-834.

Gargett C E, Healy DL. Generating receptive endometrium in Asherman's syndrome. *J Hum Reprod Sci*. 2011. 4(1):49–52.

Gargett CE, Schwab KE, Brosens JJ, Puttemans P, Benagiano G, Brosens I. Potential role of endometrial stem/progenitor cells in the pathogenesis of early-onset endometriosis. *Mol Hum Reprod* 2014, 20:591-8.

- Gaetje R, Kotzian S, Herrmann G, Baumann R, Starzinski-Powitz A. Nonmalignant epithelial cells, potentially invasive in human endometriosis, lack the tumor suppressor molecule E-cadherin. *Am J Pathol.* 1997, 150(2):461-7.
- Gazvani R, Templeton A. Peritoneal environment, cytokines and angiogenesis in the pathophysiology of endometriosis. *Reproduction* 2002, 123(2): 217-26. PMID: 11866688
DOI: <https://doi.org/10.1530/rep.0.1230217>
- Gazvani R, Fowler PA, Coyne L, Odds FC, Gow NAR. Does *Candida Albicans* play a role in the etiology of endometriosis? *J Endometr Pelvic Pain Disord.* 2013, 5(1):2-9. doi: 10.5301/JE.2013.10919
- Gebel HM, Braun DP, Tambur A, Frame D, Rana N, Dmowski WP. Spontaneous apoptosis of endometrial tissue is impaired in women with endometriosis. *Fertil Steril.* 1998 Jun;69(6):1042-7. doi: 10.1016/s0015-0282(98)00073-9. PMID: 9627290
- Geist SH, Salmon UJ. Androgen therapy in gynecology. *JAMA.* 1941, 117:2207-15.
- Ghiasi M, Kulkarni MT, Missmer SA. Is endometriosis more common and more severe than it was 30 years ago? *J Minim Invasive Gynecol.* 2020, 27(2):452-461. Epub 2019 Dec 6. PMID: 31816389
DOI: <https://doi.org/10.1016/j.jmig.2019.11.018>
- Gibson DA, Simitsidellis I, Collins F, Saunders PTK. Endometrial Intracrinology: Oestrogens, Androgens and Endometrial Disorders. *Int. J. Mol. Sci.* 2018, 19, 3276; doi:10.3390/ijms19103276, <https://www.mdpi.com/1422-0067/19/10/3276>
- Giudice LC, Kao LC. Endometriosis. *Lancet* 2004, 364:1789-99.
- Goldstein DP, De Chohnoky C, Emans SJ. Adolescent endometriosis. *J Adol Health Care.* 1980, 1:37-41.
- Goodwin JS, Goodwin, JM. The tomato effect. Rejection of highly efficacious therapies. *JAMA* 1984, 251: 2387-2390
- Goncalves MO, Siufi Neto J, Andres MP, Siufi D, de Mattos LA, Abrao MS. Systematic evaluation of endometriosis by transvaginal ultrasound can accurately replace diagnostic laparoscopy, mainly for deep and ovarian endometriosis. *Hum Reprod.* 2021 May 17;36(6):1492-1500. doi: 10.1093/humrep/deab085. PMID: 33864088
- González RS, Vnencak-Jones CL, Shi C, Fadare O. Endomyometriosis ("uterus-like mass") in an XY male: Case report with molecular confirmation and literature review. *Int J Surg Pathol.* 2014 Aug;22(5):421-6. doi: 10.1177/1066896913501385. Epub 2014 Mar 19. PMID: 24651910.
- González-Bonilla EA, Ruíz-García FJ, Estrada-Bujanos JM, de León-Castorena E. Ureteroscopic Excision of Distal Ureteral Endometriosis. *J Endourol Case Rep.* 2019 Dec 2;5(4):148-150. doi: 10.1089/cren.2019.0029. PMID: 32775649; PMCID: PMC7383438.
Open Access: <https://www.ncbi.nlm.nih.gov/pmc/articles/PMC7383438/>
- Gordts S, Koninckx P, Brosens I. Pathogenesis of deep endometriosis. *Fertil Steril* 2017, 108:872-85.

- Goriel LY et al. Large bowel perforation secondary to endometriosis, *J Surg Case Reports*, 2023, 8(August):rjad455, <https://doi.org/10.1093/jscr/rjad455>
Open Access: <https://academic.oup.com/jscr/article/2023/8/rjad455/7242270>
- Grandi G, Mueller MD, Papadia A, Kocbek V, Bersinger NA, Petraglia F, Cagnacci A, McKinnon B. Inflammation influences steroid hormone receptors targeted by progestins in endometrial stromal cells from women with endometriosis. *J Reprod Immunol*. 2016 Sep;117:30-8. doi: 10.1016/j.jri.2016.06.004. Epub 2016 Jun 17. PMID: 27371899.
- Green, L. W., et al. (2009). "Diffusion theory and knowledge dissemination, utilization, and integration in public health." *Ann Rev Public Health* 30: 151-174.
- Griffiths AN, Koutsouridou RN, Penketh RJ. Rectovaginal endometriosis -- a frequently missed diagnosis. *J Obstet Gynaecol*. 2007 Aug;27(6):605-7. doi: 10.1080/01443610701497660. PMID: 17896261.
- Gruber-Dujardin E, Bleyer M, Mätz-Rensing K. Morphological and immunohistochemical characterization of spontaneous endometriosis in rhesus macaques (*Macaca mulatta*). *Primate Biol*. 2017 Apr 13;4(1):77-91. doi: 10.5194/pb-4-77-2017. PMID: 32110695; PMCID: PMC7041517. Open Access: <https://pb.copernicus.org/articles/4/77/2017/>
- Gruenwald P. Origin of endometriosis from the mesenchyme of the celomic walls. *Am J Obstet Gynecol* 1942, 44:470-4. [https://doi.org/10.1016/S0002-9378\(42\)90484-8](https://doi.org/10.1016/S0002-9378(42)90484-8)
- Grümmer R. Models of endometriosis: In vitro and in vivo models. In Giudice LC, Evers JLH, Healy DL. (eds), *Endometriosis: Science and Practice*. 2012, John Wiley & Sons Publishers. Kindle Edition. <https://doi.org/10.1002/9781444398519.ch25>
- Grund S, Grummer R. Direct cell-cell interactions in the endometrium and in endometrial pathophysiology. *Int J Mol Sci* 2018, 19:2227. PMID: 30061539
PMC: <http://www.ncbi.nlm.nih.gov/pmc/articles/pmc6121364/>
DOI: <https://doi.org/10.3390/ijms19082227>
- Gu A, Bajžàk KI. Laparoscopic Excision vs Ablation for Endometriosis-Associated Pain: An Updated Systematic Review and Meta-Analysis. *J Minim Invasive Gynecol*. 2018 Feb;25(2):341. doi: 10.1016/j.jmig.2017.10.039. Epub 2017 Nov 24. PMID: 29180309.
- Guo SW, Wang Y. Sources of heterogeneities in estimating the prevalence of endometriosis in infertile and previously fertile women. *Fertil Steril*. 2006, 86(6):1584-95. doi: 10.1016/j.fertnstert.2006.04.040. Epub 2006 Oct 24. PMID: 17067588.
- Guo SW; Recurrence of endometriosis and its control, *Human Reproduction Update*, 2009, 15(4, July):441-461, <https://academic.oup.com/humupd/article/15/4/441/732833>
- Guo SW, Ding D, Shen M, Liu X. Dating endometriotic ovarian cysts based on the content of cyst fluid and its potential clinical implications. *Reprod Sci* 2015, 22:873-883.
- Guo SW. Fibrogenesis resulting from cyclic bleeding: The Holy Grail of the natural history of ectopic endometrium. *Hum Reprod*. 2018a, 33(3):353-356. doi: 10.1093/humrep/dey015. PMID: 29420711.
- Guo SW. Cancer driver mutations in endometriosis: Variations on the major theme of fibrogenesis. *Reprod Med Biol*. 2018b;1-29.

Guo SW, Martin DC. The perioperative period: a critical yet neglected time window for reducing the recurrence risk of endometriosis? *Hum Reprod*. 2019 Oct 2;34(10):1858-1865. doi: 10.1093/humrep/dez187. PMID: 31585460. <https://doi.org/10.1093/humrep/dez187>

Guo SW. Cancer-associated mutations in endometriosis: shedding light on the pathogenesis and pathophysiology. *Hum Reprod Update*. 2020a, 26(3):423-449. doi: 10.1093/humupd/dmz047. PMID: 32154564. <https://doi.org/10.1093/humupd/dmz047>

Guo SW. The pathogenesis of adenomyosis vis-à-vis endometriosis. *J Clin Med*. 2020b Feb 10;9(2):485. doi: 10.3390/jcm9020485. PMID: 32050720; PMCID: PMC7073526. Open access: <https://www.mdpi.com/2077-0383/9/2/485/htm>

Guo SW. How do women get endometriosis? *Reprod Biomed Online*. 2023 Nov 10:103696. doi: 10.1016/j.rbmo.2023.103696. Epub ahead of print. PMID: 38123408. Open Access: [https://www.rbmojournal.com/article/S1472-6483\(23\)00795-2/fulltext](https://www.rbmojournal.com/article/S1472-6483(23)00795-2/fulltext)

Gutke A, Sundfeldt K, De Baets L. Lifestyle and chronic pain in the pelvis: state of the art and future directions. *J Clin Med*. 2021 Nov 19;10(22):5397. doi: 10.3390/jcm10225397. PMID: 34830680; PMCID: PMC8622577.

Open Access: <https://www.mdpi.com/2077-0383/10/22/5397/htm>

Gawande A. *The Checklist Manifesto: How to Get Things Right* (1st Edition), 2009, Picador

Halban J. Hysteroadenosis metastatica. (Die lymphogene Genese der sogenannten Adenofibromatosis heterotopica.) *Wiener klinische Wochenschrift* 1924, 37:1205-6. quoted in Sampson 1927 *Am J Obstet Gynecol* 1927, 14:422-69 and Batt 2008 PhD thesis.

Hall MS, Talge NM, Upson K. Urinary cadmium and endometriosis prevalence in a US nationally representative sample: results from NHANES 1999–2006. *Human Reproduction*. 2023. doi:10.1093/humrep/dead117. [Online 24 July 2023] Open Access: <https://academic.oup.com/humrep/advance-article/doi/10.1093/humrep/dead117/7227951?login=false>

Halme J, Becker S, Hammond MG, Raj MH, Raj S. Increased activation of pelvic macrophages in infertile women with mild endometriosis. *Am J Obstet Gynecol*. 1983 Feb 1; 145(3):333-7.

Halme J, Hammond MG, Hulka JF, Raj SG, Talbert LM. Retrograde menstruation in healthy women and in patients with endometriosis. *Obstet Gynecol*. 1984 Aug; 64(2):151-4.

Halme J, White C, Kauma S, Estes J, Haskill S. Peritoneal macrophages from patients with endometriosis release growth factor activity in vitro. *J Clin Endocrinol Metab* 1988, 66:1044-9.

Haney AF. Endometriosis, macrophages, and adhesions. *Prog Clin Biol Res*. 1993, 381:19-44.

Harden S, Tan TY, Ku CW, Zhou J, Chen Q, Chan JKY, Brosens J, Lee YH. Peritoneal autoantibody profiling identifies p53 as an autoantibody target in endometriosis. *Fertil Steril*. 2023, S0015-0282(23)00154-1. doi: 10.1016/j.fertnstert.2023.02.025. Epub ahead of print. PMID: 36828054. Open Access: [https://www.fertstert.org/article/S0015-0282\(23\)00154-1/fulltext](https://www.fertstert.org/article/S0015-0282(23)00154-1/fulltext)

Hardman D, Bennett RD, Mikhail E. Fertility sparing double discoid excision of rectosigmoid Deep endometriosis under robotic-integrated ultrasound guidance. *Fertil Steril*. 2023a [online 7 October 2023]

- Hardman DE, Bennett R, Mikhail E. Ultrasound integrated robotic identification of sigmoid colon deep endometriosis in the absence of posterior cul de sac obliteration. *J Minim Invasive Gynecol*. 2023b, 30(11, Supplement, Nov): S50 (abstract).
<https://www.sciencedirect.com/science/article/abs/pii/S1553465023004892>. Open Access (S50):
<https://cdn.aagl.org/congress/2023/issue%20-%202023-10-23T123159.065.pdf>
- Hariyama Y, Ito M, Ohno K, Kiyono T, Kyo S, Iwase A, Kikkawa F, Kajiyama H, Kondo Y. Fusobacterium infection facilitates the development of endometriosis through the phenotypic transition of endometrial fibroblasts. *Sci Transl Med*. 2023 Jun 14;15(700):eadd1531. doi: 10.1126/scitranslmed.add1531. Epub 2023 Jun 14. PMID: 37315109.
- Harrison RF, Barry-Kinsella C. Efficacy of medroxyprogesterone treatment in infertile women with endometriosis: a prospective, randomized, placebo-controlled study. *Fertil Steril*. 2000 Jul;74(1):24-30. doi: 10.1016/s0015-0282(00)00577-x. PMID: 10899492.
Open Access: [https://www.fertstert.org/article/S0015-0282\(00\)00577-X/fulltext](https://www.fertstert.org/article/S0015-0282(00)00577-X/fulltext)
- Healey M, Ang WC, Cheng C. Surgical treatment of endometriosis: a prospective randomized double-blinded trial comparing excision and ablation. *Fertil Steril*. 2010 Dec;94(7):2536-40. doi: 10.1016/j.fertnstert.2010.02.044. Epub 2010 Mar 31. PMID: 20356588.
- Healey M, Cheng C, Kaur H. To excise or ablate endometriosis? A prospective randomized double-blinded trial after 5-year follow-up. *J Minim Invasive Gynecol*. 2014 Nov-Dec;21(6):999-1004. doi: 10.1016/j.jmig.2014.04.002. Epub 2014 Apr 24. PMID: 24768960.
- Herbst AL, Ulfelder H, Poskanzer DC. Adenocarcinoma of the vagina. Association of maternal stilbestrol therapy with tumor appearance in young women. *N Engl J Med*. 1971 Apr 15;284(15):878-81. doi: 10.1056/NEJM197104222841604. PMID: 5549830.
- Herrera-Perez D, Haslam A, Crain T, Gill J, Livingston C, Kaestner V, Hayes M, Morgan D, Cifu AS, Prasad V. A comprehensive review of randomized clinical trials in three medical journals reveals 396 medical reversals. *Elife*. 2019, 8:e45183. doi: 10.7554/eLife.45183. PMID: 31182188; PMCID: PMC6559784.
- Hill JA. Immunology and endometriosis. *Fertil Steril* 1992, 58(2):262-4. PMID:1633890
DOI: [https://doi.org/10.1016/s0015-0282\(16\)55213-3](https://doi.org/10.1016/s0015-0282(16)55213-3)
- Hirata T, Koga K, Osuga Y. Extra-pelvic endometriosis: A review. *Reprod Med Biol*. 2020 Jul 16;19(4):323-333. doi: 10.1002/rmb2.12340. PMID: 33071634; PMCID: PMC7542014.
Open access: <https://www.ncbi.nlm.nih.gov/pmc/articles/PMC7542014/>
- Hirsch M, Duffy JMN, Kuszniur JO, Davis CJ, Plana MN, Khan KS; International Collaboration to Harmonize Outcomes and Measures for Endometriosis. Variation in outcome reporting in endometriosis trials: a systematic review. *Am J Obstet Gynecol*. 2016 Apr;214(4):452-464. DOI: 10.1016/j.ajog.2015.12.039, PMID: 26778385
- Hogg C, Horne AW, Greaves E. Endometriosis-Associated Macrophages: Origin, Phenotype, and Function. *Front Endocrinol (Lausanne)*. 2020 Jan 23;11:7. doi: 10.3389/fendo.2020.00007. eCollection 2020. DOI: <https://doi.org/10.3389/fendo.2020.00007> PMID: 32038499
PMCID: <https://www.ncbi.nlm.nih.gov/pmc/articles/PMC6989423/>
- Holder MK, Blaustein JD. Puberty and adolescence as a time of vulnerability to stressors that alter neurobehavioral processes. *Front Neuroendocrinol*. 2014 Jan;35(1):89-110. doi:

10.1016/j.yfrne.2013.10.004. Epub 2013 Nov 1. PMID: 24184692; PMCID: PMC3946873.
Open access: <https://www.ncbi.nlm.nih.gov/pmc/articles/PMC3946873/>

Hollis R (Pete). He and I discussed palpation techniques for one of our patients in 1984. He taught me that post-resection palpation is needed to confirm that palpable nodules have been removed. These can be too deep for visualization. His three steps for nodules or focal tenderness that were discovered on exam in the office were:

- 1) Palpation on exam under anesthesia (EUA) for localization,
 - 2) Use a finger or probe to push the nodule up for better recognition/visualization and excision when needed.
 - 3) After excision, repeat palpation to confirm that the nodule was removed.
- Continue excision if the nodule is still present and then repeat palpation.

Hopton EN, Redwine DR. Eyes wide shut: the illusory tale of ‘occult’ microscopic endometriosis. *Human Reproduction*, 2014;29(3):384–387

Horne AW, Missmer SA. Pathophysiology, diagnosis, and management of endometriosis. *BMJ*. 2022 Nov 14;379:e070750. doi: 10.1136/bmj-2022-070750. PMID: 36375827.

Hoshiai H, Ishikawa M, Sawatari Y, Noda K, Fukaya T. Laparoscopic evaluation of the onset and progression of endometriosis. *Am J Obstet Gynecol* 1993, 169:714-9.

Hu Z, Mamillapalli R, Taylor HS. Increased circulating miR-370-3p regulates Steroidogenic Factor 1 in Endometriosis. *Am J Physiol Endocrinol Metab*. 2019 Mar 1;316(3):E373-E382
<https://www.ncbi.nlm.nih.gov/pubmed/30576245>

Huang Q, Chen Y, Chen Q, Zhang H, Lin Y, Zhu M, Dong S. Dioxin-like rather than non-dioxin-like PCBs promote the development of endometriosis through stimulation of endocrine–inflammation interactions. *Arch Toxicol*. DOI 10.1007/s00204-016-1854-0

Huang S, Xiao F, Guo SW, Zhang T. Tetramethylpyrazine retards the progression and fibrogenesis of endometriosis. *Reprod Sci*. 2022 Jan 31. doi: 10.1007/s43032-021-00813-x. Epub ahead of print. PMID: 35099777. Open Access: <https://link.springer.com/article/10.1007/s43032-021-00813-x>

Hueter, 1918, quoted in van der Linden 1996. Theories on the pathogenesis of endometriosis. *Hum Reprod* 1996, 11(suppl 3):53-65.

Hufnagel D, Li F, Cosar E, Krikun G, Taylor HS. The role of stem cells in the etiology and pathophysiology of endometriosis. *Semin Reprod Med*. 2015 Sep;33(5):333-40. doi: 10.1055/s-0035-1564609. Epub 2015 Sep 16. PMID: 26375413; PMCID: PMC4986990.
PMC (open access): <https://www.ncbi.nlm.nih.gov/pmc/articles/PMC4986990/>

Hughes CL, Foster WG, Agarwal SK. The impact of endometriosis across the lifespan of women: foreseeable research and therapeutic prospects. *Biomed Res Int*. 2015;2015:158490. doi: 10.1155/2015/158490. Epub 2015 May 6. PMID: 26064879; PMCID: PMC4438168
PMC open access: <https://www.ncbi.nlm.nih.gov/pmc/articles/PMC4438168/>

Hunsche E, Gauthier M, Witherspoon B, Rakov V, Agarwal SK. Endometriosis symptoms and their impacts on the daily lives of US women: Results from an interview study. *Int J Womens Health*. 2023 Jun 1;15:893-904. doi: 10.2147/IJWH.S409733. PMID: 37283994; PMCID: PMC10241351. Open Access: <https://www.dovepress.com/endometriosis-symptoms-and-their-impacts-on-the-daily-lives-of-us-wome-peer-reviewed-fulltext-article-IJWH>

Hunter JWA. Experimental endometrial grafts. *Br Med J.* 1927 Apr 30; 1(3460): 797-798
<https://www.ncbi.nlm.nih.gov/pmc/articles/PMC2454837/>

International Working Group of AAGL, ESGE, ESHRE and WES; Tomassetti C, Johnson NP, Petrozza J, Abrao MS, Einarsson JI, Horne AW, Lee TTM, Missmer S, Vermeulen N, Zondervan KT, Grimbizis G, De Wilde RL. An international terminology for endometriosis, 2021. *Hum Reprod Open.* 2021 Oct 22;2021(4):hoab029. doi: 10.1093/hropen/hoab029. PMID: 34693033; PMCID: PMC8530702.

Iwanoff, N.S. Drusiges cysthaltiges Uterusfibromyom kompliziert durch Sarcom und Carcinom (Adenofibromyoma cysticum arcomatodes carcinomatosum). *Monatsc fur Geburtsh und Gyndkol* 1898, 7:295-300. Quoted in Batt, 2011.

Izawa M, Harada T, Taniguchi F, Ohama Y, Takenaka Y, Terakawa N. An epigenetic disorder may cause aberrant expression of aromatase gene in endometriotic stromal cells. *Fertil Steril.* 2008 May;89(5 Suppl):1390-6. doi: 10.1016/j.fertnstert.2007.03.078. Epub 2007 Jul 26. PMID: 17662285.

Izawa M, Taniguchi F, Uegaki T, Takai E, Iwabe T, Terakawa N, Harada T. Demethylation of a nonpromoter cytosine-phosphate-guanine island in the aromatase gene may cause the aberrant up-regulation in endometriotic tissues. *Fertil Steril.* 2011 Jan;95(1):33-9. doi: 10.1016/j.fertnstert.2010.06.024. Epub 2010 Jul 23. PMID: 20655525.

Jackman JM, Vaid A, Agarwal S, Nezhat A, Nezhat C. Can we diagnosis endometriosis with a phone app? Nezhat endometriosis advisor mobile application as a predictor for endometriosis in patients experiencing pelvic pain, infertility or unexplained infertility. *Fertil Steril* 2020, 114,(3 Suppl):E539, Open Access: [https://www.fertstert.org/article/S0015-0282\(20\)32258-5/fulltext](https://www.fertstert.org/article/S0015-0282(20)32258-5/fulltext), App site: <https://endometriosis.app/>

Jacobson VC. Certain clinical and experimental aspects of ectopic endometriosis. *Bulletin of the New York Academy of Medicine.* 1925;1(9):385.
<https://www.ncbi.nlm.nih.gov/pmc/articles/PMC2387491/>

Jaeger-Lansky A, Schmidthaler K, Kuessel L, Gstöttner M, Waidhofer-Söllner P, Zlabinger GJ, Wenzl R, Eiwegger T. Local and systemic levels of cytokines and danger signals in endometriosis-affected women." *J Reprod Immunol* 2018, 130: 7-10.

Jaiswal A, Huang KG. "Energy devices in gynecological laparoscopy - Archaic to modern era". *Gynecol Minim Invasive Ther.* 2017, 6(4):147-151. doi: 10.1016/j.gmit.2017.08.002. Epub 2017 Sep 1. PMID: 30254903; PMCID: PMC6135185. Open Access: <https://www.sciencedirect.com/science/article/pii/S2213307016301241?via%3Dihub>

Jansen, R.P.S. & P. Russell. 1986. Nonpigmented endometriosis: clinical, laparoscopic, and pathologic definition. *Am. J. Obstet. Gynecol.* 155: 1154-1159.

Javert CT. Pathogenesis of endometriosis based on endometrial homeoplasia, direct extension, exfoliation and implantation, lymphatic and hematogenous metastasis, including five case reports of endometrial tissue in pelvic lymph nodes. *Cancer.* 1949 May;2(3):399-410. doi: 10.1002/1097-0142(194905)2:3<399::aid-cnrcr2820020304>3.0.co;2-l. PMID: 18131400. Open access: [https://acsjournals.onlinelibrary.wiley.com/doi/abs/10.1002/1097-0142\(194905\)2:3%3C399::AID-CNRCR2820020304%3E3.0.CO%3B2-L](https://acsjournals.onlinelibrary.wiley.com/doi/abs/10.1002/1097-0142(194905)2:3%3C399::AID-CNRCR2820020304%3E3.0.CO%3B2-L)

Jenkins TR, Liu CY, White J. Does Response to Hormonal Therapy Predict Presence or Absence of Endometriosis? *J Minimally Invas Gynecol*. 2008, 15:82–86

Jerman LF, Hey-Cunningham AJ. The role of the lymphatic system in endometriosis: a comprehensive review of the literature. *Biol Reprod* 2015, 92:64.

Jerman LF, Anderson L, Markham R, Hey-Cunningham AJ. The lymphatic system in endometriosis: a pilot study of endometrial-like cells and immune cell populations in lymph nodes associated with deep infiltrating bowel lesions. *Reprod Sci*. 2020 27(4):977-987. doi: 10.1007/s43032-020-00171-0. Epub 2020 Feb 19. PMID: 32077078.

PMID: <https://www.ncbi.nlm.nih.gov/pubmed/32077078>

Jiang, J., Yu, K., Jiang, Z., et al. IL-37 affects the occurrence and development of endometriosis by regulating the biological behavior of endometrial stromal cells through multiple signaling pathways. *Biological Chemistry*. 2018, 399(11):1325-1337.

Johnson NP, Hummelshoj L, Adamson GD, Keckstein J, Taylor HS, Abrao MS, Bush D, Kiesel L, Tamimi R, Sharpe-Timms KL, Rombauts L, Giudice LC; World Endometriosis Society Sao Paulo Consortium. World Endometriosis Society consensus on the classification of endometriosis. *Hum Reprod*. 2017 Feb;32(2):315-324. doi: 10.1093/humrep/dew293. Epub 2016 Dec 5. PMID: 27920089. Open: <https://academic.oup.com/humrep/article/32/2/315/2631390>

Jørgensen H, Fedorcsak P, Isaacson K, Tevonian E, Xiao A, Beste M, Qvigstad E, Lauffenburger D, Griffith L. Endometrial cytokines in patients with and without endometriosis evaluated for infertility. *Fertil Steril* 2022, [online February 04, 2022]. doi: 10.1016/j.fertnstert.2021.11.024

Kaiser Family Foundation. Impact of Direct-to-Consumer Advertising on Prescription Drug Spending. 2003, publication #6084, The Henry J. Kaiser Family Foundation, Menlo Park, CA

Kantor HI. The enigma of endometriosis. *Obstet Gynecol* 1964, 23:645-646

Kapoor R, Stratopoulou CA, Dolmans MM. Pathogenesis of endometriosis: New insights into prospective therapies. *Int J Mol Sci*. 2021 Oct 28;22(21):11700. doi: 10.3390/ijms222111700. PMID: 34769130; PMCID: PMC8583778. Open Access: <https://www.mdpi.com/1422-0067/22/21/11700>

Karnaky KJ. The use of stilbestrol for endometriosis; preliminary report. *South Med J*. 1948, 41(12):1109-11.

Karnaky KJ. Theories and known observations about hormonal treatment of endometriosis-in-situ, and endometriosis at the enzyme level. *Arizona Medicine* 1969;26:37-41.

Kats R, Metz CN, Akoum A: Macrophage migration inhibitory factor is markedly expressed in active and early-stage endometriotic lesions. *J Clin Endocrinol Metab*. 2002, 87(2): 883-889.

Kaunitz A, DiSant'Agnes PA: Needle tract endometriosis: An unusual complication of amniocentesis. *Obstet Gynecol* 1979, 54:753

Kavallaris A, Köhler C, Kühne-Heid R, Schneider A. Histopathological extent of rectal invasion by rectovaginal endometriosis. *Hum Reprod*. 2003 Jun;18(6):1323-7. doi: 10.1093/humrep/deg251. PMID: 12773467.

Kelly HA. Electrosurgery in Gynaecology. *Ann Surg* 1931, 93:323-5.

- Keettel WC, Stein RJ. The viability of the cast-off menstrual endometrium. *Am J Obstet Gynecol.* 1951 Feb;61(2):440-2. doi: 10.1016/0002-9378(51)90266-9. PMID: 14799567.
- Klipstein S. The role of compassionate reproductive care and counseling in the face of futility. *Fertil Steril.* 2023 Jan 13:S0015-0282(23)00050-X. doi: 10.1016/j.fertnstert.2023.01.012. Epub ahead of print. PMID: 36642300.
- Khan KN, Kitajima M, Hiraki K, Yamaguchi N, Katamine S, Matsuyama T, Fujishita A, Nakashima M, Ishimaru T, Masuzaki H. Escherichia coli contamination of menstrual blood and effect of bacterial endotoxin on endometriosis. *Fertil Steril* 2010, 94:2860-2863.
- Khan KN, Fujishita A, Kitajima M, et al. Occult microscopic endometriosis: undetectable by laparoscopy in normal peritoneum. *Hum Reprod* 2014, 29:462-72.
- Khan KN, Kitajima M, Fujishita A, Nakashima M, Masuzaki H, Kitawaki J. Role of bacterial contamination in endometriosis. *J Endometriosis Pelvic Pain Disorders* 2016, 8:2-7.
- Khare VK, Martin DC, Kaigh J. Buttonhole ulceration and perforation of the rectum. *J Am Assoc Gynecol Laparosc.* 1993 Nov;1(1):12-5. doi: 10.1016/s1074-3804(05)80751-0. PMID: 9050453.
- Khare VK, Martin DC, Eltorkey M. A comparative study of ovarian and pelvic wall-infiltrating endometriosis. *J Am Assoc Gynecol Laparosc.* 1996 Feb;3(2):235-9. doi: 10.1016/s1074-3804(96)80006-5. PMID: 9050632.
- Khashchenko EP, Vysokikh MY, Marey MV, Sidorova KO, Manukhova LA, Shkavro NN, Uvarova EV, Chuprynin VD, Fatkhudinov TK, Adamyan LV, Sukhikh GT. Altered Glycolysis, Mitochondrial Biogenesis, Autophagy and Apoptosis in Peritoneal Endometriosis in Adolescents. *Int J Molecular Sci.* 2024; 25(8):4238. doi: 10.3390/ijms25084238
Open Access: <https://www.mdpi.com/1422-0067/25/8/4238>
- Kiss I, Pospisilova E, Kolostova K, et al. Circulating endometrial cells in women with spontaneous pneumothorax. *Chest.* 2020;157(2):342–355. doi: 10.1016/j.chest.2019.09.008, PMID: 31542450
- Kistner RW. The use of newer progestins in the treatment of endometriosis. *Am J Obstet Gynecol.* 1958, 75:264-78.
- Kistner RW. Management of endometriosis in the infertile patient. *Fertil Steril.* 1975 Dec; 26(12):1151-66.
- Klages R. *Zeitschr fur Geb und Gynak* 1912; Bd. lxx: S. 858. Quoted in Lockyer 1918a, p295. https://www.google.com/books/edition/Fibroids_and_Allied_Tumours_myoma_and_Ad/ljyg419t70UC?hl=en&gbpv=0
- Klemmt PA, Carver JG, Kennedy SH, Koninckx PR, Mardon HJ. Stromal cells from endometriotic lesions and endometrium from women with endometriosis have reduced decidualization capacity. *Fertil Steril* 2006, 85(3): 564-72. <https://www.ncbi.nlm.nih.gov/pmc/articles/PMC1626574/>
- Klemmt PA, Carver JG, Koninckx PR, McVeigh E, Mardon HJ. Endometrial cells from women with endometriosis have increased adhesion and proliferative capacity in response to extracellular matrix components: stick toward a mechanistic model for endometriosis progression. 2007, 22:3139-3147

Klemmt P, Starzinski-Powitz A. Molecular and cellular pathogenesis of endometriosis. *Current Women's Health Reviews*, 2018, 14:106-116. DOI: 10.2174/1573404813666170306163448
<https://www.ncbi.nlm.nih.gov/pmc/articles/PMC5925869/>

Knapp VJ. How old is endometriosis? Late 17th and 18th-century European descriptions of the disease. *Fertil Steril* 1999, 72:10-4.

Knez J, Bean E, Nijjar S, Tellum T, Chaggar P, Jurkovic D. Natural progression of deep pelvic endometriosis in women who opt for expectant management. *Acta Obstet Gynecol Scand*. 2023 May 15. doi: 10.1111/aogs.14491. Epub ahead of print. PMID: 37190782.

Open Access: <https://obgyn.onlinelibrary.wiley.com/doi/10.1111/aogs.14491>

Knox B, Ong YC, Bakar MA, Grover SR. A longitudinal study of adolescent dysmenorrhoea into adulthood. *Eur J Pediatr*. 2019, 178(9):1325-1332. doi: 10.1007/s00431-019-03419-3.

Epub 2019 Jul 10. PMID: 31292729. <https://doi.org/10.1007/s00431-019-03419-3>

Kobayashi H, Higashiura Y, Shigetomi H, Kajihara H. Pathogenesis of endometriosis: the role of initial infection and subsequent sterile inflammation (Review). *Mol Med Rep* 2014, 9:9-15. doi: 10.3892/mmr.2013.1755

Kobayashi H. Similarities in pathogenetic mechanisms underlying the bidirectional relationship between endometriosis and pelvic inflammatory disease. *Diagnostics (Basel)*. 2023a Feb 24;13(5):868. doi: 10.3390/diagnostics13050868. PMID: 36900012.

Open Access <https://doi.org/10.3390/diagnostics13050868>

Kobayashi H. Gut and reproductive tract microbiota: Insights into the pathogenesis of endometriosis (Review). *Biomed Rep*. 2023b May 29;19(1):43. doi: 10.3892/br.2023.1626. PMID: 37324168; PMCID: PMC10265574.

Open Access: <https://www.spandidos-publications.com/10.3892/br.2023.1626>

Kodati VL, Govindan S, Movva S, Ponnala S, Hasan Q. Role of Shigella infection in endometriosis: a novel hypothesis. *Med Hypotheses* 2008; 70:239-43.

Kohl Schwartz AS, Wolfler MM, Mitter V, et al. Endometriosis, especially mild disease: a risk factor for miscarriages. *Fertility and Sterility*, 2017, 108 (5):806-814.e2.

Open Access: [https://www.fertstert.org/article/S0015-0282\(17\)31747-8/pdf](https://www.fertstert.org/article/S0015-0282(17)31747-8/pdf)

Koninckx PR, Ide P, Vandenbroucke W, Brosens IA. New aspects of the pathophysiology of endometriosis and associated infertility. *J Reprod Med*. 1980, 24(6):257-260.

PMID: 7420327, <https://pubmed.ncbi.nlm.nih.gov/7420327/>

Koninckx PR, Meuleman C, Demeyere S, Lesaffre E, Cornillie FJ. Suggestive evidence that pelvic endometriosis is a progressive disease, whereas deeply infiltrating endometriosis is associated with pelvic pain. *Fertil Steril*. 1991 Apr;55(4):759-65. doi: 10.1016/s0015-0282(16)54244-7. PMID: 2010001. Open Access:

<https://www.sciencedirect.com/science/article/pii/S0015028216542447?via%3Dihub>

Koninckx PR, Martin DC. Deep endometriosis: a consequence of infiltration or retraction or possibly adenomyosis externa? *Fertil Steril*. 1992 Nov;58(5):924-8. doi: 10.1016/s0015-0282(16)55436-3. PMID: 1426377. Open Access:

<https://www.sciencedirect.com/science/article/pii/S0015028216554363?via%3Dihub>

Koninckx PR, Cornillie FJ: Infiltrating Endometriosis: Infiltration, Retraction or Adenomyosis Externa? In *Atlas of Endometriosis*. Edited by Martin D. London: Gower Medical Publishing; 1993:9.1-9.8.

Koninckx PR. Is mild endometriosis a condition occurring intermittently in all women? *Human Reproduction* 1994, 9:2202-5.

Koninckx PR, Meuleman C, Oosterlynck D, Cornillie FJ. Diagnosis of deep endometriosis by clinical examination during menstruation and plasma CA-125 concentrations. *Fertil Steril* 1996, 65:280-287

Koninckx PR, Barlow D, Kennedy S. Implantation versus infiltration: the Sampson versus the endometriotic disease theory. *Gynecol Obstet Invest* 1999;47(Suppl 1):3-9. Discussion 9-10. Open access: http://www.gynsurgery.org/wp-content/uploads/1999_pk_edt.pdf

Koninckx PR, Ussia A, Keckstein J, Wattiez A, Adamyan L. Epidemiology of subtle, typical, cystic, and deep endometriosis: a systematic review. *Gynecol Surg* 2016, 13:457-467

Koninckx PR, Ussia A, Adamyan L, Wattiez A, Gomel V, Martin DC. Pathogenesis of endometriosis: the genetic/epigenetic theory. *Fertil Steril*. 2019a Feb;111(2):327-340. doi: 10.1016/j.fertnstert.2018.10.013. Epub 2018 Dec 7. PMID: 30527836.

Open Access: <https://doi.org/10.1016/j.fertnstert.2018.10.013>

Koninckx PR, Ussia A, Tahlak M, Adamyan L, Wattiez A, Gomel V, Martin DC. Infection as a potential cofactor in the genetic-epigenetic pathophysiology of endometriosis: a systematic review. *Facts Views Vis Obgyn*. 2019b, 11(3):209-216. PMID: 32082526

Open Access PMC: <https://www.ncbi.nlm.nih.gov/pmc/articles/PMC7020943/>

Koninckx PR, Ussia A, Wattiez A, Adamyan L, Martin DC, Gordts S. The severity and frequency distribution of endometriosis subtypes at different ages: a model to understand the natural history of endometriosis based on single centre/single surgeon data. *Facts Views Vis Obgyn*, 2021, 13 (3): 211-221. doi.org/10.52054/FVVO.13.3.028

Open Access: <https://fvvo.eu/assets/938/FVVinObGyn-13-211.pdf>

Koppolu A, Maksym RB, Paskal W, Machnicki M, Rak B, Pępek M, Garbicz F, Pełka K, Kuśmierczyk Z, Jacko J, Rydzanicz M, Banach-Orłowska M, Stokłosa T, Płoski R, Malejczyk J, Włodarski PK. Epithelial cells of deep infiltrating endometriosis harbor mutations in cancer driver genes. *Cells*. 2021, 10(4):749. doi: 10.3390/cells10040749

Open access: <https://doi.org/10.3390/cells10040749>

Kossmann R. Die Abstammung der Drüseneinschlüsse in der Uterus und der Tuben. *Archiv für Gynak* 1897; Bd. liv. S:359, 381. Quoted in Batt 2008 and Batt 2011a.

Kotlyar A, Shue S, Liu X, Falcone T. Effect of disease-modifying anti-rheumatic drugs on therapeutic outcomes among women with endometriosis. *Int J Gynaecol Obstet*. 2017 Dec 4. doi: 10.1002/ijgo.12416. PMID: 29205346

Kotlyar A, Taylor HS, D'Hooghe TM. Use of immunomodulators to treat endometriosis. *Best Pract Res Clin Obstet Gynaecol*. 2019 Oct;60:56-65. doi: 10.1016/j.bpobgyn.2019.06.006. PMID: 31515196.

Koukoura O, Sifakis S, Spandidos DA. DNA methylation in endometriosis (Review). *Mol Med Rep*. 2016 Apr;13(4):2939-48. doi: 10.3892/mmr.2016.4925. Epub 2016 Feb 22. PMID:

26934855; PMCID: PMC4805102.

Open Access: <https://www.spandidos-publications.com/mmr/13/4/2939>

Kubota T, Miyake K, Hirasawa T, Onaka T, Yamasue H. Epigenetic modulation of human neurobiological disorders. In Tollefsbol TO. Epigenetics in Human Disease. 2012, Elsevier, Inc. London. pages 193-203

Lac V, Verhoef L, Aguirre-Hernandez R, Nazeran TM, Tessier-Cloutier B, Praetorius T, Orr NL, Noga H, Lum A, Khattra J, Prentice LM, Co D, Köbel M, Mijatovic V, Lee AF, Pasternak J, Bleeker MC, Krämer B, Brucker SY, Kommoss F, Kommoss S, Horlings HM, Yong PJ, Huntsman DG, Anglesio MS. Iatrogenic endometriosis harbors somatic cancer-driver mutations. *Hum Reprod.* 2019, 34(1):69-78.

Laganà AS, Vitale SG, Salmeri FM, et al. Unus pro omnibus, omnes pro uno: A novel, evidence-based, unifying theory for the pathogenesis of endometriosis. *Med Hypotheses* 2017, 103:10-20

Laganà AS, Garzon S, Götte M, Viganò P, Franchi M, Ghezzi F, Martin DC. The pathogenesis of endometriosis: molecular and cell biology insights. *Int J Mol Sci.* 2019 Nov 10;20(22):5615. doi: 10.3390/ijms20225615. PMID: 31717614; PMCID: PMC6888544.

PMC Open Access <https://www.ncbi.nlm.nih.gov/pmc/articles/PMC6888544/>

Laganà AS, Garzon S, Casarin J, Raffaelli R, Cromi A, Franchi M, Ghezzi F. Know your enemy: Potential role of cabergoline to target neoangiogenesis in endometriosis. *J Invest Surg.* 2020, 11:1-2. doi: 10.1080/08941939.2020.1725191. Epub ahead of print. PMID: 32046558. <https://doi.org/10.1080/08941939.2020.1725191>

La Greca G, Colarossi C, Di Mattia P, Gozzo C, De Zuanni M, Piombino E, Memeo L. Endomyometriosis of the rectum with disseminated peritoneal leiomyomatosis 8 years after laparoscopic myomectomy: A case report. *Front. Surg.* 2021, 8:666147. doi: 10.3389/fsurg.2021.666147

Lamceva J, Uljanovs R, Strumfa I. The main theories on the pathogenesis of endometriosis. *Int J Mol Sci.* 2023 Feb 21;24(5):4254. doi: 10.3390/ijms24054254. PMID: 36901685. Open Access: <https://www.mdpi.com/1422-0067/24/5/4254>

Landin-Romero R, Moreno-Alcazar A, Pagani M, Amann BL. How does eye movement desensitization and reprocessing therapy work? A Systematic Review on Suggested Mechanisms of Action. *Front Psychol.* 2018, 9:1395. <https://www.ncbi.nlm.nih.gov/pmc/articles/pmid/30166975/>

Lauchlan SC. The secondary Mullerian system. *Obstet Gynecol Survey,* 1972, 27:133-146.

Laufer MR, Einarsson JI. Surgical management of superficial peritoneal adolescent endometriosis. *J Pediatr Adolesc Gynecol.* 2019 Jun;32(3):339-341. doi: 10.1016/j.jpag.2019.01.005. Epub 2019 Jan 29. PMID: 30708067.

Laux-Biehlmann A, d'Hooghe T, Zollner TM. Menstruation pulls the trigger for inflammation and pain in endometriosis. *Trends Pharmacol Sci* 2015, 36:270-6.

Law J. *After Method, Mess in Social Science Research.* 2004. Routledge, Taylor & Francis Group, Abingdon, Oxon, <https://www.routledge.com/After-Method-Mess-in-Social-Science-Research/Law/p/book/9780415341752>. Kindle version at Amazon

- Law YY, Patel R, Yorke R, Bailey HR, Van Eps JL. A case of infiltrative cecal endometriosis with appendiceal obliteration and lymph node involvement. *J Surg Case Rep*. 2020 Oct 31;2020(10):rjaa396. doi: 10.1093/jscr/rjaa396. PMID: 33154806; PMCID: PMC7602694
- Le NXH, Loret de Mola JR, Bremer P, Groesch K, Wilson T, Diaz-Sylvester P, Braundmeier-Fleming AG. Alteration of systemic and uterine endometrial immune populations in patients with endometriosis. *Am J Reprod Immunol*. 2020 Oct 18:e13362. doi: 10.1111/aji.13362. Epub ahead of print. PMID: 33070438.
- Lee CE, Allaire C, Williams C, Bedaiwy MA, Noga H, Hanley GE, Lisonkova S, Albert A, Yong PJ. Outcomes after surgery at an interdisciplinary centre of expertise for endometriosis and pelvic pain in Canada: A Prospective Cohort Study. *J Obstet Gynaecol Can*. 2024 Feb;46(2):102246. doi: 10.1016/j.jogc.2023.102246. PMID: 38442956.
- Lee M, Yu L. Cecal endometriosis presenting as a term intrauterine fetal demise and gastrointestinal hemorrhage: A case report. *Case Reports in Women's Health*. 2021, 30:e00301, ISSN 2214-9112. DOI: <https://doi.org/10.1016/j.crwh.2021.e00301>.
- Lenz J, Chvatal R, Fiala L, Konecna P, Lenz D. Comparative immunohistochemical study of deep infiltrating endometriosis, lymph node endometriosis and atypical ovarian endometriosis including description of a perineural invasion. *Biomed Pap Med Fac Univ Palacky Olomouc Czech Repub*. 2020 Mar 9. doi: 10.5507/bp.2020.006. PMID: 32158015.
- Leonardi M, Hicks C, El-Assaad F, El-Omar E, Condous G. Endometriosis and the microbiome: a systematic review. *BJOG*. 2020a, 127(2):239–249. doi:10.1111/1471-0528.15916. PMID: 31454452, DOI: <https://doi.org/10.1111/1471-0528.15916>
ResearchGate: <https://www.researchgate.net/publication/335434619>
- Leonardi M, Robledo KP, Espada M, Vanza K, Condous G. SonoPODography: A new diagnostic technique for visualizing superficial endometriosis. *Eur J Obstet Gynecol Reprod Biol*. 2020b Nov;254:124-131. doi: 10.1016/j.ejogrb.2020.08.051. Epub 2020 Sep 16. PMID: 32961428.
- Lessey BA, Castelbaum AJ, Sawin SW, Sun J. Integrins as markers of uterine receptivity in women with primary unexplained infertility. *Fertil Steril*. 1995 Mar;63(3):535-42. PMID: 7851583.
- Lessey BA, Kim JJ. Endometrial receptivity in the eutopic endometrium of women with endometriosis: it is affected, and let me show you why. *Fertil Steril*. 2017 Jul;108(1):19-27. doi: 10.1016/j.fertnstert.2017.05.031. Epub 2017 Jun 14. PMID: 28602477; PMCID: PMC5629018. Open Access: [https://www.fertstert.org/article/S0015-0282\(17\)30414-4/fulltext](https://www.fertstert.org/article/S0015-0282(17)30414-4/fulltext)
- Leuenberger J, Kohl Schwartz AS, Geraedts K, Haeblerlin F, Eberhard M, von Orellie S, Imesch P, Leeners B. Living with endometriosis: Comorbid pain disorders, characteristics of pain and relevance for daily life. *Eur J Pain*. 2022 May;26(5):1021-1038. doi: 10.1002/ejp.1926. Epub 2022 Feb 27. PMID: 35184363.
Open access: <https://onlinelibrary.wiley.com/doi/10.1002/ejp.1926>
- Levander G, Normann, P. The pathogenesis of endometriosis. An experimental study. *Acta Obstet Gynecol Scand*, 1955, 34:366-398. doi: 10.3109/00016345509158287. PMID: 13301610.

- Leyendecker G, Kunz G, Noe M et al. Endometriosis: a dysfunction and disease of the archimetra. *Hum Reprod Update* 1998, 4:752-762. DOI: 10.1093/humupd/4.5.752
Open Access: <https://academic.oup.com/humupd/article/4/5/752/592270>
- Leyendecker G, Wildt L, Mall G. The pathophysiology of endometriosis and adenomyosis. Tissue injury and repair. *Arch Gynecol Obstet* 2009, 280:529-538. DOI 10.1007/s00404-009-1191-0, PMID: 19644696, PMC: <http://www.ncbi.nlm.nih.gov/pmc/articles/pmc2730449/>
- Leyendecker G, Bilgicyildirim A, Inacker M, Stalf T, Huppert P, Mall G, Böttcher B, Wildt L. Adenomyosis and endometriosis. Re-visiting their association and further insights into the mechanisms of auto-traumatisation. An MRI study. *Arch Gynecol Obstet*. 2015, 291(4):917–932 DOI 10.1007/s00404-014-3437-8. PMID: 25241270,
PMC Open Access: <http://www.ncbi.nlm.nih.gov/pmc/articles/pmc4355446/>
- Leyendecker G, Wildt L, Laschke MW, Mall G. Archimetrosis: the evolution of a disease and its extant presentation. *Arch Gynecol Obstet*. 2022. [online 22 May 2022] doi: 10.1007/s00404-022-06597-y. Open Access: <https://doi.org/10.1007/s00404-022-06597-y>
- Li B, Yuxue Zhang, Liuhan Zhang & Lingyan Zhang (2023) Association between endometriosis and metabolic syndrome: a cross-sectional study based on the National Health and Nutrition Examination Survey data, *Gynecological Endocrinology*, 39:1, DOI: 10.1080/09513590.2023.2254844 Open Access: <https://www.tandfonline.com/doi/full/10.1080/09513590.2023.2254844?scroll=top&needAccess=true&role=tab>
- Li F, Alderman MH 3rd, Tal A, Mamillapalli R, Coolidge A, Hufnagel D, Wang Z, Neisani E, Gidicsin S, Krikun G, Taylor HS. Hematogenous dissemination of mesenchymal stem cells from endometriosis. *Stem Cells*. 2018, 36(6):881-890. doi: 10.1002/stem.2804. PMID: 29450941; PMCID: PMC5992028. PMC: <https://www.ncbi.nlm.nih.gov/labs/pmc/articles/PMC5992028/>
- Li WN, Wu MH, Tsai SJ. Hypoxia and reproductive health: The role of hypoxia in the development and progression of endometriosis. *Reproduction*. 2021 Jan;161(1):F19-F31. doi: 10.1530/REP-20-0267. PMID: 33112784.
Open access: <https://rep.bioscientifica.com/view/journals/rep/161/1/REP-20-0267.xml>
- Li Q, Rycaj K, Chen X, Tang DG. Cancer stem cells and cell size: A causal link? *Semin Cancer Biol*. 2015 Dec;35:191-9. doi: 10.1016/j.semcancer.2015.07.002. Epub 2015 Aug 1. PMID: 26241348; PMCID: PMC4651715.
Open access: <https://www.ncbi.nlm.nih.gov/pmc/articles/PMC3262453/>
- Liang Y, Yao S. Potential role of estrogen in maintaining the imbalanced sympathetic and sensory innervation in endometriosis. *Mol Cell Endocrinol*. 2016 Mar 15;424:42-9. doi: 10.1016/j.mce.2016.01.012. PMID: 26777300. Open Access: <https://www.sciencedirect.com/science/article/pii/S0303720716300120?via%3Dihub>
- Liang Y, Xie H, Wu J, Liu D, Yao S. Villainous role of estrogen in macrophage-nerve interaction in endometriosis. *Reprod Biol Endocrinol*. 2018 Dec 5;16(1):122. doi: 10.1186/s12958-018-0441-z. PMID: 30518376; PMCID: PMC6282253
PMC: <https://www.ncbi.nlm.nih.gov/pmc/articles/PMC6282253/>
Open Access: <https://rbej.biomedcentral.com/articles/10.1186/s12958-018-0441-z>

Liang Y, Wu J, Wang W, Xie H, Yao S. Pro-endometriotic niche in endometriosis. *Reprod BioMed Online*. 2019, 38 (4):549-559. PMID: 30772194

Open Access <https://www.sciencedirect.com/science/article/pii/S1472648318306540>

Liang Y, Mei L, Ning Q, Zhang J, Fei J, Dong J. A case of rectal endometriosis misdiagnosed as rectal malignancy on three colonoscopies and biopsies sharing a combined literature review. *Int J Womens Health*. 2024;16:163-174. doi: 10.2147/IJWH.S445280

Open Access: <https://doi.org/10.2147/IJWH.S445280>

Likes CE, Cooper LJ, Efirid J, Forstein DA, Miller PB, Savaris R, Lessey BA. Medical or surgical treatment before embryo transfer improves outcomes in women with abnormal endometrial BCL6 expression. *J Assist Reprod Genet*. 2019 Mar;36(3):483-490. doi: 10.1007/s10815-018-1388-x. Epub 2019 Jan 4. PMID: 30610661; PMCID: PMC6439015.

Open Access: <https://www.ncbi.nlm.nih.gov/pmc/articles/PMC6439015/>

Lin YH, Chen YH, Chang HY, Au HK, Tzeng CR, Huang YH. Chronic niche inflammation in endometriosis-associated infertility: Current understanding and future therapeutic strategies. *Int J Mol Sci*. 2018 Aug 13;19(8):2385. doi: 10.3390/ijms19082385. PMID: 30104541; PMCID: PMC6121292.

Lin YH, Yang YC, Chen SF, Hsu CY, Shen YC. Risk of systemic lupus erythematosus in patients with endometriosis: A nationwide population-based cohort study. *Arch Gynecol Obstet*. 2020, 302(5):1197-1203. doi: 10.1007/s00404-020-05726-9. PMID: 32767040.

Ling F quoted in Vandivier H. Primary Care. *Wabash Magazine*. Winter, 1998
<https://www.wabash.edu/magazine/1998/winter/features/ling.htm> accessed 02/19/2019.

Ling FW and the Pelvic Pain Study Group. Randomized controlled trial of depot leuprolide in patients with chronic pelvic pain and clinically suspected endometriosis. *Obstet Gynecol*. 1999, 93(1):51-8. doi: 10.1016/s0029-7844(98)00341-x. PMID: 9916956.

Liu DT, Hitchcock A. Endometriosis: its association with retrograde menstruation, dysmenorrhoea and tubal pathology. *Br J Obstet Gynaecol*. 1986 Aug;93(8):859-62. doi: 10.1111/j.1471-0528.1986.tb07995.x. PMID: 3741813.

Liu X, Zhang Q, Guo SW. Histological and immunohistochemical characterization of the similarity and difference between ovarian endometriomas and deep infiltrating endometriosis. *Reprod Sci* 2017, (pre-publication DOI: 10.1177/1933719117718275, PMID 28718381):1-10.

Lockyer C. Adenomyoma in the recto-uterine and recto-vaginal septa. *Proc Royal Soc Med*. 1913, 6:112-20.

Lockyer, Cuthbert (ed) *Fibroids and Allied Tumours (Myoma and Adenomyoma)*. Macmillan and Co. Limited, London Co, 1918a.

https://www.google.com/books/edition/Fibroids_and_Allied_Tumours_myoma_and_Ad/ljyg419t70UC?hl=en&gbpv=0

Lockyer C, A New Classification of Adenomyoma, in Lockyer C (ed) *Fibroids and allied tumours (myoma and adenomyoma) Their pathology, clinical features and surgical treatment*. Macmillan and Co. Limited, London, 1918b, pp 306-378.

https://www.google.com/books/edition/Fibroids_and_Allied_Tumours_myoma_and_Ad/ljyg419t70UC?hl=en&gbpv=0

Long Q, Liu X, Guo SW. Surgery accelerates the development of endometriosis in mice. *Am J Obstet Gynecol*. 2016, Sep;215(3):320.e1-320.e15. doi: 10.1016/j.ajog.2016.02.055. Epub 2016 Mar 3. PMID: 26945602.

Open Access: [https://www.ajog.org/article/S0002-9378\(16\)00397-5/fulltext](https://www.ajog.org/article/S0002-9378(16)00397-5/fulltext)

Long Q, Zheng H, Liu X, Guo S-W. Perioperative intervention by b-blockade and NF-kB suppression reduces the recurrence risk of endometriosis in mice due to incomplete excision. *Reprod Sci* 2018, 26(5), 697–708. PMID: 30764712

DOI: <https://doi.org/10.1177/1933719119828066>

Publisher's Site: <https://journals.sagepub.com/doi/full/10.1177/1933719119828066>

Long Q, Liu X, Guo S. Early maternal separation accelerates the progression of endometriosis in adult mice. *Reprod Biol Endocrinol*. 2020, 18, 63. doi: 10.1186/s12958-020-00600-4.

Open Access <https://doi.org/10.1186/s12958-020-00600-4>

Longo LD. Aberrant portions of the müllerian duct found in an ovary: William Wood Russell Johns Hopkins Hospital Bulletin, vol. 10, pp. 8--10, 1899. *Am J Obstet Gynecol*. 1979, 134:225-6. PMID 377966

Lu Q, Huang Y, Wu J, Guan Y, Du M, Wang F, Liu Z, Zhu Y, Gong G, Hou H, Zhang M, Zhang JY, Ning F, Chen L, Wang L, Lash GE. T-cadherin inhibits invasion and migration of endometrial stromal cells in endometriosis. *Hum Reprod*. 2020, 35(1):145-156.

PMID: 31886853

DOI: <https://doi.org/10.1093/humrep/dez252>

Luo X, Cheng W, Wang S, Chen Z, Tan J. Autophagy suppresses invasiveness of endometrial cells through reduction of Fascin-1. *Biomed Res Int*. 2018, 2018:8615435. DOI: 10.1155/2018/8615435. eCollection 2018.

Macer ML, Taylor HS. Endometriosis and infertility: a review of the pathogenesis and treatment of endometriosis-associated infertility. *Obstet Gynecol Clin North Am*. 2012 Dec;39(4):535-49. doi: 10.1016/j.ogc.2012.10.002. PMID: 23182559; PMCID: PMC3538128.

Maia H, Casoy J, Correia T, Freitas LA, Pimentel K, Athayde C. The effect of oral contraceptives on aromatase expression in the eutopic endometrium of patients with endometriosis. *Gynecol Endocrin*. 2008, 24(3): 123–128 doi: 10.1080/09513590801890816.

PMID: 18335325. <https://www.tandfonline.com/doi/full/10.1080/09513590801890816>

Mackenzie SC, Stephen J, Williams L, Daniels J, Norrie J, Becker CM, Byrne D, Cheong Y, Clark TJ, Cooper KG, Cox E, Doust AM, Fernandez P, Hawe J, Holland T, Hummelshoj L, Jackson LJ, King K, Maheshwari A, Martin DC, Sutherland L, Thornton J, Vincent K, Vyas S, Horne AW, Whitaker LHR. Effectiveness of laparoscopic removal of isolated superficial peritoneal endometriosis for the management of chronic pelvic pain in women (ESPrIT2): protocol for a multi-centre randomised controlled trial. *Trials*. 2023 Jun 22;24(1):425. doi: 10.1186/s13063-023-07386-x. PMID: 37349849; PMCID: PMC10286505.

PMC Open Access: <https://www.ncbi.nlm.nih.gov/pmc/articles/PMC10286505/>

Makiyan Z. Endometriosis origin from primordial germ cells. *Organogenesis*. 2017 Jul 3;13(3):95-102. doi: 10.1080/15476278.2017.1323162. Epub 2017 May 9. PMID: 28486048; PMCID: PMC5654850.

Open Access: <https://www.tandfonline.com/doi/full/10.1080/15476278.2017.1323162>

Maksym RB, Hoffmann-Młodzianowska M, Skibińska M, Rabijewski M, Mackiewicz A, Kieda C. Immunology and Immunotherapy of Endometriosis. *J Clin Med*. 2021 Dec 15;10(24):5879. doi: 10.3390/jcm10245879. PMID: 34945174; PMCID: PMC8708975.

Open Access: <https://www.mdpi.com/2077-0383/10/24/5879/htm>

Malinak LR. Management of endometriosis in the infertile female. In *The Infertile Female*, Edited by JR Givens. Yearbook Medical Publishers, Chicago, 1979, p 359-375. ISBN: 0-8151-3527-0. (p 362)

Mamillapalli R, Mutlu L, Taylor HS. Characterization of bone marrow progenitor cell uterine engraftment and transdifferentiation. *Reprod Sci*. 2021 Sep 13. doi: 10.1007/s43032-021-00738-5. PMID: 34515983.

Manavella D, Cacciottola L, Pommé S, Desmet CM, Jordan BF, Donnez J, Amorim CA, Dolmans M-M. Two-step transplantation with adipose tissue-derived stem cells increases follicle survival by enhancing vascularization in xenografted-human ovarian tissue. *Hum Reprod*. 2018 Jun 1;33(6):1107-1116. doi: 10.1093/humrep/dey080.

Maniglio P, Ricciardi E, Meli F, Vitale SG, Noventa M, Vitagliano A, Valenti G, La Rosa VL, Laganà AS, Caserta D. Catamenial pneumothorax caused by thoracic endometriosis. *Radiol Case Rep*. 2017 Oct 13;13(1):81-85. doi: 10.1016/j.radcr.2017.09.003. PMID: 29552245; PMCID: PMC5850814. <https://www.ncbi.nlm.nih.gov/pmc/articles/PMC5850814/>

Marcellin L, Méhats C, Gogusev J. Histopathological alterations in fetal membranes of women with endometriosis. *Reprod Sci*, 2018, 25(5), 782–787. <https://doi.org/10.1177/1933719117728804>

Marchand FJ, Beiträge zur Kenntniss der Ovarialtumoren, Abbandl der Naturf Gesellsch, 1879 xiv: Habittationsschrift, Halle: 1879. Quoted in Russell 1899.

Margatho D, Mota Carvalho N, Eloy L, Bahamondes L. Assessment of biomarkers in women with endometriosis-associated pain using the ENG contraceptive implant or the 52 mg LNG-IUS: a non-inferiority randomized clinical trial. *Eur J Contracept Reprod Health Care*. 2018 29:1-7.

Marinaro F, Silva JM, Barros AA, Aroso IM, Gómez-Blanco JC, Jardin I, Lopez JJ, Pulido M, de Pedro MÁ, Reis RL, Sánchez-Margallo FM, Casado JG, López E. A fibrin coating method of polypropylene meshes enables the adhesion of menstrual blood-derived mesenchymal stromal cells: A new delivery strategy for stem cell-based therapies. *Int J Mol Sci*. 2021 Dec 13;22(24):13385. doi: 10.3390/ijms222413385. PMID: 34948187; PMCID: PMC8706515. Open Access: <https://www.ncbi.nlm.nih.gov/pmc/articles/PMC8706515/>

Markovic M, Manderson L, Warren N. Endurance and contest: women's narratives of endometriosis. *Health (London)*. 2008 Jul;12(3):349-67. doi: 10.1177/1363459308090053. PMID: 18579632.

Marla S, Mortlock S, Heinosalo T, Poutanen M, Montgomery GW, McKinnon BD. Gene expression profiles separate endometriosis lesion subtypes and indicate a sensitivity of endometrioma to estrogen suppressive treatments through elevated ESR2 expression. *BMC Med*. 2023 Nov 23;21(1):460. doi: 10.1186/s12916-023-03166-1. PMID: 37996888; PMCID: PMC10666321. Open Access: <https://bmcmecine.biomedcentral.com/articles/10.1186/s12916-023-03166-1>

Marquardt RM, Kim TH, Shin JH, Jeong JW. Progesterone and estrogen signaling in the endometrium: What goes wrong in endometriosis? *Int J Mol Sci.* 2019;20(15):3822. Published 2019 Aug 5. doi:10.3390/ijms20153822. PMID: 31387263
PMCID: <http://www.ncbi.nlm.nih.gov/pmc/articles/pmc6695957/>
DOI: <https://doi.org/10.3390/ijms20153822>

Marsh EE, Laufer MR. Endometriosis in premenarcheal girls who do not have an associated obstructive anomaly. *Fertil Steril* 2005, 83 (3):758-760

Martin DC. Infertility surgery using the carbon dioxide laser. *Clinical GynBriefs* 1983, 4(3):1-4.

Martin DC. CO2 laser laparoscopy for the treatment of endometriosis associated with infertility. *J Reprod Med* 1985, 30(5):409-12. PMID: 3159892.

Martin DC. CO2 laser laparoscopy for endometriosis associated with infertility. *J Reprod Med.* 1986a Dec;31(12):1089-94. PMID: 3098974.

Martin DC, Diamond MP. Operative laparoscopy - the role of the CO2 laser. Operative laparoscopy. In Martin DC, Absten CT, Levinson CJ, Guy J Photopulos GJ (editors). *Intra-abdominal Laser Surgery.* Memphis, Resurge Press, 1986b, pp 105-136.

Martin DC, Absten CT, Levinson CJ, Guy J Photopulos GJ (editors). *Intra-abdominal Laser Surgery.* Memphis, Resurge Press, 1986c [slide 041]

Martin DC, Diamond MP. Operative laparoscopy: comparison of lasers with other techniques. *Curr Probl Obstet Gynecol Fertil,* 1986d, IX(12):563-617

Martin DC, Vander Zwagg R. Excisional techniques for endometriosis with the CO2 laser laparoscope. *J Reprod Med* 1987, 32(10): 753-758

Martin DC. Laparoscopic and vaginal colpotomy for the excision of infiltrating cul-de-sac endometriosis. *J Reprod Med* 1988a, 33:806-808

Martin DC. *Laparoscopic Appearance of Endometriosis.* The Resurge Press, Richmond, 1988b, web revision 2018. <https://www.danmartinmd.com/files/lae1988.pdf>

Martin DC, Hubert GD, Vander Zwaag R, el-Zeky FA. Laparoscopic appearances of peritoneal endometriosis. *Fertil Steril.* 1989a Jan;51(1):63-7. doi: 10.1016/s0015-0282(16)60429-6. PMID: 2521327. Open Access: <https://www.sciencedirect.com/science/article/pii/S0015028216604296?via%3Dihub>

Martin DC, Hubert GD, Levy BS. Depth of infiltration of endometriosis. *J Gynecol Surg* 1989b, 5(1):55-60. doi: 10.1089/gyn.1989.5.55. <https://www.liebertpub.com/doi/10.1089/gyn.1989.5.55>

Martin DC, Ahmic R, El-Zeky FA, Vander Zwaag R, Pickens MT, Cherry K. Increased histologic confirmation of endometriosis. *J Gynecol Surg* 1990a;6(4):275-279. doi: 10.1089/gyn.1990.6.275. <https://www.liebertpub.com/doi/abs/10.1089/gyn.1990.6.275>

Martin DC, Berry JD. Histology of Chocolate Cysts. *J Gynecol Surg* 1990b, 6(1):43-46, doi: 10.1089/gyn.1990.6.43. <https://www.liebertpub.com/doi/10.1089/gyn.1990.6.43>

Martin DC. Recognition of Endometriosis. In Martin, DC. (ed) *Laparoscopic Appearance of Endometriosis Color Atlas.* 1990c, revised 2020. Resurge Press, Richmond, pp 1-7. <https://www.danmartinmd.com/files/coloratlas1990.pdf>

- Martin DC. (ed) Laparoscopic Appearance of Endometriosis Color Atlas. 1990d, Resurge Press, Richmond, revised 2020. <https://www.danmartinmd.com/files/coloratlas1990.pdf>
- Martin DC. Tissue effects of lasers. *Semin Reprod Endocrinol* 1991, 9:127–37.
- Martin DC, Rock JA. Laparoscopic excision of infiltrating pelvic endometriosis. In: Levinson A, ed. *OB-GYN illustrated: LTI Medica (Upjohn)*, 1992; pp. 1-16
- Martin DC. Laparoscopic treatment of advanced endometriosis. In: Sutton C, Diamond M, editors. *Endoscopic surgery for gynaecologists*. London: W.B. Saunders Company Ltd; 1993. p. 229-37.
- Martin DC. Surgical treatment of endometriosis. *Clin Consul Obstet Gynecol* 1995, 7:190-199
- Martin DC. Persistent or recurrent endometriosis. In: Lemay A, Maheus R, eds. *Understanding and Managing Endometriosis*. New York: The Parthenon Publishing Group, 1999, pages 233-239. ISBN-13: 978-1850700708, ISBN-10: 1850700702.
- Martin DC, Batt RE. Retrocervical, rectovaginal pouch, and rectovaginal septum endometriosis. *J Am Assoc Gynecol Laparosc* 2001, 8(1):12-17.
- Martin DC. Clinical and Research Aspects of Endometriosis. University of Tennessee Health Sciences Center, Department of Obstetrics and Gynecology. rounds November 15, 2005. This includes the “Pimple Model.” <http://www.danmartinmd.com/files/endouthsc2005.pdf> and <https://www.danmartinmd.com/files/pimplemodel.pdf>
- Martin DC. Applying STARD criteria to the laparoscopic identification of endometriosis. *Fertil Steril* 86(Suppl 2): s269, 2006
- Martin D. Clinical Controversies in Endometriosis. American Society of Reproductive Medicine, Baltimore, Maryland, October 21, 2015. Open access: <https://www.danmartinmd.com/files/asrm2015endometriosis.pdf>.
- Martin DC, Koninckx PR, Juvenile cystic adenomyomas: acquired adenomyosis variant or congenital Mullerian defects? *F&S Reports*. 2021, [Pre-proof online 5 May 2021] doi: <https://doi.org/10.1016/j.xfre.2021.04.004>.
Open Access: [https://www.fertstertreports.org/article/S2666-3341\(21\)00037-4/fulltext](https://www.fertstertreports.org/article/S2666-3341(21)00037-4/fulltext).
- Martin DC. Regarding "Intraoperative Detection of Rectosigmoid Endometriosis.". *J Minim Invasive Gynecol*. 2023 Apr 7:S1553-4650(23)00150-4. doi: 10.1016/j.jmig.2023.03.023. Epub ahead of print. PMID: 37031856.
- Masuda H, Schwab KE, Filby CE, Tsaltas J, Weston GC, Gargett CE. Endometrial stem/progenitor cells in menstrual blood and peritoneal fluid of women with and without endometriosis. *RBMO* 2021, 43(1):3-13. doi: 10.1016/j.rbmo.2021.04.008. [Online April 23, 2021]
- Matsuura K, Ohtake H, Katabuchi H, Okamura H. Coelomic metaplasia theory of endometriosis: evidence from in vivo studies and an in vitro experimental model. *Gynecol Obstet Invest*. 1999, 47 Suppl 1:18-20, discussion 20-2.
- Matsuzaki S, Pouly JL, Canis M. In vitro and in vivo effects of MK2206 and chloroquine combination therapy on endometriosis: autophagy may be required for regrowth of endometriosis. *Br J Pharmacol*. 2018 May;175(10):1637-1653.

Matsuzaki S, Pouly JL, Canis M. Dose-dependent pro- or anti-fibrotic responses of endometriotic stromal cells to interleukin-1 β and tumor necrosis factor α . *Sci Rep*. 2020 Jun 11;10(1):9467. doi: 10.1038/s41598-020-66298-x. PMID: 32528066; PMCID: PMC7289797. PMC open access: <https://www.ncbi.nlm.nih.gov/pmc/articles/PMC7289797/>

McGuinness B, Nezhat F, Ursillo L, Akerman M, Vintzileos W, White M. Fallopian tube endometriosis in women undergoing operative video laparoscopy and its clinical implications. *Fertil Steril*. 2020 Nov;114(5):1040-1048. doi: 10.1016/j.fertnstert.2020.05.026. Epub 2020 Aug 18. PMID: 32826047.

McNamara HC, Frawley HC, Donoghue JF, Readman E, Healey M, Ellett L, Reddington C, Hicks LJ, Harlow K, Rogers PAW, Claudia C. Peripheral, central, and cross sensitization in endometriosis-associated pain and comorbid pain syndromes. *Front Reprod Health*. 2021, 3:729642. doi: 10.3389/frph.2021.729642.

Open Access: <https://www.frontiersin.org/articles/10.3389/frph.2021.729642/full>

McQueen DB, et al. Redefining chronic endometritis: the importance of endometrial stromal changes. *Fertil Steril* 2021 [in press June 10, 2021] doi: 10.1016/j.fertnstert.2021.04.036

Open Access: <https://doi.org/10.1016/j.fertnstert.2021.04.036>

Meigs JV. Endometrial hematomas of the ovary. *Boston Med Surg J*. 1922, 187:1-13. doi: 10.1056/NEJM192207061870101. www.nejm.org/doi/full/10.1056/NEJM192207061870101

Meigs JV. Endometriosis; etiologic role of marriage age and parity: conservative treatment. *Obstet Gynecol*. 1953, 2:46-53

Metzemaekers J, Slotboom S, Sampat J, Vermolen P, Smeets MJGH, Elske van den Akker-van Marle M, Maas J, Bakker EC, Nijkamp M, Both S, Jansen FW. Crossroad decisions in deep endometriosis treatment options: a qualitative study among patients. *Fertil Steril*. 2021 Mar;115(3):702-714. doi: 10.1016/j.fertnstert.2020.06.041. Epub 2020 Oct 15. PMID: 33070963. Open access: [https://www.fertstert.org/article/S0015-0282\(20\)30612-9/fulltext](https://www.fertstert.org/article/S0015-0282(20)30612-9/fulltext)

Mier-Cabrera J, et al. Women with endometriosis improved their peripheral antioxidant markers after the application of a high antioxidant diet. *Reprod Biol Endocrinol*. 2009, 7:54. doi: 10.1186/1477-7827-7-54

Melicow, M. M. and Pachter, M. R.: Endometrial carcinoma of prostatic utricle (uterus maseulinus). *Cancer*, 20: 1715, 1967.

Meng X, Ichim TE, Zhong, et al. Endometrial regenerative cells: A novel stem cell population. *J Translational Med* 2007, 5:57 doi:10.1186/1479-5876-5-57

Open Access <http://www.translational-medicine.com/content/5/1/57>

Merrill JA. Endometrial induction of endometriosis across millipore filters. *Am J Obstet Gynecol*, 1966, 94(6,Mar):780-790. PMID: 5948379.

Mathias JR, Franklin R, Quast DC, Fraga N, Loftin CA, Yates L, Harrison V. Relation of endometriosis and neuromuscular disease of the gastrointestinal tract: new insights. *Fertil Steril*. 1998 Jul;70(1):81-8. doi: 10.1016/s0015-0282(98)00096-x. PMID: 9660426.

Open Access: [https://www.fertstert.org/article/S0015-0282\(98\)00096-X/fulltext](https://www.fertstert.org/article/S0015-0282(98)00096-X/fulltext)

Mettler L, Giesel H, Semm K. Treatment of female infertility due to tubal obstruction by operative laparoscopy. *Fertil Steril* 1979, 32:384-8.

Meyer 1903 quoted in van der Linden 1996. Theories on the pathogenesis of endometriosis. *Hum Reprod* 1996, 11(suppl 3):53-65.

Meyer R: Über den Stand der Frage der Adenomyositis und Adenomyome im allgemeinen und insbesondere über Adenomyositis seroepithelialis und Adenomyometritis sarcomatosa. *Zentralbl Gynäkol* 1919, 36:745.

Meyer R. Zur Frage der Urnieren-genese van Adenomyomen. *Zentralbl Gynäkol* 1923, 15:577-87.

Meyer R. Zur Frage der heterotopen Epithelwucherung, insbesondere des Peritonealepithels und in die Ovarien. *Virch Arch Path Anat Phys* 1924, 250(3):595–610.

<https://doi.org/10.1007/BF01891397>

<https://link.springer.com/article/10.1007/BF01891397>

Mikuš M, Goldštajn MŠ, Brlečić I, Dumančić S, Laganà AS, Chiantera V, Vujić G, Čorić M. CTLA4-Linked Autoimmunity in the Pathogenesis of Endometriosis and Related Infertility: A Systematic Review. *Int J Mol Sci*. 2022 Sep 18;23(18):10902. doi: 10.3390/ijms231810902. PMID: 36142815; PMCID: PMC9504308.

Open Access: <https://www.mdpi.com/1422-0067/23/18/10902>

Miyazaki K, Dyson MT, Coon V JS, Furukawa Y, Yilmaz BD, Maruyama T, Bulun SE. Generation of Progesterone-Responsive Endometrial Stromal Fibroblasts from Human Induced Pluripotent Stem Cells: Role of the WNT/CTNNB1 Pathway. *Stem Cell Reports*. 2018;11(5):1136-1155.

Moen MH. Is a long period without childbirth a risk factor for developing endometriosis? *Hum Reprod*. 1991 Nov;6(10):1404-7. doi: 10.1093/oxfordjournals.humrep.a137278. PMID: 1770135.

Moen MH, Magnus P. The familial risk of endometriosis. *Acta Obstet Gynecol Scand*. 1993 Oct;72(7):560-4. doi: 10.3109/00016349309058164. PMID: 8213105.

Moen MH, Stokstad T. A long-term follow-up study of women with asymptomatic endometriosis diagnosed incidentally at sterilization. *Fertil Steril*. 2002, 78(4):773-6. doi: 10.1016/s0015-0282(02)03336-8. PMID: 12372455.

Momoeda M, Hayakawa M, Shimazaki Y, Mizunuma H, Taketani Y. Does the presence of coexisting diseases modulate the effectiveness of a low-dose estrogen/progestin, ethinyl estradiol/drospirenone combination tablet in dysmenorrhea? Reanalysis of two randomized studies in Japanese women. *Int J Women's Health* 2014, 6 989–998

<https://www.ncbi.nlm.nih.gov/pmc/articles/PMC4259553/>

Montagna P, Capellino S, Villaggio B, Remorgida V, Ragni N, Cutolo M, Ferrero S. Peritoneal fluid macrophages in endometriosis: correlation between the expression of estrogen receptors and inflammation. *Fertil Steril*. 2008 Jul;90(1):156-64. doi: 10.1016/j.fertnstert.2006.11.200. Epub 2007 Jun 4. PMID: 17548071.

Open access: [https://www.fertstert.org/article/S0015-0282\(07\)00095-7/fulltext](https://www.fertstert.org/article/S0015-0282(07)00095-7/fulltext)

Moore JG, Binstock MA, Growdon WA. The clinical implications of retroperitoneal endometriosis. *Am J Obstet Gynecol*. 1988, 158(6 Pt 1):1291-1298. doi: 10.1016/0002-9378(88)90359-6. PMID: 3381857.

Morassutto C, Monasta L, Ricci G, Barbone F, Ronfani L. Incidence and estimated prevalence of endometriosis and adenomyosis in northeast Italy: a data linkage study. *PLoS One* 2016;11(4):e0154227 doi: 10.1371/journal.pone.0154227. eCollection 2016

Mori T, Ito F, Koshiba A, Kataoka H, Takaoka O, Okimura H, Khan KN, Kitawaki J. Local estrogen formation and its regulation in endometriosis. *Reprod Med Biol.*2019, 18(4):305-311. doi: 10.1002/rmb2.12285. eCollection 2019 Oct. PMID: 3160779
<https://www.ncbi.nlm.nih.gov/pmc/articles/PMC6780031/>

Mortlock S, Corona RI, Kho PG, et al. A multi-level investigation of the genetic relationship between endometriosis and ovarian cancer histotypes. *Cell Reports Medicine.* 2022, 3, 100542 doi: <https://doi.org/10.1016/j.xcrm.2022.100542>
Open access: [https://www.cell.com/cell-reports-medicine/fulltext/S2666-3791\(22\)00042-8](https://www.cell.com/cell-reports-medicine/fulltext/S2666-3791(22)00042-8)

Moses AS, Demessie AA, Taratula O, Korzun T, Slayden OD, Taratula O. Nanomedicines for endometriosis: Lessons learned from cancer research. *Small.* 2021 Feb;17(7):e2004975. doi: 10.1002/sml.202004975. Epub 2021 Jan 25. PMID: 33491876; PMCID: PMC7928207.
<https://www.ncbi.nlm.nih.gov/pmc/articles/PMC7928207/>

Moss EL, Hollingworth J, Reynolds TM. The role of CA125 in clinical practice. *J Clin Pathol.* 2005, 58(3):308-312. doi: 10.1136/jcp.2004.018077. PMID: 15735166; PMCID: PMC1770590.
Open Access: <https://jcp.bmj.com/content/58/3/308.long>

Munrós J, Martínez-Zamora MA, Tàssies D, Coloma JL, Torrente MA, Reverter JC, Carmona F, Balasch J. Total circulating microparticle levels are increased in patients with deep infiltrating endometriosis. *Hum Reprod.* 2017 Feb;32(2):325-331.

Munrós J, Martínez-Zamora MA, Tàssies D, Reverter JC, Rius M, Gracia M, Ros C, Carmona F. Total circulating microparticle levels after laparoscopic surgical treatment for endometrioma: A pilot, prospective, randomized study comparing stripping with CO2 laser vaporization. *J Minim Invasive Gynecol* 2019, 26, 450-455.

Muraoka A, et al. Fusobacterium infection facilitates the development of endometriosis through the phenotypic transition of endometrial fibroblasts. *2023 Sci. Transl. Med.*, 15 (700), eadd1531. DOI: 10.1126/scitranslmed.add1531

Murphy AA, Green WR, Bobbie D, dela Cruz ZC, Rock JA. Unsuspected endometriosis documented by scanning electron microscopy in visually normal peritoneum. *Fertil Steril.* 1986 Sep;46(3):522-4. doi: 10.1016/s0015-0282(16)49598-1. PMID: 3743803

Muzii L, Bianchi A, Bellati F, Cristi E, Pernice M, Zullo MA, Angioli R, Panici PB. Histologic analysis of endometriomas: what the surgeon needs to know. *Fertil Steril* 2007, 87:362-366.

Muzii L, Lecce F, Achilli C, Antonilli M, Musella A, Palaia I, Panici PB. Endometrioma-associated infertility: is surgery still the best way to go? *J Endometriosis* 2013; 5(4):127-133

Nair AS, Nair HB, Lucidi RS, Kirchner AJ, Schenken RS, Tekmal RR, Witz CA. Modeling the early endometriotic lesion: mesothelium-endometrial cell co-culture increases endometrial invasion and alters mesothelial and endometrial gene transcription. *Fertil Steril.* 2008 Oct;90(4 Suppl):1487-95. doi: 10.1016/j.fertnstert.2007.09.047. Epub 2007 Dec 27. PMID: 18163995.

Najdawi M, et al. Pain-Free Survival after Percutaneous Image-Guided Cryoablation of Extraperitoneal Endometriosis. *J Vasc Interv Radiol* 2023; xxx:1–7, [online Mar 29. 2023]. <https://doi.org/10.1016/j.jvir.2023.03.025>

Nap AW, Groothuis PG, Demir AY, Evers JL, Dunselman GA. Pathogenesis of endometriosis. *Best Pract Res Clin Obstet Gynaecol* 2004a, Apr;18(2):233-44. doi: 10.1016/j.bpobgyn.2004.01.005. PMID: 15157640.

Nap A. The pathogenesis of endometriosis: Sampson was right. Ph.D. thesis, Maastricht University, 10 December 2004b, Limbricht, ISBN 90-90-18574-7.

<https://cris.maastrichtuniversity.nl/ws/portalfiles/portal/1016197/guid-02129060-b722-4826-9f5f-edef6c82886b-ASSET1.0.pdf>

Nap AW. Theories on the Pathogenesis of Endometriosis. in Giudice LC, Evers JLH, Healy DL. (eds), *Endometriosis: Science and Practice*. 2012, John Wiley & Sons Publishers. Kindle Edition. <https://doi.org/10.1002/9781444398519.ch5>

Nirgianakis K, Gasparri ML, Radan AP, Villiger A, McKinnon B, Mueller MD. Obstetrical complications after laparoscopic excision of posterior deep infiltrating endometriosis: a case-control study. *Fertil Steril* 2018, 110(3):459–466. DOI: 10.1016/j.fertnstert.2018.04.036

Nerune SM, Hippargi SB, Mestri NB, Mehrotra NM. Persistent Müllerian duct syndrome with ovarian endometriosis-A rare case report. *J Clin Diagnostic Research* 2016, 10(2):14-15 (*Case report and discussion of endometriosis in men.*)

Netter A, d'Avout-Fourdinier P, Agostini A, Chanavaz-Lacheray I, Lampika M, Farella M, Hennetier C, Roman H. Progression of deep infiltrating rectosigmoid endometriotic nodules. *Hum Reprod*. 2019, 34(11):2144-2152. doi: 10.1093/humrep/dez188. PMID: 31687764.

Nezhat F, Allan CJ, Nezhat C, Martin DC. Nonvisualized endometriosis at laparoscopy. *Int J Fertil*. 1991, 36(6, Nov-Dec):340-343. PMID: 1684957.

Nezhat C, Nezhat F, Nezhat C. Endometriosis: ancient disease, ancient treatments. *Fertil Steril*. 2012, 98(6 Suppl):S1-62. doi: 10.1016/j.fertnstert.2012.08.001. Epub 2012 Oct 17. PMID: 23084567. [https://www.fertstert.org/article/S0015-0282\(12\)01955-3/fulltext](https://www.fertstert.org/article/S0015-0282(12)01955-3/fulltext)

Nezhat C, Agarwal S, Lee DA, Tavallae M. Can we accurately diagnose endometriosis without a diagnostic laparoscopy? *J Turk Ger Gynecol Assoc*. 2022 Jun 1;23(2):117-119. doi: 10.4274/jtggg.galenos.2022.2022-2-2. PMID: 35642436; PMCID: PMC9161000.

Nezhat Endometriosis Risk Advisor, 2023, <https://endometriosis.app/>. Accessed 7/26/2023.

Nishihara T, Matsumoto K, Hosoi Y, Morimoto Y. Evaluation of antioxidant status and oxidant stress markers in follicular fluid for human in vitro fertilization outcome. *Reprod Med Biol*. 2018, 17:481-486.

Nisolle M, Paidaveine B, Bourdon A, et al. Histologic study of peritoneal endometriosis in infertile women. *Fertil Steril* 1990;53:984-8

Nisolle M, Donnez J. Peritoneal endometriosis, ovarian endometriosis, and adenomyotic nodules of the rectovaginal septum are three different entities. *Fertil Steril* 1997, 68(4): 585-96.

Nisolle M, Casanas-Roux F, & Donnez J. Early-stage endometriosis: adhesion and growth of human menstrual endometrium in nude mice. *Fertil Steril* 2000, 74, 306-312.

Nisolle M, Casanas-Roux F, Marbaix E, Jadoul P, Donnez J. Transplantation of cultured explants of human endometrium into nude mice. *Hum Reprod*. 2000. 15(3), 572-577

- Noar M. AI-derived threshold score of intraabdominal myoelectrical activity predicts presence and stage of endometriosis with 100% accuracy. 2022, 29(11, supplement):S4-S5, doi: 10.1016/j.jmig.2022.09.026.
- Nora E, Meyer KA, Carbonera, P. Ectopic endometrium in abdominal scars following cesarean section, *Am J Obstet Gynecol* 1956, 71:876-884.
- Nothnick W, Alali Z. Recent advances in the understanding of endometriosis: the role of inflammatory mediators in disease pathogenesis and treatment. *F1000Res*. 2016 Feb 17;5:F1000 Faculty Rev-186. doi: 10.12688/f1000research.7504.1. PMID: 26949527; PMCID: PMC4760268. PMC: <https://www.ncbi.nlm.nih.gov/pmc/articles/PMC4760268/>
- Noble LS, Simpson ER, Johns A and Bulun SE. Aromatase expression in endometriosis. *J Clin Endocrinol Metab* 1996, 81,174–179. PMID: 8550748, DOI: 10.1210/jcem.81.1.8550748
Open Access: <https://academic.oup.com/jcem/article/81/1/174/2649406>
- Noble LS, Takayama K, Zeitoun KM, Putman JM, Johns DA, Hinshelwood MM, Agarwal VR, Zhao Y, Carr BR, Bulun SE. Prostaglandin E2 stimulates aromatase activity in endometriosis derived stromal cells. *J Clin Endocrinol Metab* 1997, 82:600–606. doi: 10.1210/jcem.82.2.3783. PMID: 9024261
Open Access: <https://academic.oup.com/jcem/article/82/2/600/2823486>
- Noël JC, Chapron C, Fayt I, Anaf V. Lymph node involvement and lymphovascular invasion in deep infiltrating rectosigmoid endometriosis. *Fertil Steril*. 2008 May;89(5):1069-1072. doi: 10.1016/j.fertnstert.2007.05.011. Epub 2007 Aug 6. PMID: 17681338.
- Novak E. Pelvic endometriosis *AJOG* 1931, 22(6):826-837
- Novella-Maestre E, Carda C, Noguera I, et al. Dopamine agonist administration causes a reduction in endometrial implants through modulation of angiogenesis in experimentally induced endometriosis. *Hum Reprod*. 2009;24(5):1025–1035. doi:10.1093/humrep/den499.
<https://doi.org/10.1093/humrep/den499>
- Noyes RW, Hertig AT, Rock J. Dating the endometrial biopsy. *Fertil Steril*. 1950, 1(1):3-25. doi: 10.1016/S0015-0282(16)30062-0
- Noyes RW, Hertig AT, Rock J. Reprint of: Dating the Endometrial Biopsy. *Fertil Steril*. 2019 Oct;112(4, Suppl 1):e93-e115. doi: 10.1016/j.fertnstert.2019.08.079. PMID: 31623748.
Open access: [https://www.fertstert.org/article/S0015-0282\(19\)32287-3/fulltext](https://www.fertstert.org/article/S0015-0282(19)32287-3/fulltext)
- Ohlsson Teague EMC, Van der Hoek KH, Van der Hoek MB, Perry N, Wagaarachchi P, Robertson SA, Print CG, Hull LM. MicroRNA-regulated pathways associated with endometriosis, *Mol Endocrinol*. 2009, 23:265–275. PMID: 19074548
DOI: <http://dx.doi.org/10.1210/me.2008-0387>
PMC: <https://www.ncbi.nlm.nih.gov/pmc/articles/PMC5419313/>
- Oliker AJ, Harris AE. Endometriosis of the bladder in a male patient. *J Urol*. 1971, 106(6):858-9. doi: 10.1016/s0022-5347(17)61418-6. PMID: 5116302.
- Olkowska-Truchanowicz J, Białoszewska A, Zwierzchowska A, Sztokfisz-Ignasiak A, Janiuk I, Dąbrowski F, Korczak-Kowalska G, Barcz E, Bocian K, Malejczyk J. Peritoneal Fluid from Patients with Ovarian Endometriosis Displays Immunosuppressive Potential and Stimulates Th2 Response. *Int J Mol Sci*. 2021 Jul 29;22(15):8134. doi: 10.3390/ijms22158134. PMID:

34360900; PMCID: PMC8347337.

Open Access: <https://www.mdpi.com/1422-0067/22/15/8134/htm>

Olsen CM, Green AC, Nagle CM, Jordan SJ, Whiteman DC, Bain CJ, Webb PM, Australian Cancer Study Group (Ovarian Cancer) and the Australian Ovarian Cancer Study Group.

Epithelial ovarian cancer: testing the 'androgens hypothesis'. *Endocr Relat Cancer* 2008;15:1061-1068. doi:10.1677/ERC-08-0075, PMID: 18772244

Open Access DOI: <https://doi.org/10.1677/erc-08-0075>

Ong YR, Cousins FL, Yang X, Mushafi AAAA, Breault DT, Gargett CE, Deane JA. Bone Marrow Stem Cells Do Not Contribute to Endometrial Cell Lineages in Chimeric Mouse Models. *Stem Cells*. 2018 Jan;36(1):91-102. doi: 10.1002/stem.2706. Epub 2017 Oct 4. PMID: 28913973.

Open access: <https://stemcellsjournals.onlinelibrary.wiley.com/doi/10.1002/stem.2706>

Oosterlynck DJ, Cornillie FJ, Waer M, Vandeputte M, Koninckx PR. Women with endometriosis show a defect in natural killer activity resulting in a decreased cytotoxicity to autologous endometrium. *Fertil Steril*. 1991;56(1):45-51

PMID: 2065804

DOI: [https://doi.org/10.1016/s0015-0282\(16\)54414-8](https://doi.org/10.1016/s0015-0282(16)54414-8)

Oosterlynck DJ, Meuleman C, Waer M, Koninckx PR. CO₂-laser excision of endometriosis does not improve the decreased natural killer activity. *Acta Obstet Gynecol Scand* 1994, 73:333-7.

Ottolina J, Schimberni M, Makieva S, Bartiromo L, Fazia T, Bernardinelli L, Viganò P, Candiani M, Gentilini D. Early life factors, in utero exposures and endometriosis risk: a meta-analysis.

RBMO 2002, [Published: May 14, 2020] DOI: <https://doi.org/10.1016/j.rbmo.2020.04.005>

Owoeye OBA, Rauvola RS, Brownson RC. Dissemination and implementation research in sports and exercise medicine and sports physical therapy: translating evidence to practice and policy.

BMJ Open Sport Exerc Med. 2020, 13;6(1):e000974. doi: 10.1136/bmjsem-2020-000974.

PMID: 33304607; PMCID: PMC7704287.

Panir K, Schjenken JE, Robertson SA, Hull ML. Non-coding RNAs in endometriosis: a narrative review. *Hum Reprod Update*. 2018, 24(4):497-51

Papageorgiou L, Andreou A, Zervou M, Vlachakis D, Goulielmos GN, Elias Eliopoulos E. A global population genomic analysis shows novel insights into the genetic characteristics of endometriosis. *World Acad Sci J*. 2023, 5: 12. DOI: 10.3892/wasj.2023.189.

Open Access: <https://www.spandidos-publications.com/10.3892/wasj.2023.189>

Parasar P, Sacha CR, Ng N, McGuirk ER, Chinthala S, Ozcan P, Lindsey L, Salas S, Laufer MR, Missmer SA, Anchan RM. Differentiating mouse embryonic stem cells express markers of human endometrium. *Reprod Biol Endocrin*, 2017, 15:52

Parra-Herran CE, Yuan L, Nucci MR, Quade BJ. Targeted development of specific biomarkers of endometrial stromal cell differentiation using bioinformatics: the IFITM1 model. *Mod Pathol*. 2014;27(4):569-579. PMID: 24072182. DOI: 10.1038/modpathol.2013.123

Open Access <https://www.nature.com/articles/modpathol2013123>

Pavone ME, Malpani SS, Dyson M, Kim JJ, Bulun SE. Fenretinide A Potential Treatment for Endometriosis. *Reprod Sci*. 2016 Sep; 23(9): 1139-1147.

Open Access <https://www.nature.com/articles/modpathol2013123>

Pavone ME, Malpani SS, Dyson M, Kim JJ, Bulun SE. Fenretinide A Potential Treatment for Endometriosis. *Reprod Sci*. 2016 Sep; 23(9): 1139-1147.

Pedrassani M, Guerriero S, Pascual MÁ, Ajossa S, Graupera B, Pagliuca M, Podgaec S, Camargos E, Vieira de Oliveira Y, Alcázar JL. Superficial endometriosis at ultrasound examination-A diagnostic criteria proposal. *Diagnostics (Basel)*. 2023 May 27;13(11):1876. doi: 10.3390/diagnostics13111876. PMID: 37296728; PMCID: PMC10252330.

Open Access: <https://www.mdpi.com/2075-4418/13/11/1876>

Peinado FM, Lendínez I, Sotelo R, et al. Association of Urinary Levels of Bisphenols A, F, and S with Endometriosis Risk: Preliminary Results of the EndEA Study. *Int J Environ Res Public Health* 2020, 17(4), 1194 <https://doi.org/10.3390/ijerph17041194>

Open Access <https://www.mdpi.com/1660-4601/17/4/1194/htm>

Perper MM, Nezhat F, Goldstein H, Nezhat CH, Nezhat C. Dysmenorrhea is related to the number of implants in endometriosis patients. *Fertil Steril* 1995, 63:500-3.

Persoons E, De Clercq K, Van den Eynde C, Pinto SJP, Luyten K, Van Bree R, Tomassetti C, Voets T, Vriens J. Mimicking Sampson's retrograde menstrual theory in rats: a new rat model for ongoing endometriosis-associated pain. *Int. J. Mol. Sci.* 2020, 21, 2326.

Open access: <https://doi.org/10.3390/ijms21072326>

Perrotta AR, Borrelli GM, Martins CO, Kallas EG, Sanabani SS, Griffith LG, Alm EJ, Abrao MS. The Vaginal Microbiome as a Tool to Predict rASRM Stage of Disease in Endometriosis: a Pilot Study. *Reprod Sci.* 2020 Apr;27(4):1064-1073. doi: 10.1007/s43032-019-00113-5. Epub 2020 Jan 6. PMID: 32046455; PMCID: PMC7539818.

Open Access: <https://www.ncbi.nlm.nih.gov/pmc/articles/PMC7539818/>

Petta CA, Ferriani RA, Abrao MS, Hassan D, Rosa E Silva JC, Podgaec S, Bahamondes L. Randomized clinical trial of a levonorgestrel-releasing intrauterine system and a depot GnRH analogue for the treatment of chronic pelvic pain in women with endometriosis. *Hum Reprod.* 2005, 20(7):1993-8.

Petraglia F, Vannuccini S, Santulli P, Marcellin L, Chapron C. An update for endometriosis management: a position statement, *Journal of Endometriosis and Uterine Disorders*, 2024, 100062, doi: 10.1016/j.jeud.2024.100062.

Open Access: <https://www.sciencedirect.com/science/article/pii/S2949838424000045>

Plavnik K, Tenaglia A, Hill C, Ahmed T, Shrikhande A. A novel, non-opioid treatment for chronic pelvic pain in women with previously treated endometriosis utilizing pelvic-floor musculature trigger-point injections and peripheral nerve hydrodissection. *PM&R.* 2020 Jul;12(7):655-662. doi: 10.1002/pmrj.12258. Epub 2019 Nov 15. PMID: 31587480.

Pluchino N, Mamillapalli R, Shaikh S, Habata S, Tal A, Gaye M, Taylor HS. CXCR4 or CXCR7 antagonists treat endometriosis by reducing bone marrow cell trafficking. *J Cell Mol Med.* 2020, 24(4):2464-2474. doi: 10.1111/jcmm.14933. Epub 2020 Jan 6. PMID: 31904910

DOI: <https://doi.org/10.1111/jcmm.14933>

Open Access: <https://onlinelibrary.wiley.com/doi/full/10.1111/jcmm.14933>

Portz DM, Elkins TE, White R, Warren J, Adadevoh S and Randolph J. Oxygen free radicals and pelvic adhesion formation: I. Blocking oxygen free radical toxicity to prevent adhesion formation in an endometriosis model. *Int J Fertil* 1991, 36,39-42.

Pospisilova E, Kiss I, Souckova H, et al. Circulating endometrial cells: A new source of information on endometriosis dynamics. *J Clin Med.* 2019;8(11):1938. PMID: 31717910, PMC:

PMC6912292/, doi: 10.3390/jcm8111938

Open Access: <https://www.mdpi.com/2077-0383/8/11/1938/htm>

Possover M, Chiantera V. Isolated infiltrative endometriosis of the sciatic nerve: a report of three patients. *Fertil Steril*. 2007 Feb;87(2):417.e17-9. doi: 10.1016/j.fertnstert.2006.05.084. PMID: 17276152. Open Access: [https://linkinghub.elsevier.com/retrieve/pii/S0015-0282\(06\)03858-1](https://linkinghub.elsevier.com/retrieve/pii/S0015-0282(06)03858-1)

Possover M. (ed) *Neuropelvelogy*. 2015. The International School for Neuropelvelogy. Hagendorn, Switzerland

Possover M. Laparoscopic morphological aspects and tentative explanation of the aetiopathogenesis of isolated endometriosis of the sciatic nerve: a review based on 267 patients. *Facts Views Vis Obgyn*. 2021 Dec;13(4):369-375. doi: 10.52054/FVVO.13.4.047. PMID: 35026098. Open Access: <https://fvvo.eu/archive/volume-13/number-4/original-articles/laparoscopic-morphological-aspects-and-tentative-explanation-of-aetiopathogenesis-of-isolated-endome/>

Potlog-Nahari C, Feldman AL, Stratton P, Koziol DE, Segars J, Merino MJ, Nieman LK. CD10 immunohistochemical staining enhances the histological detection of endometriosis. *Fertil Steril*. 2004 Jul;82(1):86-92. doi: 10.1016/j.fertnstert.2003.11.059. PMID: 15236994.

Power ML, Quagliari C, Schulkin J. Reproductive microbiomes: A new thread in the microbial network. *Reprod Sci*. 2017, 24(11):1482-1492. doi:10.1177/1933719117698577.

Prasad V, Cifu A, Ioannidis JP. Reversals of established medical practices: evidence to abandonment. *JAMA*. 2012 Jan 4;307(1):37-8. doi: 10.1001/jama.2011.1960. PMID: 22215160.

Prasad VK, Cifu AS. *Ending medical reversal: Improving outcomes, saving lives*. Johns Hopkins University Press, Baltimore. 2019

Praetorius TH, Leonova A, Lac V, Senz J, Tessier-Cloutier B, Nazeran TM, Köbel M, Grube M, Kraemer B, Yong PJ, Kommos S, Anglesio MS. Molecular analysis suggests oligoclonality and metastasis of endometriosis lesions across anatomically defined subtypes. *Fertil Steril*. 2022, 118(3):524-534 doi: 10.1016/j.fertnstert.2022.05.030. PMID: 35715244.

Open access: [https://www.fertstert.org/article/S0015-0282\(22\)00339-9/fulltext](https://www.fertstert.org/article/S0015-0282(22)00339-9/fulltext)

Pundir J, Omanwa K, Kovoov E, Pundir V, Lancaster G, Barton-Smith P. Laparoscopic excision versus ablation for endometriosis-associated pain: An updated systematic review and meta-analysis. *J Minim Invasive Gynecol*. 2017, 24(5):747-756, doi: 10.1016/j.jmig.2017.04.008, PMID: 28456617

Que J, Garman KS, Souza RF, Spechler SJ. Pathogenesis and cells of origin of Barrett's esophagus. *Gastroenterology*. 2019 Aug;157(2):349-364.e1. doi: 10.1053/j.gastro.2019.03.072. Epub 2019 May 10. PMID: 31082367; PMCID: PMC6650338.

Open access: <https://www.ncbi.nlm.nih.gov/pmc/articles/PMC6650338/>

Raas PW, De Wilde RL. The microcontact peritoneoscopy: a new diagnostic tool in endometriosis. *Am J Obstet Gynecol*. 1997 Jun;176(6):1398. doi: 10.1016/s0002-9378(97)70373-9. PMID: 9215209.

Radosa MP, Bernardi TS, Georgiev I, Diebolder H, Camara O, Runnebaum IB. Coagulation versus excision of primary superficial endometriosis: a 2-year follow-up. *Eur J Obstet Gynecol*

- Reprod Biol. 2010 Jun;150(2):195-8. doi: 10.1016/j.ejogrb.2010.02.022. Epub 2010 Mar 19. PMID: 20303642.
- Raposo G, Stoorvogel W. Extracellular vesicles: Exosomes, microvesicles, and friends. *J Cell Biol* 2013, 200(4): 373-83
- Redwine BD. Age-related evolution in color appearance of endometriosis. *Fertil Steril*, 1987, 48:1062-1063.
- Redwine DB. Is “microscopic” peritoneal endometriosis invisible? *Fertil Steril*. 1988a, 50:665-666.
- Redwine DB. Mülleriosis. The single best-fit model of the origin of endometriosis. *J Reprod Med* 1988b, 33:915-20.
- Redwine DB, Yocom LB. A serial section study of visually normal pelvic peritoneum in patients with endometriosis. *Fertil Steril*. 1990 Oct;54(4):648-51. doi: 10.1016/s0015-0282(16)53823-0. PMID: 2209885.
- Redwine DB. Conservative laparoscopic excision of endometriosis by sharp dissection: life table analysis of reoperation and persistent or recurrent disease. *Fertil Steril* 1991, 56:628-34.
- Redwine DB. Was Sampson wrong? *Fertil Steril* 2002, 78:686-692
- Redwine DB. Googling Endometriosis - The Lost Centuries. © David B. Redwine, M.D., 2012, revision 2016, <http://www.endopaedia.info/> or download https://drive.google.com/file/d/1UIBmdgddjD5eO-1TxW0mpky_vT97f2U2/view?usp=sharing
- Redwine DB, Hopton E. Bowel Invisible Microscopic Endometriosis: Leave It Alone. *J Minim Invasive Gynecol*. 2018 Mar-Apr;25(3):352-355. doi: 10.1016/j.jmig.2018.01.017. Epub 2018 Jan 31. PMID: 29373842.
- Redwine DB. Origin of Endometriosis: Cartoon Science vs Evidence-based Medicine. Endometriosis Foundation of America. Medical Conference 2019 <https://www.endofound.org/david-redwine-md-origin-of-endometriosis-cartoon-science-vs-evidence-based-medicine>
- Regidor PA, Regidor M, Schindler AE, Winterhager E. Aberrant expression pattern of gap junction connexins in endometriotic tissues. *Mol Hum Reprod*. 1997, 3(5):375–381. doi:10.1093/molehr/3.5.375, PMID: 9239721
Open Access DOI: <https://doi.org/10.1093/molehr/3.5.375>
- Rei C, Williams T, Feloney M. Endometriosis in a man as a rare source of abdominal pain: A case report and review of the literature. *Case Rep Obstet Gynecol*. 2018, 2018:2083121. doi: 10.1155/2018/2083121. PMID: 29670782; PMCID: PMC5833878.
Open Access <https://www.ncbi.nlm.nih.gov/pmc/articles/PMC5833878/>
- Reich H, McGlynn F, Salvat J. Laparoscopic treatment of cul-de-sac obliteration secondary to retrocervical deep fibrotic endometriosis. *J Reprod Med*. 1991 Jul;36(7):516-22. PMID: 1834840.
- Rekker K, Tasa T, Saare M, Samuel K, Kadastik Ü, Karro H, Götte M, Salumete A, Peters M. Differentially-expressed miRNAs in ectopic stromal cells contribute to endometriosis development: The plausible role of miR-139-5p and miR-375. *Int J Mol Sci*. 2018, 19, 3789-3800; doi:10.3390/ijms19123789; www.mdpi.com/1422-0067/19/12/3789/pdf

Ridley JH, Edwards IK. Experimental endometriosis in the human. *Am J Obstet Gynecol*. 1958 Oct;76(4):783-9; discussion 789-90. doi: 10.1016/0002-9378(58)90011-5. PMID: 13583019.

Ridley JH. The validity of Sampson's theory of endometriosis. *Am J Obstet Gynecol*. 1961 Oct;82:777-82. doi: 10.1016/s0002-9378(16)36141-5. PMID: 14492128.

Ridley JH. The histogenesis of endometriosis: a review of facts and fancies, *Obstet Gynecol Surv*. 1968, 23(1):1-35.

https://journals.lww.com/obgynsurvey/citation/1968/01000/the_histogenesis_of_endometriosis_a_review_of.1.aspx

Riley KA, Benton AS, Deimling TA, Kunselman AR, Harkins GJ. Surgical Excision Versus Ablation for Superficial Endometriosis-Associated Pain: A Randomized Controlled Trial. *J Minim Invasive Gynecol*. 2019 Jan;26(1):71-77. doi: 10.1016/j.jmig.2018.03.023. Epub 2018 Mar 30. PMID: 29609032.

Rier SE, Martin DC, Bowman RE, Dmowski WP, Becker JL. Endometriosis in rhesus monkeys (*Macaca mulatta*) following chronic exposure to 2,3,7,8-tetrachlorodibenzo-p-dioxin. *Fundam Appl Toxicol*. 1993 Nov;21(4):433-41. doi: 10.1006/faat.1993.1119. PMID: 8253297.

Rier SE, Martin DC, Bowman RE, Becker JL. Immunoresponsiveness in endometriosis: implications of estrogenic toxicants. *Environ Health Perspect*. 1995 Oct;103 Suppl 7(Suppl 7):151-6. doi: 10.1289/ehp.95103s7151. PMID: 8593863; PMCID: PMC1518890.

Open Access <https://www.ncbi.nlm.nih.gov/pmc/articles/PMC1518890/>

Rier SE, Coe CL, Lemieux AM, Martin DC, Morris R, Lucier GW, Clark GC. Increased tumor necrosis factor-alpha production by peripheral blood leukocytes from TCDD-exposed rhesus monkeys. *Toxicol Sci*. 2001 Apr;60(2):327-37. doi: 10.1093/toxsci/60.2.327. PMID: 11248145.

Ries E: *Ztschr. f. Geburtsh. u. Gynak.*, 1897, xxxvii, 518-532. Quoted in Batt RE, ed. *A History of Endometriosis*. London: Springer-Verlag London Ltd. 2011a.

<https://www.springer.com/us/book/9780857295842>

Rioux JE, Cloutier D. A new bipolar instrument for laparoscopic tubal sterilization. *Am J Obstet Gynecol*. 1974 Jul 15;119(6):737-9. doi: 10.1016/0002-9378(74)90084-2. PMID: 4276251.

Ripps BA, Martin DC. Focal pelvic tenderness, pelvic pain and dysmenorrhea in endometriosis. *J Reprod Med*. 1991 Jul;36(7):470-2. PMID: 1941783.

Ripps BA, Martin DC. Correlation of focal pelvic tenderness with implant dimension and stage of endometriosis. *J Reprod Med*. 1992 Jul;37(7):620-4. PMID: 1522570.

Risch HA. Hormonal etiology of epithelial ovarian cancer, with a hypothesis concerning the role of androgens and progesterone. *J Natl Cancer Inst*. 1998, 90(23):1774-1786.

doi:10.1093/jnci/90.23.1774, PMID: 9839517, DOI: <https://doi.org/10.1093/jnci/90.23.1774>

Rock JA, Parmley TH, King TM, Laufe LE, Su BS. Endometriosis and the development of tuboperitoneal fistulas after tubal ligation. *Fertil Steril*. 1981, 35(1):16-20.

Rokitansky C: *Über Uterusdrüsen-Neubildung in Uterus- und Ovarial-Sarcomen*. (On the neoplasm of uterus glands on uterine and ovarian sarcomas). *Zeitschr Ges Aerzte Wien* 1860, 16: 577-581. A translation is in Batt RE, ed. *Appendix II: English Translation of Carl Rokitansky's Ueber Uterusdrüsen-Neubildung in Uterus-und Ovarial Sarcomen*. in *A History of Endometriosis*. London: Springer-Verlag London Ltd. 2011c. Appendix II. PP 209-212

<https://www.springer.com/us/book/9780857295842>, Preview at Google Books at: https://www.google.com/books/edition/A_History_of_Endometriosis/JyoywyVfIhkC?hl=en&gbpv=1. Also see Chapter 2. *Intellectual Development of Carl Von Rokitansky*, in Batt RE, ed. *A History of Endometriosis*. London: Springer-Verlag London Ltd. 2011, pages 11-38. http://www.springer.com/cda/content/document/cda_downloadaddocument/9780857295842-c1.pdf?SGWID=0-0-45-1153739-p174109272

Roman H, Hennetier C, Darwish B, Badescu A, Csanyi M, Aziz M, Tuech JJ, Abo C. Bowel occult microscopic endometriosis in resection margins in deep colorectal endometriosis specimens has no impact on short-term postoperative outcomes. *Fertil Steril*. 2016, 105(2):423-9.e7. doi: 10.1016/j.fertnstert.2015.09.030. Epub 2015 Oct 29. PMID: 26474734. <https://clinicaltrials.gov/ct2/show/NCT02294825>

Roman H. Endometriosis surgery and preservation of fertility, what surgeons should know. *J Visc Surg*. 2018 Jun;155 Suppl 1:S31-S36. doi: 10.1016/j.jvisurg.2018.03.002. Epub 2018 Apr 27. PMID: 29709485.

Roman H, Bridoux V, Merlot B, Resch B, Chati R, Coget J, Forestier D, Tuech JJ. Risk of bowel fistula following surgical management of deep endometriosis of the rectosigmoid: a series of 1102 cases. *Hum Reprod*. 2020 Jul 1;35(7):1601-1611. doi: 10.1093/humrep/deaa131. PMID: 32619233; PMCID: PMC7368398.

Open Access: <https://academic.oup.com/humrep/article/35/7/1601/5867021?login=false>

Roman H, Merlot B, Forestier D, Noailles M, Magne E, Carteret T, Tuech JT, Martin DC. Nonvisualized palpable bowel endometriotic satellites. *Hum Reprod*. 2021, 36(3):656-665. doi: 10.1093/humrep/deaa340. PMID: 33432338; PMCID: PMC7891810.

Open access: <https://academic.oup.com/humrep/article/36/3/656/6085832>

Rossini R, Monsellato D, Bertolaccini L, Pesci A, Zamboni G, Ceccaroni M, Ruffo G. Lymph node involvement in deep infiltrating intestinal endometriosis: Does it really mean anything? *J Minim Invasive Gynecol*. 2016 Jul-Aug;23(5):787-92. doi: 10.1016/j.jmig.2016.03.021. Epub 2016 Apr 7. PMID: 27060532.

Rumph JT, Stephens VR, Archibong AE, Osteen KG, Bruner-Tran KL. Environmental endocrine disruptors and endometriosis. *Adv Anat Embryol Cell Biol*. 2020;232:57-78. doi: 10.1007/978-3-030-51856-1_4. PMID: 33278007; PMCID: PMC7978485.

PMC open access: <https://www.ncbi.nlm.nih.gov/pmc/articles/PMC7978485/>

Russell HB. Decidual reaction of endometrium ectopic in an abdominal lymph node. *Surg Gynecol & Obstet*. 1945, 81: 218-220

Russell WW. Aberrant portions of the Mullerian duct found in an ovary. *Johns Hopkins Hosp Bull*. 1899, 10(Nos 94-95-96)(Jan-Feb-Mar):8-10, plates I-III.

<https://babel.hathitrust.org/cgi/pt?id=uva.3470085735&view=1up&seq=20>

Ryu S, Bazer FW, Lim W, Song G. Chrysin leads to cell death in endometriosis by regulation of endoplasmic reticulum stress and cytosolic calcium level. *J Cell Physiol*. 2019 Mar;234(3):2480-2490.

Saare M, Rekker K, Laisk-Podar T, Rahmioglu N, Zondervan K, Salumets A, Götte M, Peters M. Challenges in endometriosis miRNA studies — From tissue heterogeneity to disease specific miRNAs. *Biochim Biophys Acta Mol Basis Dis*. 2017 1863(9):2282-2292.

doi: 10.1016/j.bbadis.2017.06.018. PMID: 28651916, Open Access:

<https://www.sciencedirect.com/science/article/pii/S0925443917302132?via%3Dihub>

Open Access: <https://doi.org/10.1016/j.bbadis.2017.06.018>

Sachedina A, Abu Bakar M, Dunford AM, Morris A, Nur Azurah AG, Grover SR. Dysmenorrhea in young people: Experiences from a tertiary center with a focus on conservative management. *J Obstet Gynaecol Res*. 2021 Jan;47(1):352-358. doi: 10.1111/jog.14532. PMID: 33084069.

Salmeri N, Sinagra E, Dolci C, Buzzaccarini G, Sozzi G, Sutera M, Candiani M, Ungaro F, Massimino L, Danese S, Mandarino FV. Microbiota in Irritable Bowel Syndrome and Endometriosis: Birds of a Feather Flock Together-A Review. *Microorganisms*. 2023 Aug 15;11(8):2089. doi: 10.3390/microorganisms11082089. PMID: 37630649; PMCID: PMC10458414. Open Access: <https://www.mdpi.com/2076-2607/11/8/2089>.

Samani EN, Mamillapalli R, Li F, Mutlu L, Hufnagel D, Krikun G, Taylor HS. Micrometastasis of endometriosis to distant organs in a murine model. *Oncotarget*. 2017 Apr 6;10(23):2282-2291. doi: 10.18632/oncotarget.16889. PMID: 31040919; PMCID: PMC6481344.

Open access PMC: <https://www.ncbi.nlm.nih.gov/pmc/articles/PMC6481344/>

Samimi M, Pourhanifeh MH, Mehdizadehkashi A, Eftekhar T, Asemi Z. The role of inflammation, oxidative stress, angiogenesis, and apoptosis in the pathophysiology of endometriosis: Basic science and new insights based on gene expression. *J Cell Physiol*. 2019, Nov;234(11):19384-19392. doi: <https://doi.org/10.1002/jcp.28666>. PMID: 31004368

Sampson JA. The escape of foreign material from the uterine cavity into the uterine veins. *Am J Obstet and diseases of Women and Children*. 1918, 78:161-75.

https://www.google.com/books/edition/_/G_EhAQAAAJ?hl=en

Sampson JA. Perforating hemorrhagic (chocolate) cysts of the ovary. Their importance and especially their relation to pelvic adenomas of the endometrial type (“adenomyoma” of the uterus, rectovaginal septum, sigmoid, etc.). *Arch Surg (now JAMA Surgery)*. 1921a, 3:245-323. doi: 10.1001/archsurg.1921.01110080003001,

Open Access: <https://jamanetwork.com/journals/jamasurgery/fullarticle/536143>

Sampson JA. Perforating hemorrhagic (chocolate) cysts of the ovary. Their importance and especially their relation to pelvic adenomas of the endometrial type (“adenomyoma” of the uterus, rectovaginal septum, sigmoid, etc.). *Trans Am Gynecol Soc* 1921b, 46:162-241.

Transactions of the American Gynecological Society 1921 is at

https://www.google.com/books/edition/Transactions_of_the_American_Gynecologic/QqFEAAAAYAAJ?hl=en&gbpv=1

Sampson JA. Intestinal adenomas of endometrial type. *Arch Surg (now JAMA Surgery)*. 1922, 5(1):217-80. DOI: 10.1001/archsurg.1922.01110140003001

JAMA Surgery: <https://jamanetwork.com/journals/jamasurgery/fullarticle/536342>

Sampson JA. Benign and malignant endometrial implants in the peritoneal cavity, and their relation to certain ovarian tumors. *Surg Gynecol Obstet*. 1924, 38:287-311.

<https://babel.hathitrust.org/cgi/pt?id=uva.x002486984&view=1up&seq=5>

- Sampson JA. Inguinal endometriosis (often reported as endometrial tissue in the groin, adenomyoma in the groin, and adenomyoma of the round ligament)*. *Am J Obstet Gynecol* 1925a, 10(Oct)(4):462-503. doi: 10.1016/S0002-9378(25)90591-1.
- Sampson JA. Heterotopic or misplaced endometrial tissue. *Am J Obstet Gynecol*. 1925b, 10(5):649-664. DOI: [https://doi.org/10.1016/S0002-9378\(25\)90629-1](https://doi.org/10.1016/S0002-9378(25)90629-1)
- Sampson JA. Endometriosis of the sac of a right inguinal hernia, associated with a pelvic peritoneal endometriosis and an endometrial cyst of the ovary. *Am J Obstet Gynecol* 1926, 12(4):459-483, DOI: <https://doi.org/10.1001/archsurg.1925.01120100007001>
- Sampson JA. Peritoneal endometriosis due to menstrual dissemination of endometrial tissue into the peritoneal cavity. *Am J Obstet Gynecol*. 1927a, 14:422-69. DOI: [https://doi.org/10.1016/S0002-9378\(15\)30003-X](https://doi.org/10.1016/S0002-9378(15)30003-X)
- Sampson JA. Metastatic or embolic endometriosis, due to the menstrual dissemination of endometrial tissue into the venous circulation. *Am J Path*. 1927b, 3(2):93-110.43. PMC: <https://www.ncbi.nlm.nih.gov/pmc/articles/PMC1931779/>
- Sampson JA. The development of the implantation theory for the origin of peritoneal endometriosis. *Am J Obstet Gynecol*. 1940, 40:549-557. DOI: [https://doi.org/10.1016/S0002-9378\(40\)91238-8](https://doi.org/10.1016/S0002-9378(40)91238-8)
- Santanam N, Kavtaradze N, Murphy A, Dominguez C, Parthasarathy S. Antioxidant supplementation reduces endometriosis-related pelvic pain in humans. *Transl Res*. 2013 Mar;161(3):189-95. doi: 10.1016/j.trsl.2012.05.001. Epub 2012 May 31. PMID: 22728166; PMCID: PMC3484190. PMC Access: <https://www.ncbi.nlm.nih.gov/pmc/articles/PMC3484190/>
- Sarria-Santamera A, Orazumbekova B, Terzic M, Issanov A, Chaowen C, Asúnsolo-Del-Barco A. Systematic Review and Meta-Analysis of Incidence and Prevalence of Endometriosis. *Healthcare (Basel)*. 2020 Dec 30;9(1):29. doi: 10.3390/healthcare9010029. PMID: 33396813; PMCID: PMC7824417. PMC: <https://www.ncbi.nlm.nih.gov/pmc/articles/PMC7824417>
- Sasamoto N, DePari M, Vitonis AF, Laufer MR, Missmer SA, Shafrir AL, et al. Evaluation of CA125 in relation to pain symptoms among adolescents and young adult women with and without surgically-confirmed endometriosis. *PLoS One*. 2020, 15(8): e0238043. Open Access: <https://doi.org/10.1371/journal.pone.0238043>
- Schifrin BS, Erez S, Moore JG. Teen-age endometriosis. *Am J Obstet Gynecol* 1973, 116:973-80.
- Schuurman AR, Sloot PMA, Wiersinga WJ, van der Poll T. Embracing complexity in sepsis. *Crit Care*. 2023 Mar 11;27(1):102. doi: 10.1186/s13054-023-04374-0. PMID: 36906606; PMCID: PMC10007743. Open Access: <https://ccforum.biomedcentral.com/articles/10.1186/s13054-023-04374-0>
- Ścieżyńska A, Komorowski M, Soszyńska M, Malejczyk J. NK cells as potential targets for immunotherapy in endometriosis. *J Clin Med*. 2019, 8(9):1468. Published 2019 Sep 14. doi:10.3390/jcm8091468. PMID: 31540116 PMCID: <http://www.ncbi.nlm.nih.gov/pmc/articles/pmc6780982/> DOI: <https://doi.org/10.3390/jcm8091468>

Scott RB, Te Linde RW, Wharton LR Jr. Further studies on experimental endometriosis. *Am J Obstet Gynecol.* 1953 Nov;66(5):1082-1103. doi: 10.1016/s0002-9378(16)38618-5, PMID: 13104506.

Scott RB, TeLinde RM. Clinical external endometriosis; probable viability of menstrually shed fragments of endometrium. *Obstet Gynecol.* 1954 Nov;4(5):502-10. PMID: 13214655.

Seitchik, J. Endometriosis and hormone therapy. *Am. J. Obstet Gynecol.* 81:183-184, 1961.

Semm K. Pelviscopy, Hysteroscopy and Fetoscopy. (Slides) ISBN 3-922500-00-5, © 1980 Professor De.Med. Kurt Semm. Slides 141 and 142.

Semm K. Pelviscopy. Presented partial excisional techniques at the 10th Annual AAGL meeting in Phoenix, Arizona, circa Nov 7, 1981, the date signed Dr. Martin's copy of Prof. Semm's slide set.

Semm K (ed). *Operationslehre für endoskopische Abdominal-Chirurgie.* F.K. Schattauer Verlag, Stuttgart. 1984, pages 145-146, 149, 258-259. (German)

Semm K. *Operative Manual for Endoscopic Abdominal Surgery: Operative Pelviscopy, Operative Laparoscopy.* Friedrich ER (translation of 1984 German edition). Chicago: Year Book Medical, 1987, pages 157-158, 161, 276-277.

Sen P, Fan Y, Schlezinger JJ, Ehrlich SD, Webster TF, Hyötyläinen T, Pedersen O, Orešič M. Exposure to environmental toxicants is associated with gut microbiome dysbiosis, insulin resistance and obesity. *Environ Int.* 2024 Mar 20;186:108569. doi:

10.1016/j.envint.2024.108569. Epub ahead of print. PMID: 38522229.

Open Access: <https://www.sciencedirect.com/science/article/pii/S0160412024001557>

Senekjian EK, Potkul RK, Frey K, Herbst AL. Infertility among daughters either exposed or not exposed to diethylstilbestrol. *Am J Obstet Gynecol.* 1988 Mar;158(3 Pt 1):493-8. doi: 10.1016/0002-9378(88)90012-9. PMID: 3348310.

Shafir AL, Farland LV, Shah DK, Harris HR, Kvaskoff M, Zondervan K, Missmer SA. Risk for and consequences of endometriosis: A critical epidemiologic review. *Best Pract Res Clin Obstet Gynaecol.* 2018 Jul 3. pii: S1521-6934(18)30109-3. doi: 10.1016/j.bpobgyn.2018.06.001 PMID: 30017581

Shapiro F, Vogelmann-Sine S, Sine LF. Eye movement desensitization and reprocessing: treating trauma and substance abuse. *J Psychoactive Drugs.* 1994 Oct-Dec;26(4):379-91.

Shakiba K, Bena JF, McGill KM, Minger J, Falcone T. Surgical treatment of endometriosis: a 7-year follow-up on the requirement for further surgery. *Obstet Gynecol.* 2008 Jun;111(6):1285-92. doi: 10.1097/AOG.0b013e3181758ec6. Erratum in: *Obstet Gynecol.* 2008 Sep;112(3):710. PMID: 18515510.

Shroen D. *Disputatio inauguralis medica de ulceribus uteri.* Jena:Krebs, 1690:6 –17. Quoted in Knapp 1999, Batt 2000, Brosens 2000, and Batt 2011a.

Signorile PG, Baldi F, Bussani R, D'Armiento MR, De Falco M, Baldi A. 2009. Ectopic endometrium in human fetuses is a common event and sustains the theory of mullerianosis in the pathogenesis of endometriosis, a disease that predisposes to cancer. *J Exp Clin Cancer Res* 28:49.

Signorile PG, Baldi F, Bussani R, D'Armiento M, De Falco M, Boccellino M, Quagliuolo L, Baldi A. New evidence of the presence of endometriosis in the human fetus. *Reprod BioMed Online*. 2010, 21, 142- 147

Signorile PG et al. Embryologic origin of endometriosis: Analysis of 101 human female fetuses. *J Cell Physiol*. 2012, 227: 1653-1656

Signorile PG, Petraglia F, Baldi A. Anti-mullerian hormone is expressed by endometriosis tissues and induces cell cycle arrest and apoptosis in endometriosis cells *J Experimental & Clinical Cancer Research* 2014, 33:46.

Simon AK, Hollander GA, McMichael A. Evolution of the immune system in humans from infancy to old age. *Proc Biol Sci*. 2015 Dec 22;282(1821):20143085. doi: 10.1098/rspb.2014.3085. PMID: 26702035; PMCID: PMC4707740.

Open access: <https://www.ncbi.nlm.nih.gov/pmc/articles/PMC4707740/>

Simpson CN, Lomiguen CM, Chin J. Combating diagnostic delay of endometriosis in adolescents via educational awareness: A systematic review. *Cureus*. 2021 May 20;13(5):e15143. doi: 10.7759/cureus.15143. PMID: 34164243; PMCID: PMC8214575.

Open access: <https://www.ncbi.nlm.nih.gov/pmc/articles/PMC8214575/>

Simpson JL, Elias S, Malinak LR, Buttram VCJ. Heritable aspects of endometriosis. I. Genetic studies. *Am J Obstet Gynecol* 1980, 137:327.

Simpson JL, Bischoff FZ, Kamat A, Buster JE, Carson SA. Genetics of endometriosis. *Obstet Gynecol Clin North Am*. 2003 Mar;30(1):21-40, vii. doi: 10.1016/s0889-8545(02)00051-7. PMID: 12699256.

Sinaii N, Cleary SD, Ballweg ML, Nieman LK, Stratton P. High rates of autoimmune and endocrine disorders, fibromyalgia, chronic fatigue syndrome and atopic diseases among women with endometriosis: a survey analysis. *Hum Reprod*. 2002 Oct;17(10):2715-24. doi: 10.1093/humrep/17.10.2715. PMID: 12351553.

Open Access: <https://academic.oup.com/humrep/article/17/10/2715/607769?login=false>

Smarr MM, Kannan K, Buck Louis GM. Endocrine disrupting chemicals and endometriosis. *Fertil. Steril*. 2016, 106:959–966. Open Access <https://doi.org/10.1016/j.fertnstert.2016.06.034> [https://www.fertstert.org/article/S0015-0282\(16\)61389-4/fulltext](https://www.fertstert.org/article/S0015-0282(16)61389-4/fulltext)

Sokalska A, Hawkins AB, Yamaguchi T, Duleba AJ. Lipophilic statins inhibit growth and reduce invasiveness of human endometrial stromal cells. *J Assist Reprod Genet*. 2018 Dec 15.

Song C, Tang B, Campbell PA, Cuschieri A. Thermal spread and heat absorbance differences between open and laparoscopic surgeries during energized dissections by electro-surgical instruments. *Surg Endosc*. 2009 Nov;23(11):2480-7. doi: 10.1007/s00464-009-0421-7. Epub 2009 Mar 19. PMID: 19296174.

Song XC, Yu X, Luo M, Yu Q, Zhu L. Clinical characteristics and postoperative symptoms of adolescent endometriosis among 85 cases. *J Pediatr Adolesc Gynecol*. 2020 Jun 30:S1083-3188(20)30258-8. doi: 10.1016/j.jpag.2020.06.021. Epub ahead of print. PMID: 32619717.

Squifflet J, Feger C, Donnez J. Diagnosis and imaging of adenomyotic disease of the retroperitoneal space. 2002, *Gynecol Obstet Invest* 54(suppl):43-51

Starzinski-Powitz A, Handrow-Metzmacher H, Kotzian S. The putative role of cell adhesion molecules in endometriosis: can we learn from tumour metastasis? *Mol Med Today*. 1999 Jul;5(7):304-9. doi: 10.1016/s1357-4310(99)01497-5. PMID: 10377522.

Starzinski-Powitz A, Zeitvogel A, Schreiner A, Baumann R. In search of pathogenic mechanisms in endometriosis: the challenge for molecular cell biology. *Curr Mol Med* 2001, 1(6): 655-64

Starzinski-Powitz A, Zeitvogel A, Schreiner A, Baumann R. [Endometriosis—a stem cell disease?]. *Zentralbl Gynäkol* 2003, 125(7- 8): 235-8. (German)

Steck WD, Helwig EB. Cutaneous endometriosis. *JAMA*. 1965, 191(Jan):167-70. PMID: 14233249

Steiner N, Shrem G, Tannus S, Dahan SY, Balayla J, Volodarsky-Perel A, Tan SL, Dahan MH. Effect of GnRH agonist and letrozole treatment in women with recurrent implantation failure. *Fertil Steril*. 2019 Jul;112(1):98-104. doi: 10.1016/j.fertnstert.2019.03.021. Epub 2019 May 24. PMID: 31133384. Open Access: [https://www.fertstert.org/article/S0015-0282\(19\)30294-8/fulltext](https://www.fertstert.org/article/S0015-0282(19)30294-8/fulltext)

Stevens TG. Adenomyoma of the vaginal wall. *Proc R Soc Med*. 1910, 3(Obstet Gynaecol Sect):57-8. PMID: 19974573
PMCID: <https://www.ncbi.nlm.nih.gov/pmc/articles/PMC1961111/>

Stevens TG. Adenomyoma of the recto-vaginal septum. *Proc R Soc Med*. 1916, 9(Obstet Gynaecol Sect):1-17. PMID: 19979329
PMCID: <https://www.ncbi.nlm.nih.gov/pmc/articles/PMC2017308/>

Stephens VR, Rumph JT, Ameli S, Bruner-Tran KL, Osteen KG. The potential relationship between environmental endocrine disruptor exposure and the development of endometriosis and adenomyosis. *Front Physiol*. 2022 Jan 28;12:807685. doi: 10.3389/fphys.2021.807685. Erratum in: *Front Physiol*. 2023 Aug 14;14:1260961. PMID: 35153815; PMCID: PMC8832054. Open Access: <https://www.frontiersin.org/articles/10.3389/fphys.2021.807685/full>

Strauß T, Greve B, Gabriel M, et al. Impact of Musashi-1 and Musashi-2 double knockdown on notch signaling and the pathogenesis of endometriosis. *Int J Mol Sci*. 2022, 23(5), 2851; doi: 10.3390/ijms23052851 Open Access: <https://www.mdpi.com/1422-0067/23/5/2851>

Stripling MC, Martin DC, Chatman DL, Zwaag RV, Poston WM. Subtle appearance of pelvic endometriosis. *Fertil Steril*. 1988a Mar;49(3):427-31. doi: 10.1016/s0015-0282(16)59767-2. PMID: 3342893. Open Access: <https://www.sciencedirect.com/science/article/pii/S0015028216597672?via%3Dihub>

Stripling MC, Martin DC, Poston WM. Does endometriosis have a typical appearance? *J Reprod Med*. 1988b, 33:879-884.

Stuparich M, Lee T. Peritoneal pockets: tips for complete excision. 2019: <https://youtu.be/oypmCx469Gw>. Accessed August 8, 2020

Stylianou E. Epigenetics of chronic inflammatory diseases. *J Inflamm Res*. 2018 Dec 20;12:1-14. doi: 10.2147/JIR.S129027. PMID: 30588059; PMCID: PMC6304253. Open access: <https://www.ncbi.nlm.nih.gov/pmc/articles/PMC6304253/>

Suda K, Nakaoka H, Yoshihara K, Ishiguro T, Tamura R, Mori Y, Yamawaki K, Adachi S, Takahashi T, Kase H, Tanaka K, Yamamoto T, Motoyama T, Inoue I, Enomoto T. Clonal

expansion and diversification of cancer-associated mutations in endometriosis and normal endometrium. *Cell Reports* 2018. 24, 1777–1789

Suda K, Cruz Diaz LA, Yoshihara K, Nakaoka H, Yachida N, Motoyama T, Inoue I, Enomoto T. Clonal lineage from normal endometrium to ovarian clear cell carcinoma through ovarian endometriosis. *Cancer Sci.* 2020 Aug;111(8):3000-3009. doi: 10.1111/cas.14507. Epub 2020 Jun 26. PMID: 32473611; PMCID: PMC7419022.

Sugamata M, Ihara T, Uchiide I. A New Therapy for Human Endometriosis: The Therapeutic Value of Leukotriene Receptor Antagonist for Endometriosis. *Open Journal of Obstetrics and Gynecology*, 2015, 5, 313-318. <http://dx.doi.org/10.4236/ojog.2015.56045>

Suginami H. A reappraisal of the coelomic metaplasia theory by reviewing endometriosis occurring in unusual sites and instances. *Am J Obstet Gynecol.* 1991 Jul;165(1):214-8?

Sui X, Li Y, Sun Y, Li C, Li X, Zhang G. Expression and significance of autophagy genes LC3, Beclin1 and MMP-2 in endometriosis. *Exp Ther Med.* 2018 Sep;16(3):1958-1962.

Sumathi VP, McCluggage WG. CD10 is useful in demonstrating endometrial stroma at ectopic sites and in confirming a diagnosis of endometriosis. *J Clin Pathol.* 2002 May;55(5):391-2. doi: 10.1136/jcp.55.5.391. PMID: 11986349; PMCID: PMC1769659.

PMB open access: <https://www.ncbi.nlm.nih.gov/pmc/articles/PMC1769659/>

Sun H, Fukuda S, Hirata T, Arakawa T, Ma S, Neriishi K, ... Osuga Y. IFITM1 is a Novel, Highly Sensitive Marker for Endometriotic Stromal Cells in Ovarian and Extragenital Endometriosis. *Reproductive Sciences.* 2019, Feb 21. PMID: 30791812. <https://doi.org/10.1177/1933719119831782>.

Surrey ES. Gonadotropin-releasing hormone agonist and add-back therapy: what do the data show? *Curr Opin Obstet Gynecol.* 2010 Aug; 22(4):283-8

Surrey ES, Katz-Jaffe M, Kondapalli LV, Gustofson RL, Schoolcraft WB. GnRH agonist administration prior to embryo transfer in freeze-all cycles of patients with endometriosis or aberrant endometrial integrin expression. *Reprod Biomed Online.* 2017 Aug;35(2):145-151. doi: 10.1016/j.rbmo.2017.05.004. Epub 2017 May 17. PMID: 28601378.

Surrey ES, Soliman AM, Johnson SJ, Davis M, Castelli-Haley J, Snabes MC. Risk of developing comorbidities among women with endometriosis: A Retrospective Matched Cohort Study. *J Womens Health (Larchmt).* 2018 Sep;27(9):1114-1123. doi: 10.1089/jwh.2017.6432. Epub 2018 Aug 2. PMID: 30070938.

Surrey ES, Soliman AM, Johns B, Vora JB, Taylor HS, Agarwal SK. Real-world characterization of women with diagnosed endometriosis initiating therapy with elagolix using a US claims database. *Clinicoecon Outcomes Res.* 2020 Aug 26;12:473-479. doi: 10.2147/CEOR.S264905. PMID: 32922052; PMCID: PMC7456657.

Sutton JG, Ewen SP, Whitelaw N, Haines P. Prospective, randomized, double-blind, controlled trial of laser laparoscopy in the treatment of pelvic pain associated with minimal, mild, and moderate endometriosis. *Fertil Steril*, 1994, 62:696-700

Szukiewicz D. Epigenetic regulation and T-cell responses in endometriosis - something other than autoimmunity. *Front Immunol.* 2022 Jul 22;13:943839. doi: 10.3389/fimmu.2022.943839.

PMID: 35935991; PMCID: PMC9355085.

Open Access: <https://www.frontiersin.org/articles/10.3389/fimmu.2022.943839/full>

Szukiewicz D. Insight into the potential mechanisms of endocrine disruption by dietary phytoestrogens in the context of the etiopathogenesis of endometriosis. *Int J Mol Sci.* 2023 Jul 30;24(15):12195. doi: 10.3390/ijms241512195. PMID: 37569571; PMCID: PMC10418522.

Open Access: <https://www.mdpi.com/1422-0067/24/15/12195>

Tadir Y, Kaplan I, Zuckerman Z, Edelstein T, Ovadia J. New instrumentation and technique for laparoscopic carbon dioxide laser operations: a preliminary report. *Obstet Gynecol.* 1984, 63(4):582-5.

Takeuchi H, Kuwatsuru R, Kitade M, Sakurai A, Kikuchi I, Shimanuki H, Kinoshita K. A novel technique using magnetic resonance imaging jelly for evaluation of rectovaginal endometriosis. *Fertil Steril.* 2005 Feb;83(2):442-7. doi: 10.1016/j.fertnstert.2004.08.021. PMID: 15705388.

Open Access: [https://www.fertstert.org/article/S0015-0282\(04\)02877-8/fulltext](https://www.fertstert.org/article/S0015-0282(04)02877-8/fulltext)

Taylor HS. Endometriosis: a complex systemic disease with multiple manifestations. *Fertil Steril.* 2019 A112(2):235-236. doi: 10.1016/j.fertnstert.2019.06.006. Epub 2019 Jul 4. PMID: 31280952. Open Access: <https://doi.org/10.1016/j.fertnstert.2019.06.006>

Taussig FJ. Ectopic decidua formation. *Surg Gynecol & Obstet.* 1906, 2: 292-303.

Te Linde RW, Scott RB. Experimental endometriosis. *Am J Obstet Gynecol.* 1950 Nov;60(5):1147-73. doi: 10.1016/0002-9378(50)90517-5. PMID: 14789879.

Te Linde RW, Scott RB: Diagnosis and treatment of endometriosis. *General Practice* 1952, 5:61-65.

The American Fertility Society. Classification of endometriosis. *Fertil Steril* 1979, 32:633-4

The American Fertility Society. Revised American Fertility Society classification of endometriosis: 1985. *Fertil Steril* 11. 1985, 43:351-2

Thomas EJ, Cooke ID: The impact of gestrinone upon the course of asymptomatic endometriosis. *Br Med J* 1987, 294:272-274.

<https://www.ncbi.nlm.nih.gov/pmc/articles/PMC1245293/>

Thomas EJ. Endometriosis [should not be treated just because it's there]. *BMJ.* 1993 Jan 16;306(6871):158-9. doi: 10.1136/bmj.306.6871.158. PMID: 8443475; PMCID: PMC1676597.

Open Access: <https://www.ncbi.nlm.nih.gov/pmc/articles/PMC1676597/>

Thomas EJ. The relevance of asymptomatic endometriosis. *Hum Reprod.* 1996 Nov;11 Suppl 3:103-9. doi: 10.1093/humrep/11.suppl_3.103. PMID: 9147105.

Open Access: https://academic.oup.com/humrep/article/11/suppl_3/103/676768?login=false

Thompson BH, Wheelless CR Jr. Gastrointestinal complications of laparoscopy sterilization. *Obstet Gynecol.* 1973 May;41(5):669-76. PMID: 4266773.

Tiboni G, Ponzano A. Fetal safety profile of aromatase inhibitors: Animal data. *Reproductive Toxicology* 2016, 66:84-92

Tica VI, Tomescu CL, Tomescu A, Micu L, Zaher M, Bafani S, Beghim M, Serbănescu L, Tica I. Asymptomatic abdominal wall endometrioma 15 years after cesarean section. *Rom J Morphol Embryol.* 2006;47(3):301-4. PMID: 17308693.

- Tosh D, Slack JM. How cells change their phenotype. *Nat Rev Mol Cell Biol.* 2002 Mar;3(3):187-94. doi: 10.1038/nrm761. PMID: 11994739.
- Tosh D, Horb ME. How cells change their phenotype. In: Lanza R, Atala A, eds. *Essentials of Stem Cell Biology, Third Edition.* Amsterdam: Elsevier Inc. (Academic Press), 2014:107-17. Chapter 9. DOI: <https://doi.org/10.1016/B978-0-12-409503-8.00009-3>
- Tran DK, GEE (1994) Classification de l'endométriose externe par la méthode FOATI. *Contracept Fertil Sex.* 1994, 22(suppl 12):817–823
- Tran DK, Belaisch J, and the members of the French Endometriosis Study Group (GEE). Is it the time to change the ASRM classification for endometriosis lesions? Proposal for a functional FOATIaRVS classification. *Gynecol Surg.* (2012) 9:369–73. doi: 10.1007/s10397-012- 0739-3
Open Access: <https://link.springer.com/article/10.1007/s10397-012-0739-3>
- Treloar SA, O'Connor DT, O'Connor VM, Martin NG. Genetic influences on endometriosis in an Australian twin sample. *Fertil Steril.* 1999 Apr;71(4):701-10. doi: 10.1016/s0015-0282(98)00540-8. PMID: 10202882.
- Tuominen A, Saavalainen L, Tiitinen A, Heikinheimo O, Härkki P. Pregnancy and delivery outcomes in women with rectovaginal endometriosis treated either conservatively or operatively. *Fertil Steril.* 2020 Oct 8:S0015-0282(20)30713-5. doi: 10.1016/j.fertnstert.2020.07.051. Epub ahead of print. PMID: 33039131.
- Turco MY, Gardner L, Hughes J, Cindrova-Davies T, Gomez MJ, Farrell L, Hollinshead M, Marsh SGE, Brosens JJ, Critchley HO, Simons BD, Hemberger M, Koo BK, Moffett A, Burton GJ. Long-term, hormone-responsive organoid cultures of human endometrium in a chemically defined medium. *Nat Cell Biol.* 2017 May;19(5):568-577. doi: 10.1038/ncb3516. Epub 2017 Apr 10. PMID: 28394884; PMCID: PMC5410172.
- Umezawa M, Sakata C, Tanaka N, Tabata M, Takeda K, Ihara T, Sugamata M. Pathological study for the effects of in utero and postnatal exposure to diesel exhaust on a rat endometriosis model. *J Toxicol Sci.* 2011, 36(4):493-498. <https://www.researchgate.net/publication/51535576>
- Upson K, Sathyanarayana S, Scholes D, Holt VL. Early-life factors and endometriosis risk. *Fertil Steril.* 2015 Oct;104(4):964-971.e5. doi: 10.1016/j.fertnstert.2015.06.040. Epub 2015 Jul 26. PMID: 26211883; PMCID: PMC5328429.
Open access: <https://www.ncbi.nlm.nih.gov/pmc/articles/PMC5328429/>
- Utkarsh K, Srivastava N, Papayannakos C, Nayyar A, Khan A, Haque S. Breaking the silence: The role of extracellular vesicles in unraveling the diagnosis and treatment of endometriosis. *Extracell Vesicles Circ Nucleic Acids* 2023;4:599-614. doi: 10.20517/evcna.2023.43
Open Access: <https://dx.doi.org/10.20517/evcna.2023.43>
- Vallvé-Juanico J, López-Gil C, Ballesteros A, Santamaria X. Endometrial Stromal Cells Circulate in the Bloodstream of Women with Endometriosis: A Pilot Study. *Int J Mol Sci.* 2019, 20(15):3740. PMID: 31370190
PMCID: <http://www.ncbi.nlm.nih.gov/pmc/articles/pmc6695832/>
DOI: <https://doi.org/10.3390/ijms20153740>
- van der Linden PJ. Theories on the pathogenesis of endometriosis. *Hum Reprod.* 1996 Nov;11 Suppl 3:53-65. doi: 10.1093/humrep/11.suppl_3.53. PMID: 9147102.

van der Weiden RMF, Haberland D, Sedivy R, van den Tweel JG. An 18th century description of endometriosis: The autopsy of the Countess von Reitzenstein. *Wien Med Wochenschr.* 2020 Mar;170(3-4):71-75. English. doi: 10.1007/s10354-019-0693-z. Epub 2019 Apr 8. PMID: 30963306.

van Haaps A, Wijbers J, Schreurs A, Mijatovic V. A better quality of life could be achieved by applying the endometriosis diet: a cross-sectional study in Dutch endometriosis patients. *Reprod Biomed Online.* 2023 Mar;46(3):623-630. doi: 10.1016/j.rbmo.2022.12.010. Epub 2022 Dec 17. PMID: 36702643. Open Access: <https://www.rbmojournal.com/action/showPdf?pii=S1472-6483%2822%2900860-4>

Van Niekerk L, Johnstone L, Matthewson M. Predictors of self-compassion in endometriosis: the role of psychological health and endometriosis symptom burden. *Hum Reprod.* 2022 Jan 28;37(2):264-273. doi: 10.1093/humrep/deab257. PMID: 35102421.

Vandivier H. Primary Care. *Wabash Magazine.* Winter, 1998
<https://www.wabash.edu/magazine/1998/winter/features/ling.htm> accessed 02/19/2019

Vercellini P, Bocciolone L, Vendola N, Colombo A, Rognoni MT, Fedele L. Peritoneal endometriosis. Morphologic appearance in women with chronic pelvic pain. *J Reprod Med* 1991, 36:533-6.

Vargas E, García-Moreno E, Aghajanova L, Salumets A, Horcajadas JA, Esteban FJ, Altmäe S. The mid-secretory endometrial transcriptomic landscape in endometriosis: a meta-analysis. *Hum Reprod Open.* 2022 Apr 4;2022(2):hoac016. doi: 10.1093/hropen/hoac016. PMID: 35464885; PMCID: PMC9022214.
PMC Open Access: <https://www.ncbi.nlm.nih.gov/pmc/articles/PMC9022214/>

Vercellini P, Somigliana E, Viganò P, Abbiati A, Barbara G, Fedele L. 'Blood on the tracks' from corpora lutea to endometriomas. *BJOG.* 2009 Feb;116(3):366-71. doi: 10.1111/j.1471-0528.2008.02055.x. PMID: 19187368.
Open access: <https://obgyn.onlinelibrary.wiley.com/doi/full/10.1111/j.1471-0528.2008.02055.x>

Vernon MW, Beard JS, Graves K, Wilson EA. Classification of endometriotic implants by morphologic appearance and capacity to synthesize prostaglandin F. *Fertil Steril.* 1986, 46(5):801-6.

Viganò P, Gaffuri B, Santorsola R, Somigliana E, Busacca M, Di Blasio AM, Vignali M. Cell adhesion molecules. In: Lemay A, Maheus R, eds. *Understanding and Managing Endometriosis.* New York: The Parthenon Publishing Group, 1999, pages 83-90. ISBN-13: 978-1850700708, ISBN-10: 1850700702

Viganò P, Candiani M, Monno A, Giacomini E, Vercellini P, Somigliana E. Time to redefine endometriosis including its pro-fibrotic nature. *Hum Reprod* 2018, 33(3):347-352.

Viganò P, Vercellini P, Somigliana E, Chapron C, Petraglia F, Griffith LG, Mueller MD, Martin DC, Nap A, Romano A, Reis F, Carmona F, Burns KA, Taylor HS, Santulli P, Canis M, Koninckx RP, Guo S-W. "I'm looking through you": What consumers and manufacturers need to know about non-invasive diagnostic tests for endometriosis. *Journal of Endometriosis and Uterine Disorders.* 2023, 2:100031. [online 9 June 2023] doi: 10.1016/j.jeud.2023.100031.
<https://doi.org/10.1016/j.jeud.2023.100031>.
<https://authors.elsevier.com/sd/article/S2949838423000191>

Vinatier D, Dufour P, Oosterlynck D. Immunological aspects of endometriosis. *Hum Reprod Update*. 1996 Sep-Oct;2(5):371-84. doi: 10.1093/humupd/2.5.371. PMID: 15717437.

Vitale SG, Capriglione S, Peterlunger I, La Rosa VL, Vitagliano A, Noventa M et al. The Role of Oxidative Stress and Membrane Transport Systems during Endometriosis: A Fresh Look at a Busy Corner. *Oxid Med Cell Longev* 2018, 2018:7924021.

Vogel D. Introduction. NIH, Endometriosis 2000, Endometriosis Research and Strategies, April 9 and 10, 2000, Bethesda. Maryland

Von Recklinghausen F. Die Adenomyome und Cystadenome der Uterus- und Tubenwandung ihre Abkunft von Resten des Wolff'schen Körpers. Im Anhang: Von W. A. Freund, Klinische Notizen zu den voluminösen Adenomyomen des Uterus. [Berlin: Verlag von August Hirschwald, 1896] (reported by Cullen 1896 and Casler 1919)

Waiyaput W, Wattanakamolchai K, Tingthanatikul Y, et al. Effect of combined contraceptive pill on immune cell of ovarian endometriotic tissue. *J Ovarian Res* 14, 66 (2021). Open access: <https://doi.org/10.1186/s13048-021-00819-8>

Waldeyer W. Eierstock und Ei. Leipzig 1870. Quoted in Russell 1899 and van der Linden 1996.

Wang Y, Nicholes K, Shih IM. The origin and pathogenesis of endometriosis. *Annu Rev Pathol*. 2020, 15:71-95. doi: 10.1146/annurev-pathmechdis-012419-032654. Epub 2019 Sep 3. PMID: 31479615.

Wang Y, Li Q, Zhao R, Wang JY, Wang Y, Lin W, Yuan Z, Zhang J, Fadare O, Wang Y and Zheng W. Fallopian tubal histogenesis of ovarian endometriosis—A study of folate receptor-alpha expression. *Front Med*. 2023. 10:1138690. doi: 10.3389/fmed.2023.1138690
Open Access: <https://www.frontiersin.org/articles/10.3389/fmed.2023.1138690/full>

Warren LA, Shih A, Renteira SM, Seckin T, Blau B, Simpfendorfer K, Lee A, Metz CN, Gregersen PK. Analysis of menstrual effluent: diagnostic potential for endometriosis. *Mol Med*. 2018, 19;24(1):1. doi: 10.1186/s10020-018-0009-6. PMID: 30134794. PMCID: PMC6016873

Watkins RE: Uterine replacement, retrograde menstruation and endometriosis. *West J Surg* 46:480, 1938. Discussed in Blumenkrantz et al. *Obstet Gynecol*. 1981, 57(5):667-670.

Watkins RE: The presence of endometrial cells in peritoneal fluid. *J Pac Coast Soc Obstet* 7:120, 1937. Reported in Blumenkrantz et al. *Obstet Gynecol*. 1981, 57(5):667-670.

Wei Y, Liang Y, Lin H, Dai Y, Yao S. Autonomic nervous system and inflammation interaction in endometriosis-associated pain. *J Neuroinflammation*, 2020, 17:80. doi: 10.1186/s12974-020-01752-1. PMID: 32145751. PMCID: PMC7060607/
Open Access: <https://www.ncbi.nlm.nih.gov/pmc/articles/PMC7060607/>

Wei Y, Tan H, Yang R, Yang F, Liu D, Huang B, OuYang L, Lei S, Wang Z, Jiang S, Cai H, Xie X, Yao S, Liang Y. Gut dysbiosis-derived β -glucuronidase promotes the development of endometriosis. *Fertil Steril*. 2023 Sep;120(3 Pt 2):682-694. doi: 10.1016/j.fertnstert.2023.03.032. Epub 2023 May 12. PMID: 37178109. Open Access: [https://www.fertstert.org/article/S0015-0282\(23\)00241-8/fulltext](https://www.fertstert.org/article/S0015-0282(23)00241-8/fulltext)

Wharton LR: Conservative surgical treatment of pelvic endometriosis. *South Med J*. 1929, 22(3):267-271.

- Weller CV. Menstruating umbilical tumors. *Am J Pathol.* 1927 Sep; 3(5): 553-555
<https://www.ncbi.nlm.nih.gov/pmc/articles/PMC1931819/pdf/amjpathol00378-0170.pdf>
- Wheeler JM, Malinak LR. Recurrent endometriosis: incidence, management, and prognosis. *Am J Obstet Gynecol.* 1983 Jun 1;146(3):247-53. doi: 10.1016/0002-9378(83)90744-5. PMID: 6859132. [https://www.ajog.org/article/0002-9378\(83\)90744-5/fulltext](https://www.ajog.org/article/0002-9378(83)90744-5/fulltext)
- Wheless, CR. Thermal gastrointestinal injuries. In Phillips JM (ed). *Laparoscopy.* Baltimore, Williams & Wilkins, 1977 231-235
- Whiteley, Kathleen. Hippocrates' Diseases of Women Book 1 – Greek Text with English Translation and Footnotes. PhD thesis 2003 <http://uir.unisa.ac.za/handle/10500/1620>
- Wild RA, Zhang RJ, Medders D. Whole endometrial fragments form characteristics of in vivo endometriosis in a mesothelial cell co-culture system: an in vitro model for the study of the histogenesis of endometriosis. *J Soc Gynecol Investig* 1994. 1(1):65-8.
- Williams TJ, Pratt JH. Endometriosis in 1,000 consecutive celiotomies: incidence and management. *Am J Obstet Gynecol.* 1977 Oct 1;129(3):245-50. doi: 10.1016/0002-9378(77)90773-6. PMID: 900194.
- Wilson C. DES--adverse health outcomes after in utero exposure. *Nat Rev Endocrinol.* 2011 Nov 1;7(12):692. doi: 10.1038/nrendo.2011.187. PMID: 22045107.
- Wirtz D, Konstantopoulos K, Searson PC. The physics of cancer: the role of physical interactions and mechanical forces in metastasis. *Nat Rev Cancer.* 2011 Jun 24;11(7):512-22. doi: 10.1038/nrc3080. PMID: 21701513; PMCID: PMC3262453
- Witz CA, Montoya-Rodriguez IA, Schenken RS. Whole peritoneal explants—a novel model of the early endometriosis lesion. *Fertil Steril.* 1999, 71:56–60.
- Witz CA et al. Attachment of endometrial cells to peritoneum--facilitated? *Fertil Steril.* 2001. 76(2):421-422.
- Witz C, Dechaud H, Montoya-Rodriguez I, Thomas M, Nair A, Centonze V, Schenken R. An in vitro model to study the pathogenesis of the early endometriosis lesion. *Ann N Y Acad Sci* 2002, 955:296-307; discussion 340-2, 396-406.
- Witz CA, Cho S, Centonze VE, Montoya-Rodriguez IA, Schenken RS. Time series analysis of transmesothelial invasion by endometrial stromal and epithelial cells using three-dimensional confocal microscopy. *Fertil Steril* 2003. 79:770–8.
- Wright J, Lotfallah H, Jones K, Lovell D. A randomized trial of excision versus ablation for mild endometriosis. *Fertil Steril.* 2005 Jun;83(6):1830-6. doi: 10.1016/j.fertnstert.2004.11.066. PMID: 15950657.
- Wu Y, Kajdacsy-Balla A, Strawn E, Basir Z, Halverson G, Jailwala P, Wang Y, Wang X, Ghosh S, Guo SW. Transcriptional characterizations of differences between eutopic and ectopic endometrium. *Endocrinology.* 2006 Jan;147(1):232-46. doi: 10.1210/en.2005-0426. Epub 2005 Sep 29. PMID: 16195411.
- Wu RC, Wang P, Lin SF, Zhang M, Song Q, Chu T, Wang BG, Kurman RJ, Vang R, Kinzler K, Tomasetti C, Jiao Y, Shih IM, Wang TL. Genomic landscape and evolutionary trajectories of ovarian cancer precursor lesions. *J Pathol.* 2019 May;248(1):41-50. doi: 10.1002/path.5219.

Epub 2019 Feb 15. PMID: 30560554; PMCID: PMC6618168.

<https://www.ncbi.nlm.nih.gov/pmc/articles/PMC6618168/>

Wüest A, Limacher JM, Dingeldein I, Siegenthaler F, Vaineau C, Wilhelm I, Mueller MD, Imboden S. Pain Levels of Women Diagnosed with Endometriosis: Is There a Difference in Younger Women? *J Pediatr Adolesc Gynecol*. 2023 Apr;36(2):140-147. doi: 10.1016/j.jpag.2022.10.011. Epub 2022 Nov 4. PMID: 36343859.

Yachida N, Yoshihara K, Yamaguchi M, Suda K, Tamura R, Enomoto T. How does endometriosis lead to ovarian cancer? The molecular mechanism of endometriosis-associated ovarian cancer development. *Cancers (Basel)*. 2021 Mar 22;13(6):1439. doi: 10.3390/cancers13061439. PMID: 33809880; PMCID: PMC8004227.

Yamamoto K, Mitsuhashi Y, Takaike T, Takase K, Hoshiai H, Noda K. Tubal endometriosis diagnosed within one month after menarche: a case report. *Tohoku J Exp Med*. 1997 Mar;181(3):385-7. doi: 10.1620/tjem.181.385. PMID: 9163854.
Open access: https://www.jstage.jst.go.jp/article/tjem/181/3/181_3_385/article

Yan D, Liu X, Guo SW. Neuropeptides substance P and calcitonin gene related peptide accelerate the development and fibrogenesis of endometriosis. *Sci Rep*. 2019, 9(1):2698
PMID: 30804432, PMCID: PMC6389969. DOI: 10.1038/s41598-019-39170-w
<https://www.ncbi.nlm.nih.gov/pmc/articles/PMC6389969/>

Yang HL, Mei J, Chang KK, Zhou WJ, Huang LQ, Li MQ. Autophagy in endometriosis. *Am J Transl Res*. 2017 Nov 15;9(11):4707-4725. PMID: 29218074; PMCID: PMC5714760.

Yang K, Cheng S, Cai Y, Qiao J, Xu Y, Li X, Xiong S, Lu Y, Mei A, Li X, Zhou L. Clinical characteristics and surgical treatment of ureteral endometriosis: our experience with 40 cases. *BMC Womens Health*. 2021 May 17;21(1):206. doi: 10.1186/s12905-021-01349-7. PMID: 34001081; PMCID: PMC8130255. Open Access:
<https://bmcwomenshealth.biomedcentral.com/articles/10.1186/s12905-021-01349-7>

Yasukawa M, Uchiyama T, Ohbayashi C, Kawaguchi T, Kawai N, Sawabata N, Taniguchi S. A case of a Müllerian cyst arising in the posterior mediastinum. *Oxf Med Case Reports*. 2018 Oct 9;2018(11):omy080. doi: 10.1093/omcr/omy080. PMID: 30319783; PMCID: PMC6176126.
Open Access: <https://academic.oup.com/omcr/article/2018/11/omy080/5123803?login=false>

Yeung P Jr, Sinervo K, Winer W, Albee RB Jr. Complete laparoscopic excision of endometriosis in teenagers: is postoperative hormonal suppression necessary? *Fertil Steril*. 2011 May;95(6):1909-12, 1912.e1. doi: 10.1016/j.fertnstert.2011.02.037. PMID: 21420081

Yeung PP Jr, Logan I, Gavard JA. Deep Retraction Pockets, Endometriosis, and Quality of Life. *Front Public Health*. 2016, 4:85. doi: 10.3389/fpubh.2016.00085. PMID: 27242981; PMCID: PMC4861171.

Yilmaz BD, Bulun SE. Endometriosis and nuclear receptors. *Hum Reprod Update*. 2019, Jul 1;25(4):473-485. doi: 10.1093/humupd/dmz005. PMID: 30809650; PMCID: PMC6601390.
PMC(open access): <https://www.ncbi.nlm.nih.gov/pmc/articles/PMC6601390/>

Yin M, Zhou HJ, Lin C, Long L, Yang X, Zhang H, Taylor H, Min W. CD34+KLF4+ Stromal stem cells contribute to endometrial regeneration and repair. *Cell Rep*. 2019 May 28;27(9):2709-2724.e3. doi: 10.1016/j.celrep.2019.04.088. PMID: 31141693; PMCID: PMC6548470.
PMC (open access): <https://www.ncbi.nlm.nih.gov/pmc/articles/PMC6548470/>

- Yin M, Zhang J, Zeng X, Zhang H, Gao Y. Target identification and drug discovery by data-driven hypothesis and experimental validation in ovarian endometriosis. *Fertil Steril*. 2021 Aug;116(2):478-492. doi: 10.1016/j.fertnstert.2021.01.027. Epub 2021 Mar 11. PMID: 33714537.
- Yoo JY, Kim TH, Fazleabas AT, Palomino WA, Ahn SH, Tayade C, Schammel DP, Young SL, Jeong JW, Lessey BA. KRAS Activation and over-expression of SIRT1/BCL6 Contributes to the Pathogenesis of Endometriosis and Progesterone Resistance. *Sci Rep*. 2017, 28;7(1):6765. doi: 10.1038/s41598-017-04577-w. PMID: 28754906; PMCID: PMC5533722.
- Yoon IB, Wheelless CR Jr, King TM. A preliminary report on a new laparoscopic sterilization approach: the silicone rubber band technique. *Am J Obstet Gynecol*. 1974 Sep;120(1):132-6. doi: 10.1016/0002-9378(74)90191-4. PMID: 4276927.
- Young VJ, Brown JK, Saunders PT, Horne AW. The role of the peritoneum in the pathogenesis of endometriosis. *Hum Reprod Update*. 2013 Sep-Oct;19(5):558-69. doi: 10.1093/humupd/dmt024. Epub 2013 May 29. PMID: 23720497.
Open access: <https://academic.oup.com/humupd/article/19/5/558/614030>
- Yoshino O, Ono Y, Honda M, Hattori K, Sato E, Hiraoka T, Ito M, Kobayashi M, Arai K, Katayama H, Tsuchida H, Yamada-Nomoto K, Iwahata S, Fukushi Y, Wada S, Iwase H, Koga K, Osuga Y, Iwaoka M, Unno N. Relaxin-2 May Suppress Endometriosis by Reducing Fibrosis, Scar Formation, and Inflammation. *Biomedicines*. 2020 Oct 31;8(11):E467. doi: 10.3390/biomedicines8110467. PMID: 33142814.
Open Access: <https://www.mdpi.com/2227-9059/8/11/467>
- Yovich JL, Rowlands PK, Lingham S, Sillender M, Srinivasan S. Pathogenesis of endometriosis: Look no further than John Sampson. *Reprod Biomed Online*. 2019 Oct 24. pii: S1472-6483(19)30783-7. doi: 10.1016/j.rbmo.2019.10.007.
PMID: <https://www.ncbi.nlm.nih.gov/pubmed/31836436>
Open Access: <https://linkinghub.elsevier.com/retrieve/pii/S1472648319307837>
- Zámečník M, Hošťáková D. Endometriosis in a mesothelial cyst of tunica vaginalis of the testis. Report of a case. *Cesk Patol*. 2013 49(3):134-6. PMID: 23964911.
Open Access <https://www.prolekare.cz/linkout/41227>
- Zanetta G, Webb MJ, Segura JW. Ureteral endometriosis diagnosed at ureteroscopy. *Obstet Gynecol*. 1998 May;91(5 Pt 2):857-9. doi: 10.1016/s0029-7844(97)00435-3. PMID: 9572191.
- Zegers-Hochschild F, Adamson GD, Dyer S, Racowsky C, de Mouzon J, Sokol R, Rienzi L, Sunde A, Schmidt L, Cooke ID, Simpson JL, van der Poel S. The international glossary on infertility and fertility care, 2017. *Hum Reprod*. 2017 Sep 1;32(9):1786-1801. doi: 10.1093/humrep/dex234. PMID: 29117321; PMCID: PMC5850297.
- Zhang J, Wang H, Meng Q, Chen J, Wang J, Huang S. Expression of MTA1 in endometriosis and its relationship to the recurrence. *Medicine (Baltimore)*. 2018, 97(35):e12115. doi: 10.1097/MD.00000000000012115. PMID: 30170442.
- Zhang S, Zhuang L, Liu Q, Yu X, Min Q, Chen M and Chen Q: Rosiglitazone affects the progression of surgically-induced endometriosis in a rat model. *Mol Med Rep*. 2021, 23: 35. doi: 10.3892/mmr.2020.11673
Open access: <https://www.spandidos-publications.com/10.3892/mmr.2020.11673>

Zhang P, Wang G. Progesterone Resistance in Endometriosis: Current Evidence and Putative Mechanisms. *Int J Mol Sci.* 2023 Apr 10;24(8):6992. doi: 10.3390/ijms24086992. PMID: 37108154; PMCID: PMC10138736. Open Access: <https://www.mdpi.com/1422-0067/24/8/6992>

Zhou WJ, Yang HL, Shao J, Mei, J Chang, K-J, Zhu, RLi M-Q. Anti inflammatory cytokines in endometriosis. *Cell. Mol. Life Sci.* 2019a, 76:2111–2132. doi: 10.1007/s00018-019-03056-x

Zhou Y, Chen C, Hu C, Wang Y, Zhang X, Wu R. Predictive value of the serum anti-Müllerian level for spontaneous pregnancy in women after endometriosis surgery. *J Int Med Res.* 2019b 47(11):5643-5649. doi: 10.1177/0300060519861171. Epub 2019 Sep 26. PMID: 31554444; PMCID: PMC6862891.

Open Access: <https://journals.sagepub.com/doi/10.1177/0300060519861171>

Zhu S, Zhang J, Xue N, Zhu X, Li F, Dai Q, Qing X, Chen D, Liu X, Wei Z, Cao Y. Highly specific neutrophil-mediated delivery of albumin nanoparticles to ectopic lesion for endometriosis therapy. *J Nanobiotechnology.* 2023 Mar 8;21(1):81. doi: 10.1186/s12951-023-01831-4. PMID: 36890521; PMCID: PMC9996962. Open Access:

<https://jnanobiotechnology.biomedcentral.com/articles/10.1186/s12951-023-01831-4>

Zinsser KR, Wheeler JE. Endosalpingiosis in the omentum: a study of autopsy and surgical material. *Am J Surg Pathol.* 1982 Mar;6(2):109-17. doi: 10.1097/00000478-198203000-00003. PMID: 7102891.

Zippl AL, Reiser E, Seeber B. Endometriosis and mental health disorders: identification and treatment as part of a multimodal approach. *Fertil Steril.* 2024 Mar;121(3):370-378. doi: 10.1016/j.fertnstert.2023.12.033. Epub 2023 Dec 29. PMID: 38160985. Open Access:

[https://www.fertstert.org/article/S0015-0282\(23\)02104-0/fulltext](https://www.fertstert.org/article/S0015-0282(23)02104-0/fulltext)

Zondervan KT, Becker CM, Koga K, Missmer SA, Taylor RN, Viganò P. Endometriosis. *Nat Rev Dis Primers.* 2018, 19;4(1):9. doi: 10.1038/s41572-018-0008-5. PMID: 30026507

Zondervan KT, Becker CM, Missmer SA. Endometriosis. *N Engl J Med.* 2020 Mar 26;382(13):1244-1256. doi: 10.1056/NEJMra1810764. PMID: 32212520.

[\[Return to Contents\]](#)

Resources

Laparoscopic Appearance of Endometriosis, First Edition (PDF)
1988 Images: <https://www.danmartinmd.com/files/lae1988.pdf>

Laparoscopic Appearance of Endometriosis, Second Edition (PDF)
URL for updates: <https://www.danmartinmd.com/files/coloratlas1990.pdf>

Endometriosis Concepts (Webpage)
<http://www.endometriosisconcepts.com>

Endometriosis Concepts and Theories (PDF)
<https://danmartinmd.com/files/endotheory.pdf>

DanMartinMD.com links (Webpage)
<https://danmartinmd.com/links.html>

DanMartinMD.com downloads (Webpage)
<http://www.danmartinmd.com/sitemap.html>

Dan Martin, MD at Google Scholar
<https://scholar.google.com/citations?user=sj2jcPIAAAAJ&hl=en&oi=sra>

Edmonds K. Heal Endo: An Anti-Inflammatory Approach to Healing from Endometriosis. 2022. Katie Edmonds, Kauai. <https://www.amazon.com/Heal-Endo-Anti-Inflammatory-Approach-Endometriosis/dp/1792389485/>

Edmonds K. The 4-Week Endometriosis Diet Plan: 75 Healing Recipes to Relieve Symptoms and Regain Control of Your Life. 2019. Katie Edmonds, Kauai. <https://www.amazon.com/4-Week-Endometriosis-Diet-Plan-Symptoms/dp/1641527366/>

Endometriosis Foundation of America
<https://www.endofound.org/>

Society for Women's Health Research (SWHR) Toolkit
https://swhr.org/swhr_resource/endometriosis-toolkit-a-patient-empowerment-guide/

Endometriosis.org
<http://endometriosis.org/>

Endometriosis Association
<https://endometriosisassn.org/>

GynSurgery.com
<https://www.gynsurgery.org/>

